

Tocopherol Alleviates Exacerbation of Colitis Due to Cadmium Exposure in Wistar Rats: A Biochemical and Histological Study

Ige Serah Funke ^a, Ayinla Sussan Chinyere ^{a*},
Adeniyi Iyanuoluwa Temilade ^a, Yusuff Matthew Akorede ^a,
Adewumi Adeola Anuoluwa ^a, Olaleke Faith Temitope ^a,
Hezekiah Oluwaseun Samuel ^a, Ayodele Deborah Feranmi ^a
and Akangbe Barakat Omobolanle ^a

^a Department of Physiology, Faculty of Basic Medical Sciences, Ladoke Akintola University of Technology, Ogbomoso, Oyo State, Nigeria.

Authors' contributions

This work was carried out in collaboration among all authors. Authors ISF and ASC designed the study and wrote the first draft of the manuscript, Author AIT, YMA and HOS performed the statistical analysis while Authors ASC, AAA and OFT managed the literature searches. All authors read and approved the final manuscript.

Article Information

Open Peer Review History:

This journal follows the Advanced Open Peer Review policy. Identity of the Reviewers, Editor(s) and additional Reviewers, peer review comments, different versions of the manuscript, comments of the editors, etc are available here: <https://www.sdiarticle5.com/review-history/122078>

Original Research Article

Received: 21/06/2024

Accepted: 23/08/2024

Published: 03/09/2024

ABSTRACT

Aims: This study investigated the effects of Tocopherol (vitamin E) on cadmium-exposed colitic rats.

Study Design: A randomized controlled experimental study involving 40 male Wistar rats (180 ± 20g). Group 1: Normal control; Group 2: Vitamin E-treated; Group 3: Colitis-induced; Group 4:

*Corresponding author: Email: sussanchi@gmail.com;

Cite as: Funke, Ige Serah, Ayinla Sussan Chinyere, Adeniyi Iyanuoluwa Temilade, Yusuff Matthew Akorede, Adewumi Adeola Anuoluwa, Olaleke Faith Temitope, Hezekiah Oluwaseun Samuel, Ayodele Deborah Feranmi, and Akangbe Barakat Omobolanle. 2024. "Tocopherol Alleviates Exacerbation of Colitis Due to Cadmium Exposure in Wistar Rats: A Biochemical and Histological Study". *Asian Journal of Research and Reports in Gastroenterology* 7 (1):165-74. <https://journalajrrga.com/index.php/AJRRGA/article/view/146>.

Cadmium Chloride (CdCl₂); Group 5: Colitis + CdCl₂; Group 6: Colitis + vitamin E; Group 7: CdCl₂ + vitamin E; Group 8: Colitis + CdCl₂ + vitamin E.

Place and Duration of Study: Department of Physiology, Faculty of Basic Medical Sciences, Ladoke Akintola University of Technology, Ogbomoso, Oyo state Nigeria, between January 2024 and May 2024.

Methodology: The experiment lasted 30 days. CdCl₂ (50mg/kg b.w) was administered orally for 21 days, Colitis was induced on day 23 with 2 mL/200g of 6% acetic acid intra-rectally, while the animals were treated with vitamin E (100mg/kg b.w) for 7 days. Diarrhea score and body weight changes were assessed during the course of the experiment. Oxidative stress markers: Superoxidase dismutase (SOD) and Catalase (CAT); inflammatory markers: Myeloperoxidase (MPO) and Tumor Necrosis Factor alpha (TNF- α); Neutrophils and Lymphocyte counts and colon histology were also assessed. Data obtained was analyzed using one-way ANOVA, and Tukey's post hoc test was used for comparison of inter-group differences. $P < 0.05$ was considered statistically significant.

Results: The study showed significant body weight decrease and increased diarrhea scores in cadmium-exposed and colitis + cadmium groups. SOD and CAT activities were significantly depleted, while MPO activity and TNF- α levels were markedly elevated compared to normal control and vitamin E-treated groups. Neutrophil count decreased while lymphocyte count increased in Cd-exposed and colitis + cadmium groups compared to the normal control. Histological evaluation revealed inflammation and epithelial erosion in the colitis + cadmium group, with observed healing in vitamin E-treated groups.

Conclusion: This study revealed vitamin E's potential to mitigate oxidative stress and inflammation in colitis when heightened by cadmium toxicity. This findings provides new insights into the role of vitamin E in preventing and treating inflammatory conditions.

Keywords: Ulcerative colitis; vitamin E; cadmium chloride; oxidative stress.

1. INTRODUCTION

Ulcerative colitis (UC), a prevalent form of inflammatory bowel disease (IBD) is a chronic inflammatory condition that affects the gastrointestinal tract, particularly the distal colon and rectum [1]. The pathogenesis of this inflammatory condition remains elusive, yet its prevalence is attributed to a multifaceted interplay of factors such as geographical location, diet, genetics, immune response aberrations, and environmental triggers [2,3,4]. It is a relapsing disease that presents with symptoms such as abdominal discomfort, rectal bleeding, bloody watery stool and weight loss [5,6]. Previous studies have reported that ulcerative colitis is on the rise particularly in developing countries [7], affecting more than 3.5 million people worldwide and this presents as a major health challenge [8]. Cases of ulcerative colitis have been well-reported in the Western world [9,10,11] with significant variation in the incidence and prevalence in different countries. However, a study carried out by Watermeyer et al. [7] on the epidemiology of IBD reported that a quite number of cases on UC are beginning to rise in some sub-Saharan countries where it was initially uncommon. The continuing rise in UC occurrences has been attributed to

industrialization which was associated with environmental contaminants [12].

Cadmium (Cd) with atomic number 48, is a heavy toxic metal that accumulates in our surroundings as a result of industrialization [13]. In a review conducted by Rafati et al. [13] Cd was identified as a potential global hazard which can infect a person through several routes such as, air, water and food; and this can cause deleterious effect on some organs and systems of the body. A study conducted by Adegoke et al. [14] revealed that Cd toxicity can aggravate the clinical course of UC. Studies have also established that Cadmium poisoning can cause an individual to be susceptible to ulcerative colitis [15].

Nutritional interventions, especially vitamins have been identified as an effective treatment option in managing inflammatory conditions [16]; and one of such is vitamin E. Vitamin E, also referred to as Tocopherol, is a micronutrient and a natural antioxidant is known to modulate immune function and neutralize free radicals by protecting the cell membrane against oxidation of polyunsaturated fatty acids (PUFA) [17]. The regulatory role of vitamin E in disease management was recently reviewed by Jiang et al. [18] where it was reported of its potential

effects in quenching reactive oxygen species (ROS) and mitigating inflammation. Several studies have highlighted the benefits of consuming diets rich in tocopherols due to its anti-inflammatory property which helps in reducing the impact of oxidative stress on the immune system [19].

In managing ulcerative colitis, conventional treatments such as 5-amino salicylic acid (5-ASA), sulfasalazine, antibiotics, immunosuppressive agents, steroids (glucocorticoid), and anti-tumor necrosis factor (TNF)- α (infliximab), usually cause serious side effects and sometimes, patients do not respond effectively to those drugs [20]. These kinds of treatments often lead to immune suppression, culminating in a compromised quality of life [21], and studies have established that individuals grappling with ulcerative colitis often exhibit micronutrient deficiencies [22]. From literature searches, there are little or no studies on the role of vitamin E on ulcerative colitis when exacerbated by this toxic heavy metal; therefore, this study was designed to investigate the protective role of vitamin E on ulcerative colitis when exposed to cadmium toxicity [23].

2. MATERIALS AND METHODS

2.1 Chemicals and Supplement

The chemicals and supplement used in this study were of high analytical grade. Acetic acid (Eastman Chemical Company, United States), Cadmium chloride (Sigma chemical Co., India), Formalin (Hexion Inc. United States); Vitamin E (Gujarat pharmacaps, India)

2.2 Animals

The Wistar rats were obtained from the Animal House of Ladoke Akintola University of Technology Ogbomoso Oyo State. They were acclimatized for two weeks prior commencement of the experiment. They were housed in ventilated plastic cages and kept under standard conditions (12hr light and 12hr dark period; temperature- 28-31°C) with food (pelletized feed) and water *ad libitum* readily accessible to them.

2.3 Experimental Design

Forty male Wistar rats weighing 180 \pm 20 g were randomly distributed into eight groups (n=5) with each group receiving different treatments. Group 1 (Normal control): received distilled water for 30 days. Group 2 (Vitamin E): received 100 mg/kg

B.W of Tocopheryl acetate for 7 days. Group 3 (Colitis): received single intra-rectal administration of 2ml/200g B.W of 6% acetic-acid on the 23rd day. Group 4 (Cadmium): received 50mg/kg B.W of Cadmium Chloride (CdCl₂) for 30 days. Group 5 (Colitis + Cadmium): colitis was induced after CdCl₂ exposure. Group 6 (Colitis + Vitamin E): received Tocopheryl acetate for 7 days after 24 hrs post-colitis induction. Group 7 (Cadmium + Vitamin E): received Tocopheryl acetate for 7 days after being exposed to CdCl₂ for 23 days. Group 8 (Colitis + Cadmium+ Vitamin E): received CdCl₂ for 21 days, induced with colitis on the 23rd day, thereafter the rats were treated with Tocopheryl acetate for 7 days

2.4 Induction of Colitis

After 21 days of cadmium exposure, rats in group 3, 5, 6 and 8 were left to fast for 24 hours prior to colitis induction. Rectal flushing was done to remove faecal remnant and then intra-rectal administration of 2ml/200g body weight of 6% Acetic acid (AA) was done with the aid of a rectal cannula, which was inserted into the colon through the rectum (8cm proximal to the anus) and the animals were retained for 55 seconds in a Trendelenburg position to avoid liquid extravasation as described by Dodda et al. [24].

2.5 Collection of Blood and Tissue Samples

The rats were anaesthetized with ketamine (50mg/kg) before the sacrifice. The heart was punctured and blood samples were collected using a syringe and stored into Ethylene diamine tetra acetic acid (EDTA) bottles for haematological analysis. The colons (distal 6cm) were excised and carefully cleaned of blood stains and faecal content to avoid stretch and then stored appropriately for biochemical and histology analyses.

2.6 Colitis (Stool) Scoring

During the course of the experiment, the stool of the animals were observed and recorded daily by using the method of Masonobi et al. [25] with little modifications as follows: 0 – normal stool; 1 – normal stool with blood; 2 – loose stool without blood; 3 – loose stool with visible blood; 4 – blood watery stool.

2.7 Body Weight Changes

Each rat was weighed every week by using a digital weighing scale (Citizen Model MP2000).

Before the sacrifice, they were also weighed and the change in weight was obtained using this formula: Weight Changes = final weight (before sacrifice) – initial weight (before colitis induction).

2.8 Biochemical Analysis

The proximal part of the colon was homogenized in phosphate buffer solution (PBS) and then centrifuged at a speed of 16,000rpm at 4°C for 20 minutes and the resultant supernatants were kept at 4°C for biochemical assay. Oxidative stress markers such as: Superoxide Dismutase (SOD) and Catalase (CAT) were analysed using calorimetric method as described by Misra and Fridovich [26] and Cohen et al. [27] respectively. Inflammatory stress markers such as: Myeloperoxidase (MPO) and Tumor Necrosis Factor alpha (TNF- α) as described by Sands [28] were assayed using Enzyme-Linked Immunosorbent Assay (ELISA) kit (Elabscience Biotechnology Inc., U.S.A).

2.9 Histological Analysis

The distal part of the colonic tissue was rinsed in ice-cold normal saline and then fixed in 10% formalin solution. The tissue was removed after 24hrs and alcohol was added to induce dehydration. The tissue was then put in wax bath for infiltration, which was set to run for twelve hours in order to harden/block. It was deparaffinised with xylene and chopped (using a microtome) into tiny pieces, no thicker than 4 mm and then stained with haematoxylin and eosin (H & E) to improve the contrast of the tissue structures for proper microscopic evaluation. The stained sections were assessed under a light microscope and then photomicrographs were taken at 100 magnifications for assessment of any histo-pathological alteration [29].

2.10 Statistical Analysis

The data was represented as mean \pm SEM. With the aid of Graph pad Prism version 7.0 (Graph Pad statistical software. Inc. USA), one-way analysis of variance (ANOVA) was used to analyse the data. To compare results within different groups, Tukeys' post-hoc test was also employed.

3. RESULTS AND DISCUSSION

The body weight of cadmium group and colitis+ cadmium group was significantly decreased

when compared with the control group (Table 1).The decrease in body weight might be due to a decline in the absorption of lipids and proteins which could be caused by cadmium exposure. Studies have shown that cadmium, when inhaled or ingested can compromise metabolism resulting in low weight gain [14,30].

Cadmium exposure increased the stool consistency score in the colitis + cadmium group when compared with the colitis group and cadmium group (Table 2). Inflammatory responses of acetic acid-induced colitis, in addition to cadmium's existing effect might have increased oxidative stress in the GIT of the rats, thereby reducing colitis healing (as measured by stool consistency score) and this findings corroborates with the work of Adegoke et al. [31].

Neutrophil and lymphocyte ratio is an index used in determining disease progression particularly in inflammatory conditions [32]. When compared to the control group, there was a significant increase in neutrophil count in cadmium group and colitis + cadmium group and significant decrease in lymphocyte count in cadmium group when compared with the control and vitamin E group (Table 3).This could likely be due to the continuous activation of inflammatory cells caused by cadmium [14].

Superoxide dismutase (SOD) is known to be the first line of defense in GIT against free radicals by attenuating oxidative stress associated with ulcerative colitis. In this study, the depletion of SOD activities in colitis + cadmium group illustrates how cadmium exposure and acetic acid-induced colitis work together to weaken endogenous antioxidant defenses (Fig. 1). Cadmium, which is a heavy toxic metal, interferes with antioxidant enzymes and causes reactive oxygen species (ROS) to be produced; and this upsets cellular redox homeostasis. Earlier research of Valko et al. [33] revealed that cadmium-induced ROS production not only diminishes SOD activity but also triggers a cascade of events that exacerbate tissue damage and inflammation. On treatment with vitamin E, SOD concentration was improved in the colitis + Cd + vit E group ($P < .01$) when compared to the colitis + Cd group. Studies have shown that vitamin E can interrupt lipid peroxidation by scavenging lipid-derived radicals, which could contribute to the preservation of SOD activity [34,35].

Table 1. Effect of Vitamin E on Body Weight Changes of Cadmium Exposed Colitic Wistar Rats

Groups	Final Weight(g)	Initial Weight(g)	Weight Changes (g)
Control	213.0 ± 4.669	158.2 ± 2.596	54.8 ± 2.073
Vitamin E	149.4 ± 3.600	115.0 ± 3.066	34.4 ± 0.534
Colitis	210.8 ± 3.891	181.2 ± 3.023	29.6 ± 0.868
Cadmium	172.0 ± 3.033	191.2 ± 3.760	-19.2 ± 0.727 ^a
Colitis + cadmium	183.2 ± 4.944	175.6 ± 6.120	7.6 ± 1.176 ^b
Cadmium + Vitamin E	200.2 ± 9.609	184.0 ± 13.87	16.2 ± 4.261
Colitis + Vitamin E	169.2 ± 14.11	152.8 ± 11.97	16.4 ± 2.14
Colitis + cadmium Vitamin E	194.6 ± 5.528	176.8 ± 5.526	17.8 ± 0.002

^arepresents significant decrease at P = .05 when compared with Control group. ^brepresents significant decrease at P = .05 when compared with colitis + cadmium + vitamin E group

Table 2. Effect of Vitamin E on Diarrhea Score of Cadmium Exposed Colitic Wistar Rats

Groups	Diarrhea Score
Control	0.00 ± 0.00
Vitamin E	0.00 ± 0.00
Colitis	0.60 ± 0.25
Cadmium	0.20 ± 0.20
Colitis + cadmium	1.50 ± 0.87 ^a
Cadmium + vitamin E	0.20 ± 0.20
Colitis + vitamin E	0.40 ± 0.40
Colitis + cadmium + vitamin E	0.80 ± 0.37

^arepresents significant decrease at P = .05 when compared with colitis and cadmium group

Table 3. Effect of Vitamin E and Cadmium on Neutrophil and Lymphocyte Counts

NLR	Control	Vit E	Colitis	Cadmium (Cd)	Colitis + Cd	Colitis + Vit E	Cd + Vit E	Colitis + Cd + Vit E
NEU	31.20 ± 2.15	28.50 ± 5.05	37.75 ± 4.00	54.00 ± 3.83 ^a	58.67 ± 3.48 ^b	28.67 ± 3.66	42.25 ± 1.54	39.25 ± 3.90 ^c
LYM	65.80 ± 1.28	67.00 ± 4.35	63.40 ± 4.35	39.40 ± 5.84 ^a	49.40 ± 6.15 ^b	69.00 ± 3.48	53.40 ± 3.54	63.40 ± 79.40 ^c

Significant increase in neutrophil count (P = .05) and decrease in lymphocyte count (P < .01) of cadmium group and colitis + cadmium group, when compared with colitis + cadmium +vitamin E group

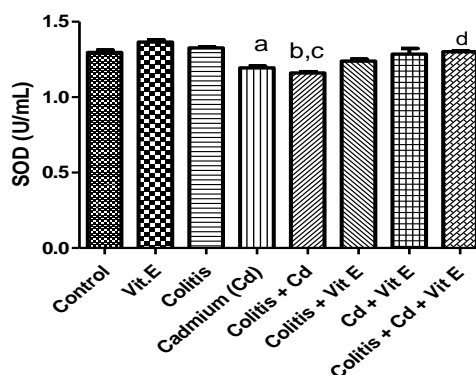


Fig. 1. Effect of Vitamin E on Superoxide Dismutase Activity of Cadmium Exposed Colitic Wistar Rats

Data were presented as mean ± SEM of 5 rats ^a represents significant decrease at P = .05 when compared with control group. ^brepresents significant decrease at P = .05 when compared with control group. ^crepresents significant decrease at P < .01 when compared with the colitis group. ^drepresents significant increase at P < .01 when compared with colitis + cadmium group

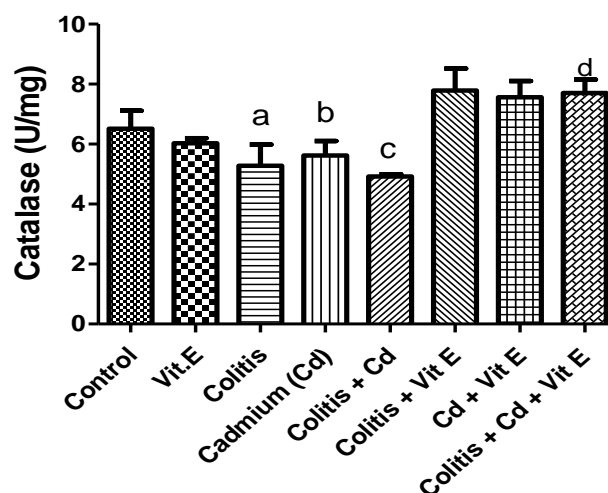


Fig. 2. Effect of Vitamin E Catalase Activity of Cadmium Exposed Colitic Wistar Rats

Data were presented as mean \pm SEM of 5 rats ^{a,b} represents significant decrease at $P = .05$ when compared with control group. ^c represents significant decrease at $P = .05$ when compared with the colitis + cadmium + vit E group). ^d represents significant increase at $P = .05$ when compared with the colitis + cadmium group

Catalase, which is also an essential endogenous antioxidant, operates by using hydrogen peroxide detoxification to stop the build-up of ROS [36]. The result revealed depleted catalase activity in the colitis, cadmium, and colitis + cadmium groups when compared with vitamin E treated groups as shown in Fig. 2. This finding corresponds with previous studies, proving vitamin E's ability to mop up free radicals from the cytosol of the mitochondria [34].

Myeloperoxidase (MPO) is a heme-containing enzyme predominantly expressed in neutrophils, and plays a pivotal role in catalyzing the formation of ROS and contributing to tissue damage [37]. Cadmium exposure led to elevated MPO activity in the cadmium and colitis + cadmium groups when compared with the control group, which were elicited by pro-inflammatory milieu resulting in the infiltration of neutrophils in the cellular level (Fig. 3). The observed up-regulation of MPO could be attributed to the synergistic interaction between colitis-induced tissue damage and cadmium-induced inflammation. In contrast, MPO activity was significantly decreased in the vitamin E treated groups. This result accentuates with previous studies of the potential ameliorative role of vitamin E in mitigating neutrophils recruitment in the colonic mucosa [34,38].

Inflammation, though a physiological response lies at the heart of numerous pathological

conditions, including inflammatory bowel diseases and exerts a multi-layered influence on cellular and systemic homeostasis. Tumor necrosis factor (TNF- α), a potent pro-inflammatory cytokine holds a central role in modulating immune response. In this study, TNF- α activity was markedly increased in the colitis + cadmium group when compared with the control group, colitis group and cadmium group (Fig. 4). This may possibly be due to cadmium potential to activate Mitogen-Activated Protein Kinase (MAPK) pathways, thereby exacerbating inflammation on the colonic mucosa of the rats [39,40]. The anti-inflammatory property of vitamin E was able to suppress the pro-inflammatory cytokines in the colonic tissues and this findings is consistent with the work of Kini et al. [38]

Histological analysis revealed that, the combined effect of colitis and cadmium eroded the epithelium and inflamed the colonic tissues, thereby slowing the healing process. Comparing the intact structure of crypts in the control and vitamin E groups to the colitis + cadmium group, cross-sections of the colonic tissue samples revealed multiple instances of inflammatory infiltration, particularly into the lamina propria and submucosa, deterioration of crypt architecture, and formation of crypt abscess. This could be as a result of cadmium's on-going stimulation of colonic inflammatory cells over time. Similar result was reported by Zalups and Ahmad [41] they iterated that oral administration of cadmium

compounds resulted in colonic epithelial desquamation. Healing process was observed in colitis + cadmium group treated with vitamin E. This led to the reduction in the wide spread of inflammatory reaction and tissue damage brought on by colitis and cadmium exposure.

The mucosal crypts and lamina propria of the control and vitamin E group appears normal (white arrow). There is mild inflammation of the mucosal crypts and lamina propria of the colitis group, cadmium group and cadmium +

vitamin E group (blue arrow). The mucosal crypts, lamina propria and submucosa of the colitis + cadmium group shows chronic inflammation composed of large lymphoid follicles and a disrupted mucosal crypt architecture (red arrow). The lamina propria of colitis + vitamin E also appears inflamed mildly (black arrow). In colitis + cadmium + vitamin E group, there is mild inflammation on the lamina propria (yellow arrow), and healing already taking place on some part of the lamina propria (green arrow) (Fig. 5).

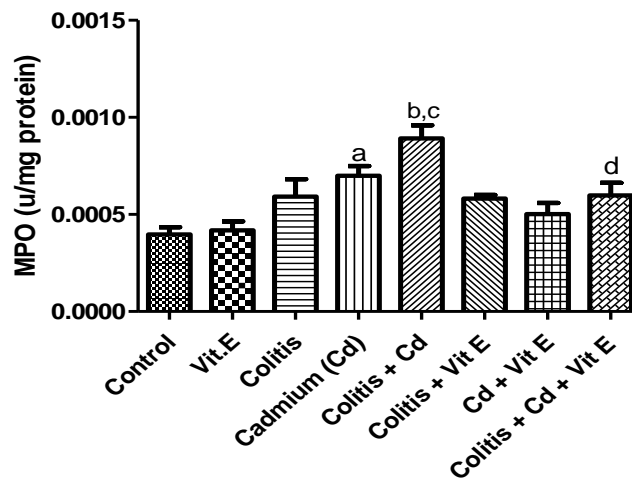


Fig. 3. Effect of Vitamin E on Myeloperoxidase Activity of Cadmium Exposed Colitic Rats

Data were presented as mean \pm SEM of 5 rats ^a represents significant increase at $P = .05$ when compared with control group. ^b represents significant increase at $P < .001$ when compared with the control group. ^c represents significant increase at $P = .05$ when compared with colitis induced group. ^d represents significant decrease at $P < .05$ when compared with vitamin E treated groups

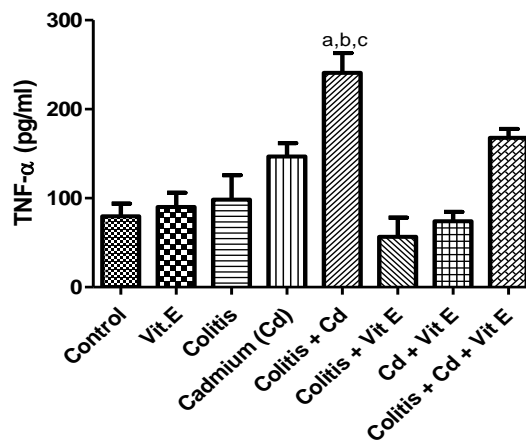


Fig. 4. Effect of Vitamin E on Tumour Necrosis Factor-Alpha of Cadmium Exposed Colitic Wistar Rats

Data were presented as mean \pm SEM of 5 rats ^a represents significant increase at $P < .001$ when compared with control group. ^b represents significant increase at $P < .01$ when compared with colitis-induced group. ^c represents significant increase at $P < .05$ when compared with Cd-exposed group

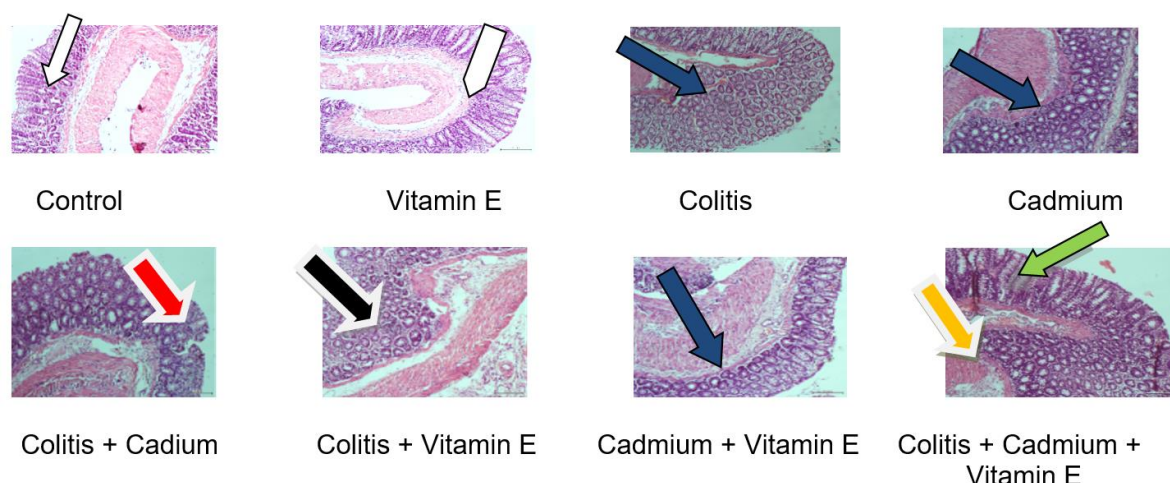


Fig. 5. Histological assessment

Photomicrographs: (histological assessment of the mucosa of cadmium exposed colitic rats H&E x100 magnification)

4. CONCLUSION

From this study, vitamin E treatment proved to be an excellent free radical scavenger by ameliorating the diarrhea of the colitis group exposed to cadmium compound, which led to an improvement in their body weight. Vitamin E improved the redox status by mitigating oxidative stress, inhibiting neutrophils infiltration, down-regulated pro-inflammatory cytokines, and reversing the histo-pathological damages on the colonic mucosa. This study therefore accentuates the effectiveness of vitamin E as an intervention strategy in alleviating colitis when exacerbated by cadmium exposure.

The study not only provides new insights into the role of vitamin E in preventing and treating cadmium toxicity but also paves the way for further exploration of vitamin E as a possible treatment option in combating health issues arising from environmental pollutants

DISCLAIMER (Artificial intelligence)

Author(s) hereby declare that NO generative AI technologies such as Large Language Models (ChatGPT, COPILOT, etc) and text-to-image generators was used during writing or editing of manuscripts.

CONSENT

It is not applicable.

ETHICAL APPROVAL

Ethical approval (ERCFBMSLAUTECH: 020/01/2024) was obtained from the Ethics Research Committee (ERC) of Faculty of Basic

Medical Science of the institution, and the animals were handled according to the International Guidelines on the Care and Use of Laboratory Animals in Research [23].

COMPETING INTERESTS

Authors have declared that no competing interests exist.

REFERENCES

1. Antoniussen C, Rasmussen H, Holst M and Lauridsen C. Reducing disease activity of inflammatory bowel disease by consumption of plant-based foods and nutrients. *Frontiers In Nutrition*. 2021;8: 733433. DOI: 10.3389/Fnut.733433
2. Seyed S, Forogh N, Mehrdad D. A review of the diagnosis, prevention, treatment methods of inflammatory bowel disease. *Journal Of Medicine and Life*. April-June 2019;12(2):113–122. DOI: 10.25122/Jml-2018-0075
3. Ihara S, Hirata Y, Koike K. Inflammatory bowel disease: A key regulator of immune cells, epithelium and the intestinal microbiota. *Journal of Gastroenterology*. 2017;52:777–787. [Crossref]
4. Glassner KI, Abraham Bp, Quigley Emm. The microbiome and inflammatory bowel disease. *Journal of Allergy and Clinical Immunology*. 2020;145:16–27.
5. Adeniyi OF, Odeghe E, Olatona F A, et al. Inflammatory bowel disease in children: Experience and constraints in a resource limited setting. *Cureus* 2020;12(4):E7848.

6. Ungaro R, Mehandru S, Allen Pb, Peyrin-Biroulet L, Colombel Jf. Ulcerative Colitis. *Lancet* (London, England). 389:1756–70. DOI: 10.1016/S0140-67361632126-2
7. Watermeyer G, Katsidzira L, Setshedi M, Devani S, Mudombi W, Kassianides C. Inflammatory bowel disease in Sub-Saharan Africa: Epidemiology, risk factors, challenges in diagnosis. *The Lancet Gastroenterology & Hepatology*. 2022; 7(10):952-961.
8. Ng S.C, Shi Hy, Hamidi N. Worldwide Incidence and prevalence of inflammatory bowel disease in the 21st Century: A Systematic Review of Population-Based Studies. *Lancet* (London, England. 2017;390:2769–78.
9. Benchimol Ei, Mack Dr, Guttman A, et al. Inflammatory bowel disease immigrants to Canada and their children: A population based cohort study. *American Journal of Gastroenterology*. 2015;110:553-563. DOI: 10.1038/Ajg.2015.52
10. Zhou Y, Huang Y Inflammatory bowel disease in Chinese children: A retrospective analysis of 49 cases. *Experimental and Therapeutic Medicine*. 2016;12:3363-3368.
11. Marginean CO, Melit Le, Mocanu S, Marginean Mo, Marginean S. Inflammatory bowel diseases: A burden in pediatrics case series and a review of the literature. *Medicine*. 2017;96:E6329. DOI: 10.1097/Md.0000000000006329
12. Ekwunife Cn, Nweke Ig, Achusi Ib, Ekwunife Cu. Ulcerative colitis prone to delayed diagnosis in a Nigerian population: Case series. *Annals of Medicine and Health Science Research*. 2015;5:311-313.
13. Rafati RM, Kazemi S, Moghadamnia A. Cadmium toxicity and treatment: An update. *Caspian Journal of Internal Medicine*. 2017;8(3):135-145.
14. Adegoke A.G, Salami At, Olaleye Sb. Cadmium exacerbates acetic acid induced experimental colitis in rats. *European Journal of Experimental Biology*. 2017; 7(5):27. DOI: 10.21767/2248-9215.100027
15. Breton J, Daniel C, Vignal C, Mathilde B, Anne G, Coline P. Does oral exposure to cadmium and lead mediate susceptibility to colitis? The dark-and-bright sides of heavy metals in Gut Ecology. *Scientific Reports*. 2016;6:19200. DOI: 10.1038/Srep19200
16. Sigall-Boneh R, Levine A, Lomer M, Wierdsma N, Allan P, Fiorino G. Research gaps in diet and nutrition in inflammatory bowel disease. A topical review by D-Ecco working group (Dietitians of Ecco). *Journal of Crohns Colitis*. 2017; 1407–19. DOI: 10.1093/Ecco-Jcc/Jjx109
17. Hong Y, Daniel W, Wupeng L, Fred W. Vitamin E Therapy Beyond Cancer: Tocopherol Versus Tocotrienol, *Pharmacology & Therapeutics*. 2016;162: 152-169, Available: <https://doi.org/10.1016/>
18. Jiang Q, Im S, Wagner JG, Hernandez ML, Peden DB. Gamma-tocopherol, A major form of vitamin E in diets: Insights into antioxidant and anti-inflammatory effects, Mechanisms, Roles In Disease Management. *Free Radical Biology and Medicine*. 2022;178:347-359.
19. Shahidi F, De Camargo Ac. Tocopherols and tocotrienols in common and emerging dietary sources: Occurrence, applications, health benefits. *International Journal of Molecular Sciences*. 2016;17(10):1745. Available: <https://doi.org/10.3390/Ijms17101745>
20. Ben-Horin S, Mao R, Chen M. Optimizing biologic treatment in IBD: Objective measures, but when, how and how often? *Bmc Gastroenterology*. 2015;15:178. [Crossref, Pubmed]
21. Harbord M, Eliakim R, Bettenworth D, Karmiris K, Katsanos K, Kopylov U, et al. Third European Evidence-based consensus on diagnosis and management of Ulcerative Colitis. Part 2: Current Management. *Journal of Crohn's and Colitis*. 2017;11:769–784. [Crossref, Pubmed].
22. Sugihara K, Morhardt TI, Kamada N. The role of dietary nutrients in inflammatory bowel disease. *Frontiers in Immunology*. 2019;9:3183. DOI: 10.3389/Fimmu.2018.03183
23. National Research Council. Guide for the care and use of laboratory animals. 8th Ed. Washington: The National Academies Press; 2011.
24. Dodda D, Chhajed R, Mishra J. Protective effect of quercetin against acetic acid induced inflammatory bowel disease (IBD) like symptoms in rats: Possible morphological and biochemical alterations. *Pharmacological Reports*. 2014;66(1):169-173.

25. Masonobi F, Osamu K, Yoshio A, Akira A, Kehchi M, Kohsuke T, et al. Prebiotic treatment of experimental colitis with germinated barley foodstuff; A Comparison with Probiotic or Antibiotic Treatment. *Int. J. Mol. Med.* 2002;9:65-70.
26. Misra H And Fridovich I. The role of superoxide anion in the autoxidation of epinephrine and a simple assay for superoxide dismutase. *J. Biol. Chem.* 1972;247(10):3170-3175.
27. Cohen G, Kim M, Ogwa V. A modified catalase assay suitable for a plate reader. *Journal of Neuroscience Methods.* 1996;67(1):53-56.
28. Sands BE. Biomarkers of inflammation in inflammatory bowel disease. *Journal of Gastroenterology* 2015;149(5):1275-1285.
29. Ogihara Y, Okabe S. Effect and mechanism of sucralfate on healing of acetic acid-induced gastric ulcers in rats. *J Physiol Pharmacol.* 1993;44:109-118.
30. Singh P, Mogra P, Bano H, Sankhla V, Deora K, et al. Protective and preventive effects of curcumin against cadmium chloride induced gastrointestinal toxicity in Swiss albino mice. *World Journal of Science and Technology* 2012;2:10-17.
31. Adegoke AG, Olaleye SB, Kolaviron, A flavonoid from garcinia kola seeds, Ameliorates Experimental Colitis in Rats Exposed To Cadmium. *The Faseb Journal.* 2018;32:Lb361-Lb361.
32. Celikbilek M, Dogan S, Ozbakir O, Zararsiz G, Küçük H. Neutrophil-lymphocyte ratio as a predictor of disease severity in ulcerative colitis. *J Clin Lab Anal.* 2013;27:72-76.
33. Valko M, Morris H, Cronin MT. Metals, toxicity and oxidative stress. *Current Medicinal Chemistry.* 2005;12(10):1161-1208.
34. Jiang Q, Im S, Wagner JG, Hernandez ML, Peden DB. Gamma-tocopherol, a major form of vitamin E in diets: Insights into antioxidant and anti-inflammatory effects, Mechanisms, Roles in Disease Management. *Free Radical Biology and Medicine.* 2022;178:347-359.
35. Tefagh G, Payab M, Qorbani M, Sharifi F, Sharifi Y, Ebrahimnegad S, et al. Effect of vitamin E supplementation on cardiometabolic risk factors, inflammatory and oxidative markers and Hormonal Functions in Pcos (Polycystic Ovary Syndrome): A Systematic Review and Meta-Analysis. *Scientific Reports.* 2022; 12(1):5770.
36. Baker A, Lin CC, Lett C, Karpinska B, Wright MH, Foyer CH. Catalase: A critical node in the regulation of cell fate. *Free Radical Biology and Medicine.* 2023;199: 56-66.
37. Aratani Y. Myeloperoxidase: Its role for host defense, inflammation, Neutrophil Function. *Archives of Biochemistry and Biophysics.* 2018;640:47-52.
38. Kini RD, Tripathi Y, Raghuvver CV, Pai SR, Ramswamy C, Nayanatara AK. Protective role of vitamin E against cadmium chloride induced testicular damage in rats. *Journal of Physiology and Biomedical Sciences.* 2009;22:12-6.
39. Hu KH, Li WX, Sun MY, Zhang SB, Fan CX, et al. Cadmium induced apoptosis in mg63 cells by increasing ros, activation of P38 Mapk and inhibition of Erk 1/2 Pathways. *Cellular Physiology and Biochemistry.* 2015;36(2):642-654.
40. Cao X, Fu M, Bi R, Zheng X, Fu B, Tian S, et al. Cadmium induced beas-2b cells apoptosis and mitochondria damage via mapk signaling pathway. *Chemosphere.* 2021;263:128346.
41. Zalups Rk, Ahmad S. Molecular handling of cadmium in Epithelia. *Toxicology and Applied Pharmacology.* 2003;186:163-188.

Disclaimer/Publisher's Note: The statements, opinions and data contained in all publications are solely those of the individual author(s) and contributor(s) and not of the publisher and/or the editor(s). This publisher and/or the editor(s) disclaim responsibility for any injury to people or property resulting from any ideas, methods, instructions or products referred to in the content.

© Copyright (2024): Author(s). The licensee is the journal publisher. This is an Open Access article distributed under the terms of the Creative Commons Attribution License (<http://creativecommons.org/licenses/by/4.0>), which permits unrestricted use, distribution, and reproduction in any medium, provided the original work is properly cited.

Peer-review history:

The peer review history for this paper can be accessed here:

<https://www.sdiarticle5.com/review-history/122078>