



Primary Sclerosing Encapsulating Peritonitis and Meckel's Diverticulum in a Patient with Small Bowel Obstruction: A Rare Entity

Junaid Sofi ^{a,b*}, Fozia Nazir ^{c,d}, Atehar R. Sofi ^d
and Ashwani Gupta ^b

^a Urology, Northwick Park Hospital, Harrow, UK.

^b Department of Surgery, Vardhman Mahavir Medical College and Safdarjung Hospital, New Delhi, India.

^c Emergency General Surgery, Hillingdon Hospital, Uxbridge, UK.

^d Department of General and Minimal Invasive Surgery, Sher-i-Kashmir Institute of Medical Sciences, Srinagar, India.

Authors' contributions

This work was carried out in collaboration among all authors. All authors read and approved the final manuscript.

Article Information

Open Peer Review History:

This journal follows the Advanced Open Peer Review policy. Identity of the Reviewers, Editor(s) and additional Reviewers, peer review comments, different versions of the manuscript, comments of the editors, etc are available here: <https://www.sdiarticle5.com/review-history/121031>

Case Report

Received: 04/06/2024

Accepted: 06/08/2024

Published: 10/08/2024

ABSTRACT

Background: Sclerosing Encapsulating Peritonitis (SEP) is a rare cause of small bowel obstruction. There are other similar and rare entities like peritoneal encapsulation found in different age groups. Management in severe cases is mostly surgical. Laparoscopic approach may be useful

*Corresponding author: E-mail: sofijunaid@gmail.com;

Cite as: Sofi, Junaid, Fozia Nazir, Atehar R. Sofi, and Ashwani Gupta. 2024. "Primary Sclerosing Encapsulating Peritonitis and Meckel's Diverticulum in a Patient With Small Bowel Obstruction: A Rare Entity". *Asian Journal of Case Reports in Surgery* 7 (2):398-405. <https://journalajcrs.com/index.php/AJCRS/article/view/557>.

for diagnosis but difficult to proceed with. It is important to differentiate between idiopathic (primary) SEP and secondary SEP as management may differ, especially in a Tubercular Abdomen.

Case Summary: We describe a case of Primary SEP in a 45-year-old male presenting as small bowel obstruction (SBO). Due to failure of conservative management patient underwent exploratory laparotomy, excision of the membrane, adhesiolysis, appendectomy and resection of Meckel's Diverticulum. On-table appearance fitted the picture of primary SEP, and no evidence of tubercular pathology was noted. The surgical treatment led to resolution of bowel obstruction, although this was complicated with a minor leak which was managed conservatively.

Conclusion: Primary SEP is a rare cause of small bowel obstruction. This entity is often confused with tubercular abdomen in tropics which may lead to delay in surgical treatment and should be differentiated from Secondary SEP which is more frequently encountered in patients with peritoneal irritation from various aetiologies. Nevertheless, preoperative diagnosis is difficult, and a high degree of suspicion is required for diagnosis.

Keywords: Sclerosing encapsulating peritonitis; small bowel obstruction; peritoneal encapsulation.

1. INTRODUCTION

Sclerosing Encapsulating Peritonitis, (SEP) is a rare cause of small bowel obstruction and has been previously confused with other similar appearing entities like peritoneal encapsulation that have different origins and outcomes. SEP is also known as cocoon abdomen and is characterised by a thick fibro-collagenous membrane encapsulating the small bowel which may be clattered and crowded and aggregated to various degrees [1].

SEP could be either idiopathic or secondary to peritoneal irritation and this differentiation can be difficult, but hints can be taken from history by the lack of inciting factors and confirmation by on-table lack of adhesion in between bowel loops in primary SEP and quick unravelling of bowel loops once the membrane is excised. Preoperative diagnosis requires a high degree of suspicion and remains a challenge and surgical morbidity can be high due to potential complications. This case report describes the presentation, workup and management and complications associated with SEP.

2. CASE PRESENTATION

We describe a case of Sclerosing Encapsulating Peritonitis, (SEP) and concurrent Meckel's Diverticulum in a 45-year-old of Indian origin gentleman with a background history of chronic abdominal pain for 9 years. No risk factors for peritoneal inflammation were noted in history except for high incidence of Tuberculosis in the region. He was admitted with symptoms of pain abdomen, recurrent vomiting and obstipation Examination had atypical findings of asymmetrical and localised tense abdominal

distension contained to left upper and right lower quadrant. Xray abdomen showed air fluids levels spread throughout the abdomen and impression of small bowel obstruction was made. Inflammatory markers were marginally increased with white cell count of 12,000/uL. Slightly raised creatinine due to vomiting was noted and normal liver functions. Lactate was 2.0 mmol/L.

Stomach was decompressed with a nasogastric tube and fluid resuscitation was commenced and empirical antibiotics were given. A foleys catheter was placed as well for output monitoring.

Contrast enhanced CT (CECT) revealed dilated small bowel loops covered by a membrane of variable thickness, no ascites, or other signs of tuberculosis in abdomen or chest and no signs of malignancy. The membrane was thinner in upper abdomen and was quite thick in mid/lower abdomen and septa were seen even in pelvis on CECT [Images 1, 2,3].

There was no improvement in the condition over next 48 hours and surgical exploration was agreed with the patient. Patient underwent an exploratory midline laparotomy. On laparotomy, the entire small intestine was found to be cocooned and enclosed in a thick fibrotic membrane with clumping of small bowel resulting in obstruction of the small intestine [Image 4]. In few areas, the membrane was as thick as a muscle sheath. Once the thick fibrous membrane was excised this led to revealing of tortuous dilated small bowels with some further flimsy overlying membranes. No significant inter bowel adhesions were encountered further pointing towards Primary SEP. The liver and stomach were free from the membrane. The membrane itself was not inflamed but was as

thick as sheath in some areas [Image 5]. The bowel underlying was not inflamed. Extensive excision of this thick membrane and release of

bowel loops revealed normal underlying small bowel and incidental Meckel's diverticulum [Images 6 and 7].

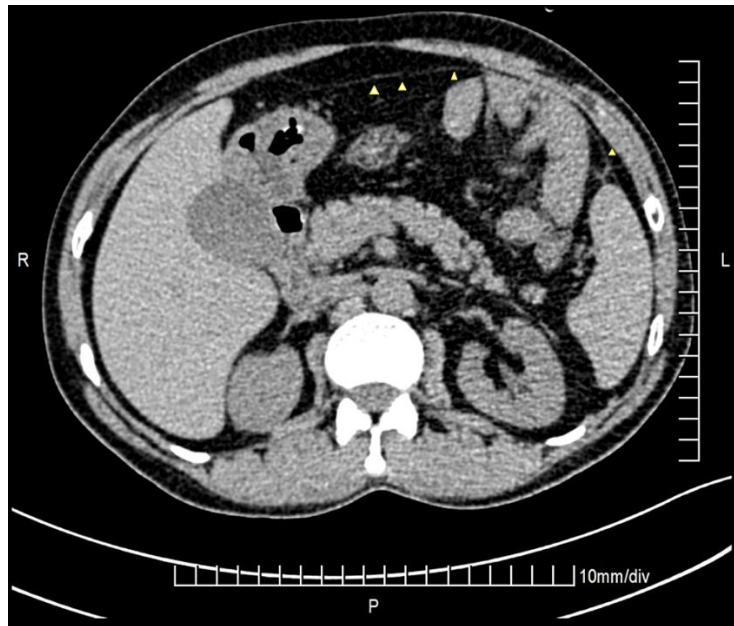


Image 1. CECT slice through upper abdomen showing the membrane (yellow arrowheads)
CECT: Contrast Enhanced Computerized Tomography

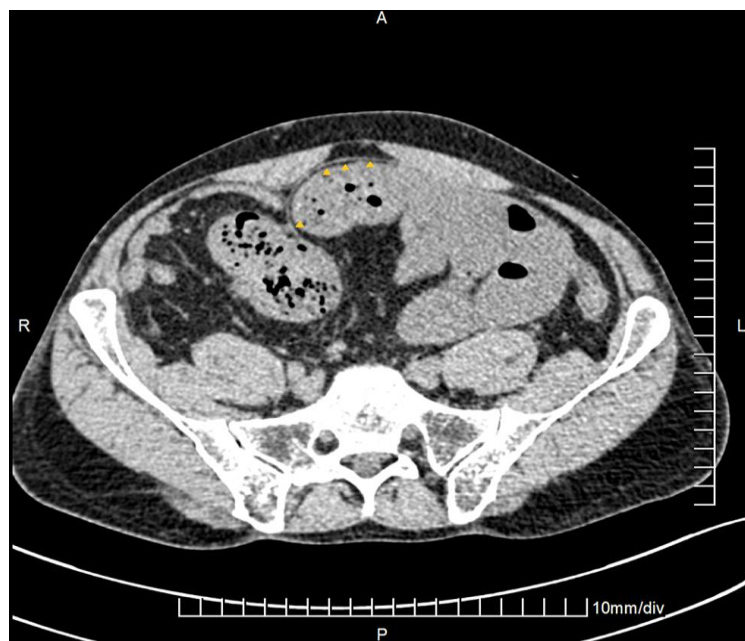

Image 2. CECT slice through upper pelvis showing dilated small bowels and thick membrane (yellow arrowheads)

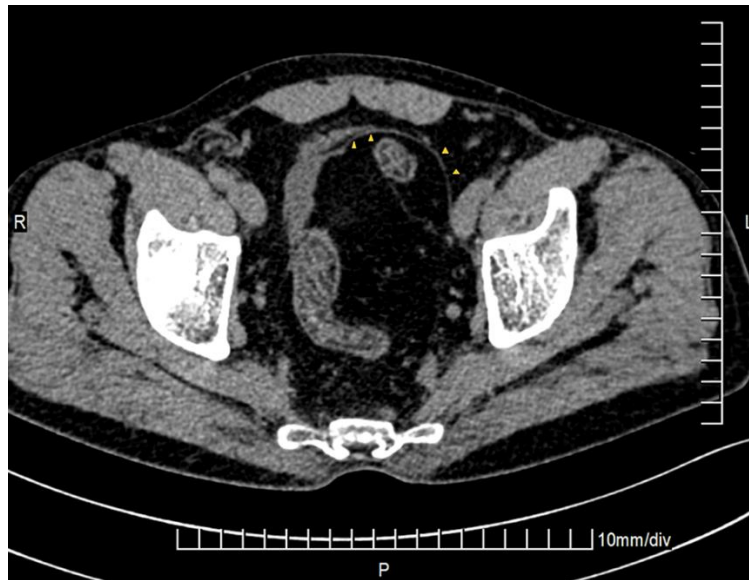

Image 3. CECT slice through lower pelvis showing membranes going down to the pelvis (yellow arrowheads)

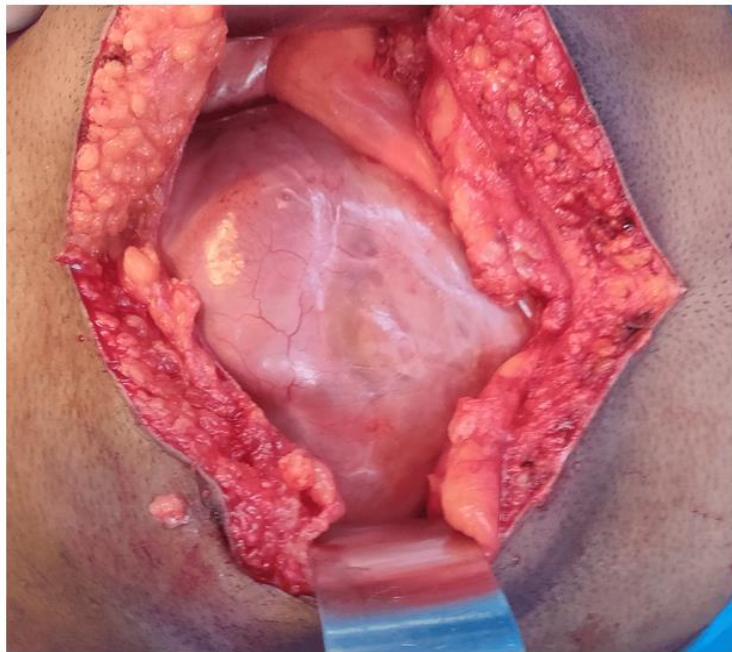


Image 4. Initial view of abdominal cavity showing thick membrane encasing bowels

Appendix was identified and appendectomy was done. Meckel's Diverticulum was resected given high probability of future adhesions making resection difficult. A drain was placed.

The histopathology report was consistent with non-specific dense fibrosis, focal areas of calcification and congestion and no granulomas were identified. Abdominal washings were negative for tuberculosis. Based on these

findings, a diagnosis of idiopathic sclerosing encapsulating peritonitis as a cause of small bowel obstruction was made.

Post-operative period was complicated by a minor leak via the abdominal drain which was managed conservatively and eventually the leak settled and drain was removed without requiring any further surgical intervention. Patient was doing well at 3 month follow up.

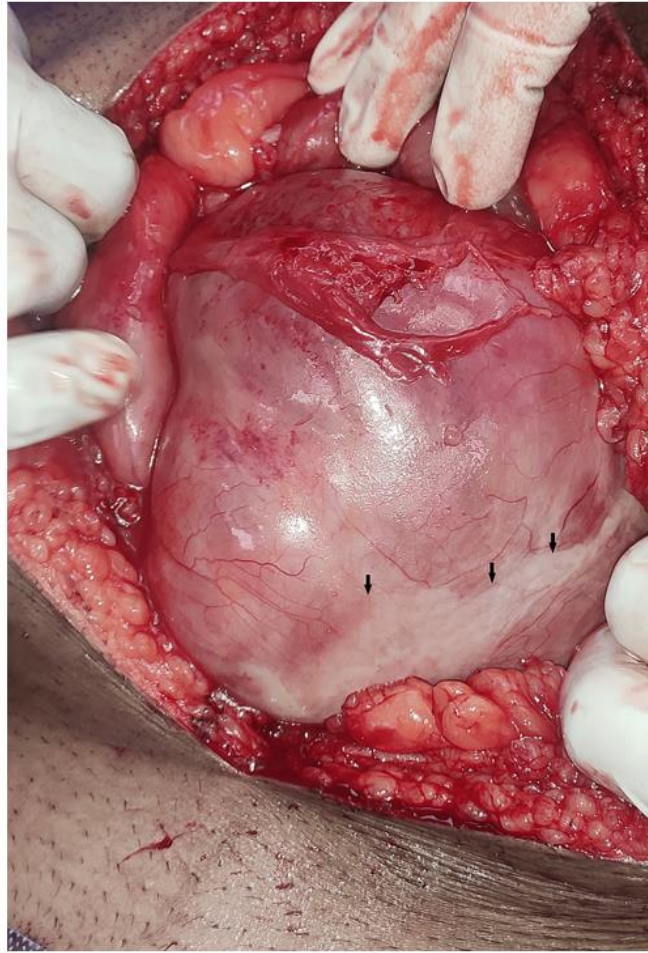


Image 5. The membrane was quite thick at some places (black arrows)

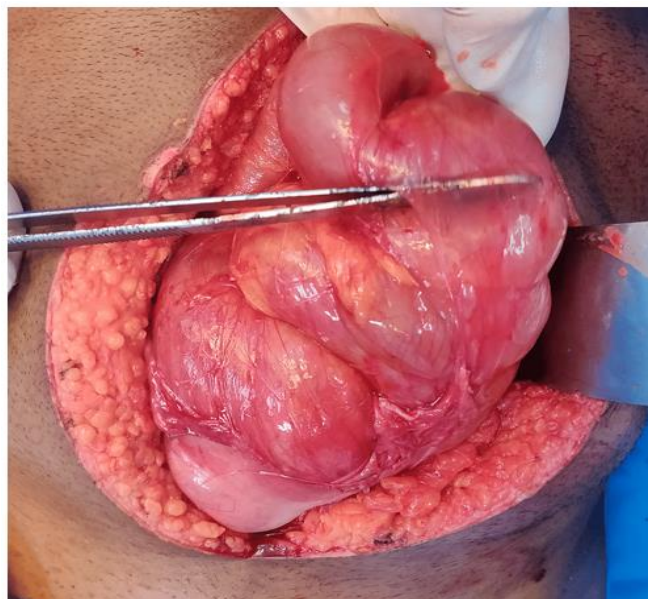


Image 6. Images post release and partial excision of the thick membrane showing small bowel beginning to unravel

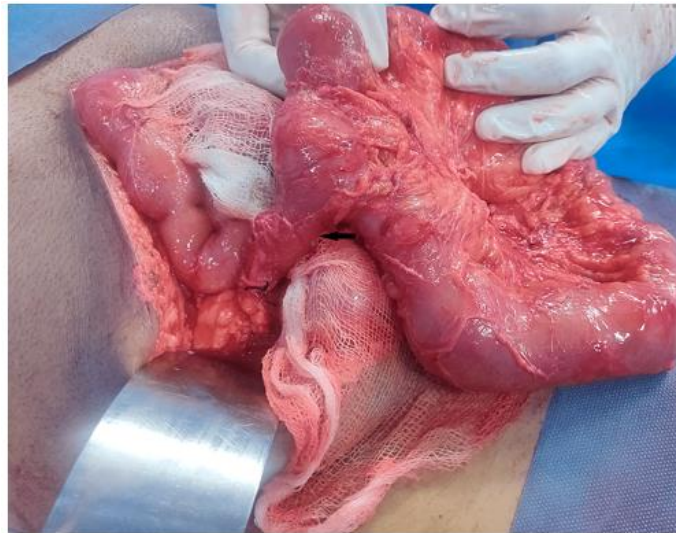


Image 7. Meckel's diverticulum- an incidental finding

3. DISCUSSION

Sclerosing Encapsulating Peritonitis, (SEP) is a rare entity described in literature as a cause of small bowel obstruction. This is also known as cocoon abdomen and the main pathology seems to be a thick fibro-collagenous membrane encapsulating the small bowel which may be clattered and crowded and aggregated to various degrees [1].

SEP could be either idiopathic or secondary to peritoneal irritation especially due to peritoneal dialysis, tuberculosis, peritoneal shunts, Mediterranean familial fever - recurrent polyserositis etc. Primary and secondary could be further differentiated on-table with lack of inter-bowel adhesions in primary SEP.

Preoperative diagnosis requires a high degree of suspicion. This is particularly important in Southeast Asia where tubercular abdomen may present with similar findings and could be treated with anti-tubercular treatment (ATT) at earliest, given high risks of fistula formation with operative management in such patients [2]. Contrast Enhanced CT can show thick covering over the bowels and clumping of bowel loops and other sequela of obstruction.

SEP clinical entity was first defined in 1907 by Owtschinnikow. He described encasement of the intestines by a fibro-collagenous membrane and used the term "*peritonitis chronica fibrosa incapsulata*" [3]. SEP is differentiated from congenital peritoneal encapsulation (CPE) which

has been described first by Cleland in 1868 as a developmental anomaly characterised by an accessory thin peritoneal membrane covered by mesothelium more like duplication of peritoneum [4]. CPE is unrelated to inflammatory processes as there is absence of sclerosis and SEP typically does not have mesothelium lining [5]. Foo et al described a similar presentation in young adolescent girls in 1978 and name it abdominal cocoon syndrome with a membrane covering the small bowel leading to obstruction and on incising the membrane the small bowel unravelled itself with intact serosa [6].

In SEP, a thick fibro-collagenous membrane is seen to encapsulate the small bowel which may be clattered and crowded to various levels and may also include other organs like stomach liver or colon. On this basis it has further been divided into Type 1: when only parts of small bowel is engulfed by the membrane, Type 2: when all of the bowel is covered and Type 3: when other organs are also so covered [7].

The main stay of surgical treatment in acute abdomen in SEP is excision of the membrane adhesiolysis and sometimes prophylactic appendectomy has been done in an attempt to prevent future exploration into a hostile abdomen [8]. Anastomosis should be avoided given high chances of leaks but may sometimes be necessary if diversion is not possible [9].

A review of literature by Sami Akbulut included 184 patients over twenty-three countries, with

overwhelming majority of the patients being treated surgically, few with tubercular concerns were treated with ATT and minority with immunosuppressants. The four countries with the most of published articles and reported patients were China, India, Türkiye, and Nigeria [10].

SEP in TB endemic regions is often misdiagnosed as abdominal TB and ATT is started empirically which should be avoided given the inappropriate treatment, antimicrobial resistance, side-effects and economic burden of the prolonged course [11].

4. CONCLUSIONS

In conclusion SEP remains a rare cause of SBO and is poorly understood and often misdiagnosed. Our aim is to spread raise the awareness about this entity and especially highlight the difference between primary and secondary types of SEP and the impact it has on the management of these distinct types. In tuberculosis endemic regions SEP can often be confused with abdominal TB and inaccurately treated with ATT. The cause of Primary SEP remains unknown and further research is needed in this direction.

The CARE checklist was followed when authoring the report [12].

DISCLAIMER (ARTIFICIAL INTELLIGENCE)

Author(s) hereby declares that NO generative AI technologies such as Large Language Models (ChatGPT, COPILOT, etc) and text-to-image generators have been used during writing or editing of manuscripts.

ETHICAL APPROVAL

As per international standards or university standards written ethical approval has been collected and preserved by the author(s).

CONSENT

As per international standards or university standards, patient(s) written consent has been collected and preserved by the author(s).

COMPETING INTERESTS

Authors have declared that no competing interests exist.

REFERENCES

1. Alzarooni HA, Ribeiro Junior MAF, Iddris SA, Alhammadi HB, DeSoucy ES, Alsayari AA: Sclerosing encapsulating peritonitis: A rare cause of small bowel obstruction. *Int J Surg Case Rep.* 2023;112:108959. DOI:10.1016/j.ijscr.2023.108959
2. Weledji EP, Pokam BT: Abdominal tuberculosis: Is there a role for surgery?. *World J Gastrointest Surg.* 2017;9:174. DOI:10.4240/wjgs.v9.i8.174
3. Pj Owtschinnikow: Peritonitis chronica fibrosa incapsulata. *Arch Klin Chir.* 1907; 83:623-34.
4. Cleland: On an Abnormal Arrangement of the Peritoneum, with Remarks on the Development of the Mesocolon. *J Anat Physiol.* 1868;201-6.
5. Allam H, Al Yahri O, Mathew S, et al.: The enigma of primary and secondary encapsulating peritoneal sclerosis. *BMC Surg.* 2016;16:81. DOI:10.1186/s12893-016-0198-2
6. Foo KT, Ng KC, Rauff A, Foong WC, Sinniah R: Unusual small intestinal obstruction in adolescent girls: The abdominal cocoon. *BJS Br J Surg.* 1978; 65:427-30. DOI:10.1002/bjs.1800650617
7. Wei B, Wei H-B, Guo W-P, Zheng Z-H, Huang Y, Hu B-G, Huang J-L: Diagnosis and treatment of abdominal cocoon: a report of 24 cases. *Am J Surg.* 2009;198: 348-53. DOI:10.1016/j.amjsurg.2008.07.054
8. Zhang Y, Liu W-D, He J-T, Liu Q, Zhai D-G: A Rare Case of Abdominal Cocoon Presenting as Umbilical Hernia. *Chin Med J (Engl).* 2015;128:1415. DOI:10.4103/0366-6999.156815
9. Li N, Zhu W, Li Y, et al.: Surgical Treatment and Perioperative Management of Idiopathic Abdominal Cocoon: Single-Center Review of 65 Cases. *World J Surg.* 2014;38:1. DOI:10.1007/s00268-014-2458-6
10. Akbulut S: Accurate definition and management of idiopathic sclerosing encapsulating peritonitis. *World J Gastroenterol.* 2015;21:675-87. DOI:10.3748/wjg.v21.i2.675
11. Anand U, Kumar R, Priyadarshi RN, Kumar B: Primary encapsulating peritoneal sclerosis in a tuberculosis-endemic region. *Journal of Gastroenterology and Hepatology.* 2019;3:349-52.

- DOI:10.1002/jgh3.12161
12. Gagnier JJ, Kienle G, Altman DG, Moher D, Sox H, Riley DS, CARE Group. The CARE Guidelines: Consensus-based Clinical Case Reporting Guideline Development; 2013. DOI:10.7453/gahmj.2013.008

Disclaimer/Publisher's Note: The statements, opinions and data contained in all publications are solely those of the individual author(s) and contributor(s) and not of the publisher and/or the editor(s). This publisher and/or the editor(s) disclaim responsibility for any injury to people or property resulting from any ideas, methods, instructions or products referred to in the content.

© Copyright (2024): Author(s). The licensee is the journal publisher. This is an Open Access article distributed under the terms of the Creative Commons Attribution License (<http://creativecommons.org/licenses/by/4.0>), which permits unrestricted use, distribution, and reproduction in any medium, provided the original work is properly cited.

Peer-review history:

The peer review history for this paper can be accessed here:

<https://www.sdiarticle5.com/review-history/121031>