



Using 3D Printing for Pre-planning of Orthopedic Surgeries, a Review

**Hamidreza Mosleh^{1#}, Shahab Aldin Nazari^{2#}, Mehdi Mehdizadeh¹,
Fatemeh Moradi¹, Hoda Mosleh³, Ronak Shabani^{1*}
and Mohammadreza Miniator Sajjadi^{4*}**

¹Department of Anatomy, Faculty of Medicine, Iran University of Medical Sciences, Tehran, Iran.

²Department of Oral and Maxillofacial Radiology, Faculty of Dentistry, Shahid Sadoughi University of Medical Sciences, Yazd, Iran.

³Faculty of Biomedical Engineering, Amirkabir University of Technology, Tehran, Iran.

⁴Department of Orthopedic Surgery, Taleghani Hospital, Shahid Beheshti University of Medical Sciences, Tehran, Iran.

Authors' contributions

This work was carried out in collaboration among all authors. Authors RS and MMS designed the study. Authors Hamidreza Mosleh and SAN wrote the protocol, wrote the first draft of the manuscript and managed the analyses of the study. Authors Hoda Mosleh, FM and MM managed the literature searches. All authors read and approved the final manuscript.

Article Information

DOI: 10.9734/JPRI/2021/v33i231147

Editor(s):

(1) Dr. Vasudevan Mani, Qassim University, Kingdom of Saudi Arabia.

(2) Dr. Mohamed Fathy, Assiut University, Egypt.

Reviewers:

(1) Sunny, Chi Lik Au, Tung Wah Eastern Hospital, Hong Kong.

(2) Zornitsa Spasova- Mitkova, Medical University-Sofia, Bulgaria.

Complete Peer review History: <http://www.sdiarticle4.com/review-history/65686>

Review Article

Received 02 December 2020

Accepted 09 February 2021

Published 18 February 2021

ABSTRACT

Background: Recent developments in 3D printing have gave orthopedic surgeons among a novel technology that has the ability to revolutionize preoperative planning. The appearance of 3D printing technology (3DPT) enables the digital preoperative plan & simulation to move from the virtual phase to the reality phase. Numerous fields of medicine are lately benefiting from the operate of 3D printing, including the arising part of 3D printing in orthopedic surgery.

Methods: We searched on PubMed and Google Scholar databases in January 2020 to find papers and studies about using 3D printing in orthopedy for aim of preplanning. The key words for search

*Corresponding author: E-mail: shabani.r@iums.ac.ir, Arashsajadi55@yahoo.com;

#Contributed equally to this study.

were (“3D printing” OR “3D-printed Model” OR “three-dimensional Printer”) AND (“Orthopedy” OR “Orthopedics” OR “Orthopedics”) AND (“Surgery” OR “Operation”) AND (“Pre-planning” OR “Plan”) AND (“Fracture” OR “Trauma”) that we used compound. We exclude the papers which their titles or abstracts were not relevant. At last, we select the most related papers to use in this article.

Results: The search on PubMed found 80 Papers and on Google Scholar found 104 papers. After excluding similar and unrelated papers, 44 papers were selected for this review article.

Conclusion: Almost all studies have shown us that using a 3D model can have a very positive effect on the surgical process and its outcomes, as well as patient and surgeon satisfaction. Therefore, we anticipate that this technology will be used in many orthopedic surgeries in the near future.

Keywords: 3D printing; orthopedic; pre-planning; surgery.

1. INTRODUCTION

Three-dimensional (3D) printing appearing in numerous subjects of medicine is appear as a clinically suggesting technology aimed at rapid prototyping of reachable creations. Recent developments in 3D printing have gave orthopedic surgeons among a novel technology that has the ability to revolutionize preoperative planning, surgical tool development, and custom orthopedic implant formation [1]. Orthopedics move into the digital era with the rapid improves of digital technology [2]. The appearance of 3D printing technology (3DPT) enables the digital preoperative plan & simulation to move from the virtual phase to the reality phase. 3D digital images promote to shape a 3D significant target. This will gives a valuable actual indication for surgeons to achieve the diagnosis and the separate operation plan, which considerably corrects the safety & effectiveness of surgery [3]. This technology creates use of data from resource such as Magnetic Resonance Imaging (MRI), Computed Tomography (CT Scan), Computer Aided Designs (CAD), Cone Beam Computed Tomography (CBCT) or from any Reverse Engineering Techniques (RET) [4]. Usual presurgical planning is based on the running of two-dimensional data obtained by incomes of traditional radiography & photography. This method limits the extensive understanding of different bony structure movements and this needs surgeon’s very well visualization abilities [5,6]. Several present surgical processes are difficult and need help to obtain a satisfactory esthetic outcome, or to prevent damaging important structure of the body [6]. An amount of examines report better outcomes for patients with orthopedic deformities by using patient-specific 3D printed models for surgical planning [7]. Several clinical centers have yet to adopt the technology as part of usual clinical treatment, despite the presence of 3D

printing in medicine for many years, not merely due to high prices and problems with segmentation—which are commonly understood as the bottleneck of the procedure [8]. The medical images integration, usually benefit for patient diagnoses, with the newest 3D printing technology predict to be very useful for therapeutic and diagnostic reasons. Numerous fields of medicine are lately benefiting from the operate of 3D printing, including the arising part of 3D printing in orthopedic surgery [9].

2. METHODS

We searched on PubMed and Google Scholar databases in January 2020 to find papers and studies about using 3D printing in orthopedy for aim of preplanning. There were 4 different researchers involved in the selection process, and they were independently judging the included studies. The key words for search were (“3D printing” OR “3D-printed Model” OR “three-dimensional Printer”) AND (“Orthopedy” OR “Orthopedics” OR “Orthopedics”) AND (“Surgery” OR “Operation”) AND (“Pre-planning” OR “Plan”) AND (“Fracture” OR “Trauma”) that we used compound.

We exclude the papers which their titles or abstracts were not relevant, language problems, hadn’t novelty or be similar to other studies, and not be suitable for our article. At last, we select the most related papers to use in this article. However, there was no limits on the time, but we did our best to choose most new and novel studies.

3. RESULTS

The search on PubMed found 80 Papers and on Google Scholar found 104 papers. After excluding similar and unrelated papers, 44 papers were selected for this review article.

4. DISCUSSION

4.1 About 3D Printing

Additive manufacturing technique, also known, as 3D printing method, is a procedure that from 3D digital or other electronic data resource, creation 3D printed things. It was firstly used for printing objects in industry, and next presented into medicine [10]. 3D printers by using computer software to build substantial items from data, shape custom-formed targets. Technological improvements in the last decade, less the price of 3D printers, such that their usage has expanded into fields not traditionally mixed with rapid prototyping [1]. The three-dimensional printing technology primary medical used in 1990 was explained by Mankovich et al. In orthopedic surgery, two mainly kinds of techniques used for 3D printing, namely additive techniques & subtractive. The subtractive method is milling for medical application, in which from a block of polyurethane or other foam the physical model will be milled. The advantage of this method is low material price. However, the geometric accuracy is weak and cannot be sterilized for intraoperative use. Other techniques normally used in orthopedic surgery are Additive techniques, in which the models create during layer by layer with liquid- like or powder-like plastic or metal material. Compared with subtractive method, additive techniques can create difficult cavities & structures. In orthopedics, generally additive technologies are selective laser sintering (SLS), stereolithography and fused deposition modelling (FDM). SLS uses high-power laser to combine little powders made of metal, plastic, glass or ceramic into a physical model based on the 3D images made by computer-aided plan. It is able to deliver a more accurate geometry. However, the cost of SLS is high and cannot be employed in operation. Stereolithography uses an optical light energy source to scan above a vat of light-curable resin, solidifying specific parts on the liquid surface. The ground of the liquid case gradually decreases, which rises the material's depth as the model increases and successive layers of resin are cured on top of each other. FDM mechanism is extraction and solidification of materials in layers. Layers achieve by a heated polymer deposition with operate of a computer-controlled extrusion nozzle. In this technique, can choose various colors and materials. The geometric accuracy is elevated and can be used in operation. But, the quality of surface is not good enough and the production time is long

[11]. Costs are different for these models of printers, in ranging of less than \$1000 to more than \$100,000. 3D printers are becoming more available and less expensive [1].

4.2 Process of 3D Printing

Image acquisition is the primary and most important stage. The quality of models depends on the quality of data establishes and the later processing; so, for making a high-quality 3D model, the quality of source images is very important. Presently, image data that use for 3D printing are obtained from MRI, CT or other imaging modalities. In the CT scan, bony tissues have a relatively higher contrast and exposure than that of soft tissue, then in orthopedic surgery CT images are commonly the sources of image for 3D printing [11]. CT image files change to stereolithography (STL) 3D printable format by segmentation and smoothing procedure. Digital Imaging and Communication in Medicine (DICOM) image tons process by MIMICS (Materialise, Leuven, Belgium) and then export as 3D-printable STL files for each patient's CT scan. For noise speckles, the STL files checking by MeshLab (Visual Computing Lab, ISTI-CNR), which will remove noises. Using the automatic mesh repair function by NetFabb (NetFabb GmbH, Lupburg, Germany), STL files adjust for 3D printing. Then the modified STL file transfer to the 3D printer [7]. 3D printing materials that use in orthopedics are poly lactic acid (PLA), stainless steel, sintered powdered metal, titanium, ceramic, nitinol, bone-like (e.g., CT-bone [xilloc, geleen, the netherlands]), plastics (e.g., polyjet [stratasys, eden prairie, minnesota], polyether ketone ketone, polyether ether ketone) [5,12].

4.3 Uses of 3D Printing in Specific Anatomical Areas of Orthopedic Surgery

4.3.1 Upper limb

4.3.1.1 Clavicle

Hyong Nyun Kim et al. in 2015 for minimally invasive plating of comminuted mid-shaft clavicle fractures used an actual size 3D printed model as a preoperative & intraoperative device. Surgeon can observe and influence exact anatomical duplications of the fractured bone by the 3D printed model. The 3D model can be used as a pattern to choose the anatomically locking plate which finest matches the model. Exclusive

of uncovering the fracture spot, the plate can add in a small incision and fixed with locking screws. 7 clavicle fractures treated with this procedure reached suitable bone union [13].

4.3.1.2 Shoulder joint

- i. Belien et al. in 2017 used a 3D model for acromion fractures. Firstly, a 3D acromial model was made and after that a fitting distal clavicular reconstruction plate for the anatomical curvatures and shape of the acromion was prevent. The surgeon had advanced practice for the surgery, which reduced the operation time. The model could also be useful to describe the patient and the operating team about surgery planning [14].
- ii. Ji Wan Kim et al. in 2018 evaluated 3D printing methods in orthopaedic trauma (clavicular shaft fractures and acetabular fractures). Acetabular 3D models could decrease operative time and bettered understanding of difficult acetabular anatomy and fracture shape to strategy the best locating of a reduction clamp and the trajectory of screws. They moreover noted simulated as a reference through the real operation. A resident did this surgical simulation and aided as a useful training technique. They recognized the ideal position of anatomical plates using 3D printed clavicle models for fractures of the clavicle [9].

4.3.1.3 Humerus

- i. Zhang et al. in 2011 treated patients with cubitus varus disorders. Osteotomy models best matching the angle and range of osteotomy were manufactured from the 3D model, by rapid prototyping and were used for managing the corrective surgery. Correction was established by postoperative radiographs. Average postoperative carrying angle in eighteen cases with cubitus varus disorder was 7.3 degree (range, 5 -11 degree), with an average correction of 21.9 degree (range, 12 – 41 degree) at twelve to twenty-four months' follow-up [15].
- ii. W. You et al. in 2016 used 3D printing tools for curing of complex proximal humeral fractures in old patients. In the test group, 3D printer was used to build the 3D facture model. This assisted to confirm the diagnosis, plan the individual operation, simulate the surgical processes and do the surgery as plan. According to the follow-up ranging from twelve to twenty-eight months for the sixty-six patients, the results displayed no significant difference in time to union between the two groups. Although, compared with the control group fewer surgery time, less blood loss through surgery, fewer number of fluoroscopies can be observed [2].

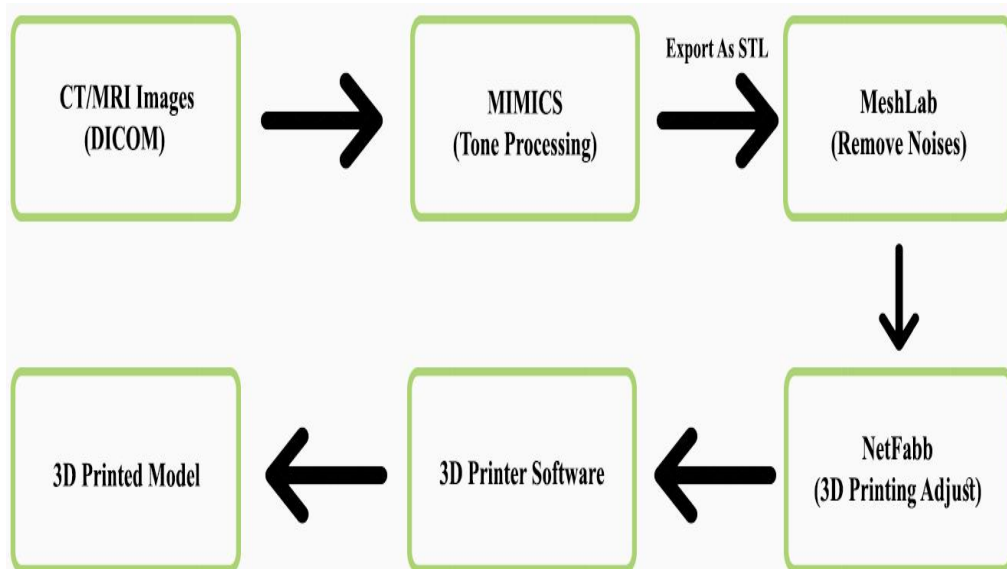


Fig. 1. Process of printing 3D model

4.3.1.4 Radius

- i. Chunhui Chen et al. in 2017 evaluated the effectiveness of applying 3D printing technology for preoperative planning for die-punch fractures. The complex fractures treatment by usage the 3D printing method decreased the operative duration, blood loss capacity and rate of intraoperative fluoroscopy, but did not increase postoperative function compared with usual treatment. The patients asked the surgeon to explain the condition and present the operative plan by 3D model because it helped their understanding. The orthopaedic surgeons believed that the 3D models were less satisfied with its usage in preoperative planning but was helpful for contact with patients [16].
- ii. Again, in 2019 Chunhui Chen et al. used 3D printing models to restructure the distal radius fractures in patients; Their results were exactly similar to 2017-study [17].

4.3.2 Lower limb

4.3.2.1 Hip joint

Hip Arthroplasty is a common and important orthopaedic surgery. There are some interesting studies that use 3D printing for preplanning of this operation, which you can see in Table 1.

4.3.2.2 Pelvis

- i. Hurson et al. in 2007 reported 12 acetabular fracture patients planned and categorized by 3D printing before surgery and verified that these models noticeably helped surgeons in understanding the specific fracture anatomy, more so for in-expert surgeons [21].
- ii. Cai et al. in 2018 utilized 3D printing technology for minimally invasive cannulated screw fixation of unstable pelvic fractures. Surgery time and average number of fluoroscopies were significantly more in the control group. Reduction in the 3D printing group was recorded excellent in 32.3 percent and good in 46.2 percent,

whereas in the control group 30.6 percent recorded excellent and 50 percent good on Matta radiological scoring systems. Overall, between the two groups no significant difference in function consequences was there [22].

- iii. Henrik Hedelin et al. in 2019 for pelvic triple osteotomy used a 3D printed model as a preoperative device. CT scans images of pre & post-operative were printed as 3D models. The models were extremely fine because of strong linear relationship between the original images and model both preoperatively and postoperatively was discovered. The study explains the effectiveness of 3D printed models in clinical exercise. Furthermore, they report a robust and easy plan by using usual clinical tools, to judge the reliability of 3D printed models [23].

4.3.2.3 Femur

- i. L. Cherkasskiy et al. in 2017 for three-plane proximal femoral osteotomy (TPFO) in slipped capital femoral epiphysis (SCFE) used patient-specific 3D models as assistance planning. TPFO cause to better hip mechanism. Post-operative radiographic parameters were similarly enhanced in all patients. Averagly, surgical duration reduced by forty-five minutes, and fluoroscopy time reduced by fifty percent in the model group compared with the no-model group. These models can be particularly beneficial to affect steep learning curves for difficult processes or in trainee education during mock surgical techniques [7].
- ii. Onder Kalenderer et al. in 2019 used 3D printing model in two cases (Legg calve perthes and developmental hip dysplasia) for preoperative planning for reduction osteotomy of femoral head: Planning of osteotomy to reach spherical head is the important point of surgery. It is typically done intra-operatively and dependent on surgeon's experience. Preoperative 3D printed model of femoral head is frequently desired to make this risk minimize. None of the cases in this study had post-operative complications or avascular necrosis [24].

Table 1. 3D printing in hip arthroplasty

Authors	Year	Summary	Results
A. Hughes et al.	2017	Acetabular Reconstruction in complex revision hip arthroplasty by using 3D printing technique. Before being adjusted, acetabular cup, buttress, augment and cage sizes were examine using the 3D-models, and improving the preoperative decision-making procedure. For decreasing the damage of neurovascular injury, screw trajectory simulation was done.	Complex pelvic deformities were improved estimated and cured with better precision by 3D printing technique. Actual-size models helped to precise operation simulation, so making better preoperative planning and anatomical appreciation. The precision and price-effectiveness of the method should verify invaluable as a device to aid clinical exercise [18].
SH. WANG et al.	2017	Using 3D printing technology in total hip arthroplasty (THA) in 74 patients. Followed-up was about 24 months.	Harris scores and time of postoperative weight bearing of the cases in the 3D printing group were better than conventional group. The postoperative infection and loosening degrees were upper in the 3D printing group. They recommend that the 3D printing method provides a better short-term healing effect and improve the lives of many patients [19].
G.Kavalerskiy et al.	2018	Using 3D models in planning of revision hip arthroplasty with complex acetabular defects. in several patients, CT scans cannot provide a perfect understanding of the pelvic destruction.	3D models created by CT data can assist surgeon in planning of complex acetabular reconstruction. 3D plaster models in this study detected high accuracy in the perfect understanding of acetabular bone deficiency [20].

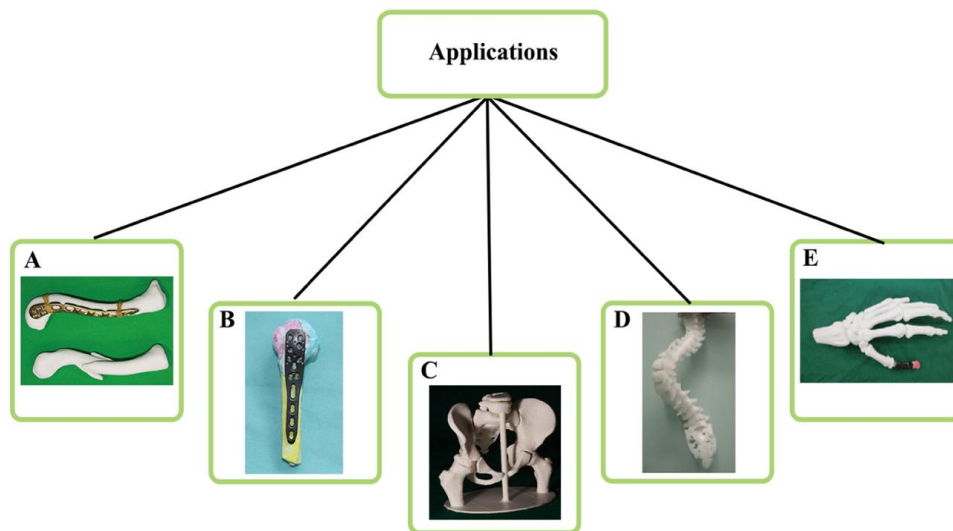


Fig. 2. 3D-printed models are very useful in orthopedy. Surgeons use these models for pre-planning of clavicle [13], humerus [2], pelvic [23], spine [35] and hand [31] surgeries

4.3.2.4 Tibia

i. Yiting Lou et al. in 2017 compared routine surgery and surgery assisted by 3D printing for tibial plateau fractures. The average operation during, blood loss, and fluoroscopy for 3D model group was

85.2±0.9 minutes, 186.3± 5.5ml, 5.3± 0.2 times, and for routine group was 99.2±1.0 minutes, 216.2 ±6.9 ml, 7.1 ± 0.2 times respectively. Statistically significant difference was found. After follow up they saw that the 3D printing group has a better clinical efficacy and it was great for

- communication between doctors and patients [25].
- ii. Giannetti et al. in 2017 compared the results after minimally invasive reduction and internal fixation with and without 3D printed model for displaced tibial plateau fractures cases. Significant reduction in duration of surgery, blood loss and radiation exposure were detected in 3D printing group. No complications with functional developed were equivalent [26].
 - iii. Wenhao Zheng et al. 2018 assessed the feasibility of 3D printing technology in the treatment of Pilon fractures. 3D printing group presented significantly smaller duration of operating, less patient's blood loss and fluoroscopy times, upper rate of anatomic fall and rate of excellent and good result than conventional group. Though, no significant difference was detected in complications between the 2 groups. Also, the questionnaire recommended that with 3D printing models usage both surgeons and patients got high scores of total satisfaction [27].
 - iv. Hwa Jun Kang et al. in 2019 determine if 3D model can change surgeon's choice of plate for distal tibia fracture surgery. A 3D printed real-size model frequently improved surgeon's preoperative choice of locking plates; especially once inexperienced surgeons estimated a compound fracture. In this study overall 102 orthopaedic surgeons were entered. 86% of inexperienced surgeons required to use 3D models for complicated fractures. But just eighteen percent of expert surgeons required to use 3D printed models for simple fractures [28].

4.3.2.5 Foot

- i. Chung et al. in 2014 using mirror imaging from the opposite side to make models of calcaneal fractures and complete ipsilateral calcaneum by 3D printing. Furthermore, they created preshaped calcaneal plates and applied these for percutaneous fixation of calcaneal fractures [29].
- ii. Wu et al. in 2017 investigated 3D printing technology for realizing ideal posterior screw location and safe regions geometry for screw fixation of talar neck. Screw trajectories and lengths at nine spots which did not breach the cortex were assessed. Furthermore, measured anteversion angle-parallel to the sagittal plane and horizontal

angle-perpendicular to the sagittal plane, and nearest & farthest spots of the safe region to the subtalar joint. The safe region was detected. The safe region of posterior screw fixation was defined, assuming fractures to be reduced. It has benefit for increase stability, decrease the surgical during and complications [30].

- iii. Zang et al. in 2017 used 3D printing to plan thumb reconstructions with second toe transfer. Models of the first toe and the second toe were prepared for understanding the donor position dimensions and moreover for fixing the donor position defect by planning best match iliac bone and superficial circumflex iliac artery flaps. All reconstructed thumbs were fine, but partial flap necrosis occurred in one patient, which was managed on bandages. Reconstructed thumbs had total great appearance and functionality [31].

4.3.3 Spine

- i. Ralph J. Mobbs et al. in 2017 evaluated the utility of 3D models for complex spinal pathologies. The authors presented two patients in which 3D printing technology was used for surgical planning as a preoperative template, and for a specific-designed titanium prosthesis: one patient with a C1/C2 chordoma who experienced tumor resection and vertebral reconstruction, and second patient with a specific-designed titanium anterior fusion cage for an uncommon congenital spinal deformity. In both reported cases, the specific-designed and specific-built implants were simply positioned, which eased the surgery and reduced the operation time, avoiding additional complex reconstruction. Radiological follow-up for both patients established successful fusion at nine and twelve months, respectively [32].
- ii. Po-Chen Chen et al. in 2019 used 3D printing technique to assist spinal deformity surgery. The engineers created drill patterns based on the bony surface anatomy and the trajectory of pedicle screws. During a preoperative mock surgery on 3D spine model, their safety and efficiency were estimated. Intraoperative monitoring no significant difference in neurologic deficit or Somatosensory evoke potential (SSEP) and motor evoke potential (MEP) was

- noticed. According to postoperative CT scans, the satisfactory rate was 97.1 percent [33].
- iii. Wongthawat Liawrungrueang et al. in 2020 used a 3D model for a patient of thoracolumbar junction pure bilateral facet joint dislocation without facet fracture, that is a very rare injury. They did an early examination using a 3D printed model so as to help with orthopaedic surgical planning, emergency initial open reduction and instrumentation with fusion. Neurological status was healthier. The 3D model should be a normal examination in rare cases of orthopaedic surgical planning [34].

5. CONCLUSION

In this article, we reviewed studies conducted around the world on orthopedic surgery pre-planning using a 3D printed model, and tried to further present new and innovative articles.

Almost all studies have shown us that using a 3D model can have a very positive effect on the surgical process and its outcomes, as well as patient and surgeon satisfaction. The advantages of this technology, which have been repeatedly mentioned in previous studies are reduced surgical time and number of fluoroscopies during surgery, and reduced patient bleeding and postoperative complications. Probably all this is due to the fact that there is a model before surgery that completely similar to the patient's anatomy, which makes the surgeon more ready and with better planning for the surgery, or even before the surgery can practice on the model.

Therefore, we anticipate that this technology will be used in many orthopedic surgeries in the near future.

6. LIMITATION

There were some limitations in writing this review article. One of them was language problem, especially articles in Chinese that we couldn't use them. Another was the studies which hadn't got obvious results.

7. SUGGESTION

Due to the benefits of using a printed 3D model as a tool for preoperative planning, as evidenced by previous studies and research, there are still many orthopedic surgeries that do not use this useful tool.

Therefore, we suggest using 3D models for more orthopedic surgeries (For example in Tibial deformity, Knee Arthroplasty, Genuvarum or Genuvalgum, and etc) and reporting their results.

CONSENT

It's not applicable.

ETHICAL APPROVAL

It's not applicable.

COMPETING INTERESTS

Authors have declared that no competing interests exist.

REFERENCES

1. Eitorai AEM, Nguyen E, Daniels AH. Three-dimensional printing in orthopedic surgery. *Orthopedics*. 2015;38(11): 684–7.
2. You W, Liu LJ, Chen HX, Xiong JY, Wang DM, Huang JH et al. Application of 3D printing technology on the treatment of complex proximal humeral fractures (Neer 3-part and 4-part) in old people. *Orthop Traumatol Surg Res*. 2016;102(7): 897–903.
3. Sutradhar A, Park J, Carrau D, Miller MJ. Experimental validation of 3D printed patient-specific implants using digital image correlation and finite element analysis. *Comput Biol Med*. 2014;52: 8–17.
4. Huotilainen E, Paloheimo M, Salmi M, Paloheimo K-S, Björkstrand R, Tuomi J et al. Imaging requirements for medical applications of additive manufacturing. *Acta Radiol*. 2014;55(1):78–85.
5. Malyala SKMK. 3D printed medical model to resolve cleft alveolus defect: A case study. *KnE Eng*. 2017;8–14.
6. Tack P, Victor J, Gemmel P, Annemans L. 3D-printing techniques in a medical setting: A systematic literature review. *Biomed Eng Online*. 2016;15(1):115.
7. Cherkasskiy L, Caffrey JP, Szewczyk AF, Cory E, Bomar JD, Farnsworth CL et al. Patient-specific 3D models aid planning for triplane proximal femoral osteotomy in slipped capital femoral epiphysis. *J Child Orthop*. 2017;11(2):147–53.
8. Witowski J, Sitkowski M, Zuzak T, Coles-Black J, Chuen J, Major P, et al. From

- ideas to long-term studies: 3D printing clinical trials review. *Int J Comput Assist Radiol Surg.* 2018;13(9):1473–8.
9. Kim JW, Lee Y, Seo J, Park JH, Seo YM, Kim SS et al. Clinical experience with three-dimensional printing techniques in orthopedic trauma. *J Orthop Sci.* 2018; 23(2):383–8.
 10. Wu A-M, Lin J-L, Kwan KYH, Wang X-Y, Zhao J. 3D-printing techniques in spine surgery: The future prospects and current challenges. Taylor and Francis; 2018.
 11. Wong TM, Jin J, Lau TW, Fang C, Yan CH, Yeung K et al. The use of three-dimensional printing technology in orthopaedic surgery: A review. *J Orthop Surg.* 2017;25(1):2309499016684077.
 12. Top 10 materials for 3D printing [Internet]. American Society of Mechanical Engineers; 2015. Available: <https://www.asme.org/engineering-topics/articles/manufacturingprocessing/top-10-materials-3d-printing>
 13. Kim HN, Liu XN, Noh KC. Use of a real-size 3D-printed model as a preoperative and intraoperative tool for minimally invasive plating of comminuted midshaft clavicle fractures. *J Orthop Surg Res.* 2015;10(1):91.
 14. Beliën H, Biesmans H, Steenwerckx A, Bijmens E, Dierickx C. Prebending of osteosynthesis plate using 3D printed models to treat symptomatic os acromiale and acromial fracture. *J Exp Orthop.* 2017;4(1):1–10.
 15. Zhang YZ, Lu S, Chen B, Zhao JM, Liu R, Pei GX. Application of computer-aided design osteotomy template for treatment of cubitus varus deformity in teenagers: A pilot study. *J Shoulder Elb Surg.* 2011; 20(1):51–6.
 16. Chen C, Cai L, Zhang C, Wang J, Guo X, Zhou Y. Treatment of die-punch fractures with 3D printing technology. *J Investig Surg.* 2018;31(5):385–92.
 17. Chen C, Cai L, Zheng W, Wang J, Guo X, Chen H. The efficacy of using 3D printing models in the treatment of fractures: A randomised clinical trial. *BMC Musculoskelet Disord.* 2019;20(1):65.
 18. Hughes AJ, DeBuitelir C, Soden P, O'Donnchadha B, Tansey A, Abdulkarim A et al. 3D printing aids acetabular reconstruction in complex revision hip arthroplasty. *Adv Orthop.* 2017;2017: 8925050.
 19. Wang S, Wang L, Liu Y, Ren Y, Jiang L, Li Y et al. 3D printing technology used in severe hip deformity. *Exp Ther Med.* 2017;14(3):2595–9.
 20. Kavalerskiy GM, Murylev VY, Rukin YA, Elizarov PM, Lychagin A V, Tselisheva EY. Three-dimensional models in planning of revision hip arthroplasty with complex acetabular defects. *Indian J Orthop.* 2018;52(6):625–30.
 21. Hurson C, Tansey A, O'donnchadha B, Nicholson P, Rice J, McElwain J. Rapid prototyping in the assessment, classification and preoperative planning of acetabular fractures. *Injury.* 2007;38(10): 1158–62.
 22. Cai L, Zhang Y, Chen C, Lou Y, Guo X, Wang J. 3D printing-based minimally invasive cannulated screw treatment of unstable pelvic fracture. *J Orthop Surg Res.* 2018;13(1):71.
 23. Hedelin H, Swinkels CS, Laine T, Mack K, Lagerstrand K. Using a 3D printed model as a preoperative tool for pelvic triple osteotomy in children: Proof of concept and evaluation of geometric accuracy. *JAAOS Glob Res Rev.* 2019;3(3).
 24. Kalenderer Ö, Erkuş S, Turgut A, Inan IH. Preoperative planning of femoral head reduction osteotomy using 3D printing model: A report of two cases. *Acta Orthop Traumatol Turc.* 2019;53(3): 226–9.
 25. Lou Y, Cai L, Wang C, Tang Q, Pan T, Guo X et al. Comparison of traditional surgery and surgery assisted by three dimensional printing technology in the treatment of tibial plateau fractures. *Int Orthop.* 2017;41(9):1875–80.
 26. Giannetti S, Bizzotto N, Stancati A, Santucci A. Minimally invasive fixation in tibial plateau fractures using an pre-operative and intra-operative real size 3D printing. *Injury.* 2017;48(3):784–8.
 27. Zheng W, Chen C, Zhang C, Tao Z, Cai L. The feasibility of 3D printing technology on the treatment of pilon fracture and its effect on doctor-patient communication. *Biomed Res Int.*; 2018.
 28. Kang HJ, Kim BS, Kim SM, Kim YM, Kim HN, Park JY et al. Can Preoperative 3D printing change surgeon's operative plan for distal tibia fracture? *Biomed Res Int.*; 2019.
 29. Chung KJ, Hong DY, Kim YT, Yang I, Park YW, Kim HN. Preshaping plates for minimally invasive fixation of calcaneal

- fractures using a real-size 3D-printed model as a preoperative and intraoperative tool. *Foot Ankle Int.* 2014;35(11):1231–6.
30. Wu J, Ma S, Liu S, Qin C, Jin D, Yu B. Safe zone of posterior screw insertion for talar neck fractures on 3-Dimensional reconstruction model. *Orthop Surg.* 2017;9(1):28–33.
 31. Zang C, Zhang J, Meng Z, Liu L, Zhang W, Chen Y et al. 3D printing technology in planning thumb reconstructions with second toe transplant. *Orthop Surg.* 2017;9(2):215–20.
 32. Mobbs RJ, Coughlan M, Thompson R, Sutterlin CE, Phan K. The utility of 3D printing for surgical planning and patient-specific implant design for complex spinal pathologies: Case report. *J Neurosurg Spine.* 2017;26(4):513–8.
 33. Chen PC, Chang CC, Chen HT, Lin CY, Ho TY, Chen YJ, et al. The accuracy of 3D printing assistance in the spinal deformity surgery. *Biomed Res Int.*; 2019.
 34. Liawrungrueang W, Sornsard T, Boonchieng E. Bilateral pure facet joint dislocation in thoracolumbar junction (T11–T12) without facet fracture using a 3D digital printing model for surgical planning: A case report. *Trauma Case Reports.* 2020;25:100273.
 35. Provaggi E, Leong JJH, Kalaskar DM. Applications of 3D printing in the management of severe spinal conditions. *Proc Inst Mech Eng Part H J Eng Med.* 2017;231(6):471–86.

© 2021 Mosleh et al.; This is an Open Access article distributed under the terms of the Creative Commons Attribution License (<http://creativecommons.org/licenses/by/4.0>), which permits unrestricted use, distribution, and reproduction in any medium, provided the original work is properly cited.

Peer-review history:
The peer review history for this paper can be accessed here:
<http://www.sdiarticle4.com/review-history/65686>