



Two Cases of Ocular Trauma with Air Gun Pellets

**Nakul Verma ^{a*}, Balbir Khan ^a, Vartika Anand ^a
and Ashneet Sandhu ^a**

^a Department of Ophthalmology, Gian Sagar Medical College, Rajpura, Patiala (Punjab), India.

Authors' contributions

This work was carried out in collaboration among all authors. All authors read and approved the final manuscript.

Article Information

DOI: <https://doi.org/10.9734/or/2024/v19i3427>

Open Peer Review History:

This journal follows the Advanced Open Peer Review policy. Identity of the Reviewers, Editor(s) and additional Reviewers, peer review comments, different versions of the manuscript, comments of the editors, etc are available here: <https://www.sdiarticle5.com/review-history/117445>

Case Report

Received: 25/03/2024

Accepted: 31/05/2024

Published: 07/06/2024

ABSTRACT

Two healthy males presented on separate occasions to the emergency room after sustaining trauma by air-gun pellets during farmer's agitation against the government. Clinical examination indicated that the foreign bodies (air-gun pellets) were imbedded in different locations (subconjunctival and subcutaneous in eye lid.). The management of this traumatic injury is discussed and concurs with the published literature.

Keywords: Ocular trauma; foreign body; subconjunctival; air-gun pellet.

1. INTRODUCTION

“Ocular trauma imposes significant impact on global health. According to the World Health Organization (WHO), some 55 million eye

injuries that limit activities for more than one day occur annually. Approximately 19 million and 3.9 million people are blinded due to ocular injuries in one or both eyes, respectively” [1].

*Corresponding author: E-mail: nakulverma2971@gmail.com;

Cite as: Verma, Nakul, Balbir Khan, Vartika Anand, and Ashneet Sandhu. 2024. “Two Cases of Ocular Trauma With Air Gun Pellets”. *Ophthalmology Research: An International Journal* 19 (3):55-59. <https://doi.org/10.9734/or/2024/v19i3427>.

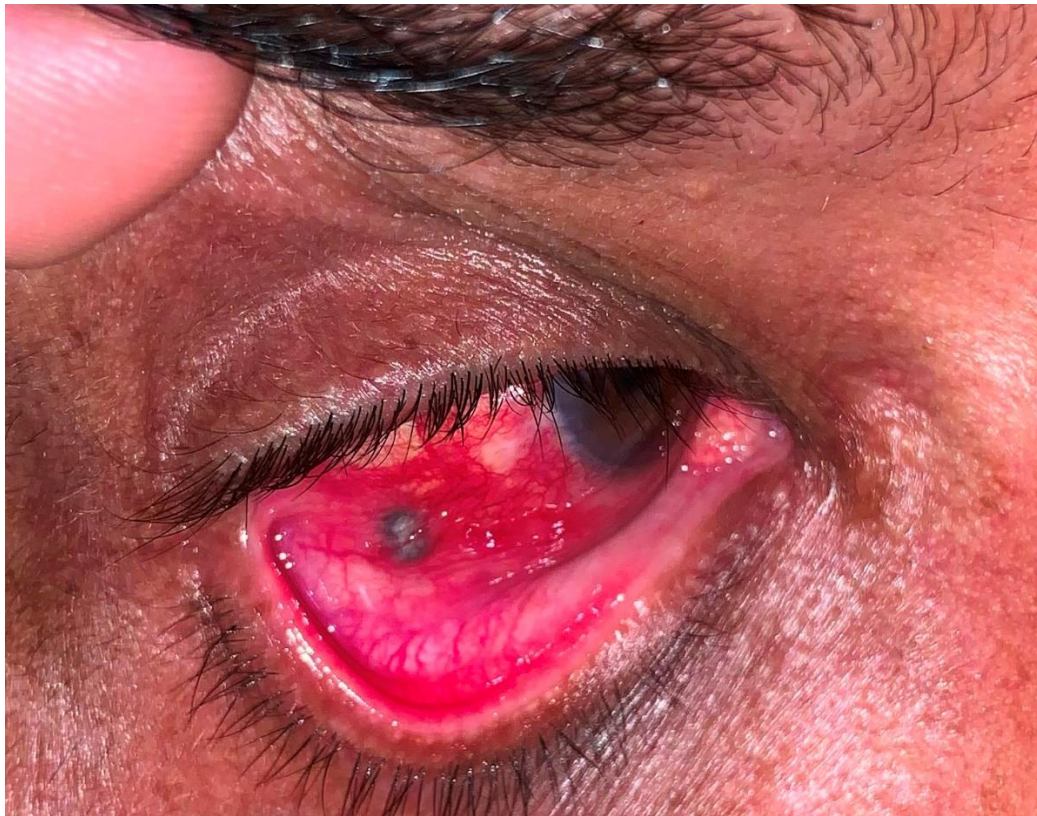“We are presenting two cases of ocular trauma with pellet guns which were used by security forces against the farmer protesters, resulting in significant ocular injuries” [1]. This case study reports the incidence, clinical findings, and management of these two patients with pellet gun-related injuries who presented in our institute.

2. CASE PRESENTATIONS

First case a 56-years male was brought to the emergency room with the history of injury in right eye one week back during farmer’s protest. He was using Carboxymethyl cellulose 0.5% eye drops prescribed by some chemist over the counter for last one week. On the day of presentation his best corrected visual acuity in the right eye was 6/12 and in the left eye was 6/6. On slit lamp examination a pellet was seen below the conjunctiva in right eye (Photograph-1) and there were 4+ cells in anterior chamber in right eye. Intraocular pressure was normal in both eyes. Dilated fundus examination was normal in both the eyes. The pellet of size 2x2mm (Photograph-2) was removed from the subconjunctival space under topical anesthesia.

Thorough exploration and irrigation of the conjunctival sac was done, subconjunctival injection of dexamethasone and gentamycin was given and pad and patch was applied. On first post op day patient was put on topical moxifloxacin 0.5% and dexamethasone 0.1%, one drop one hourly which was tapered in 2 weeks. On second week follow-up patient improved to 6/6 visual acuity in right eye and the conjunctival wound has also healed.

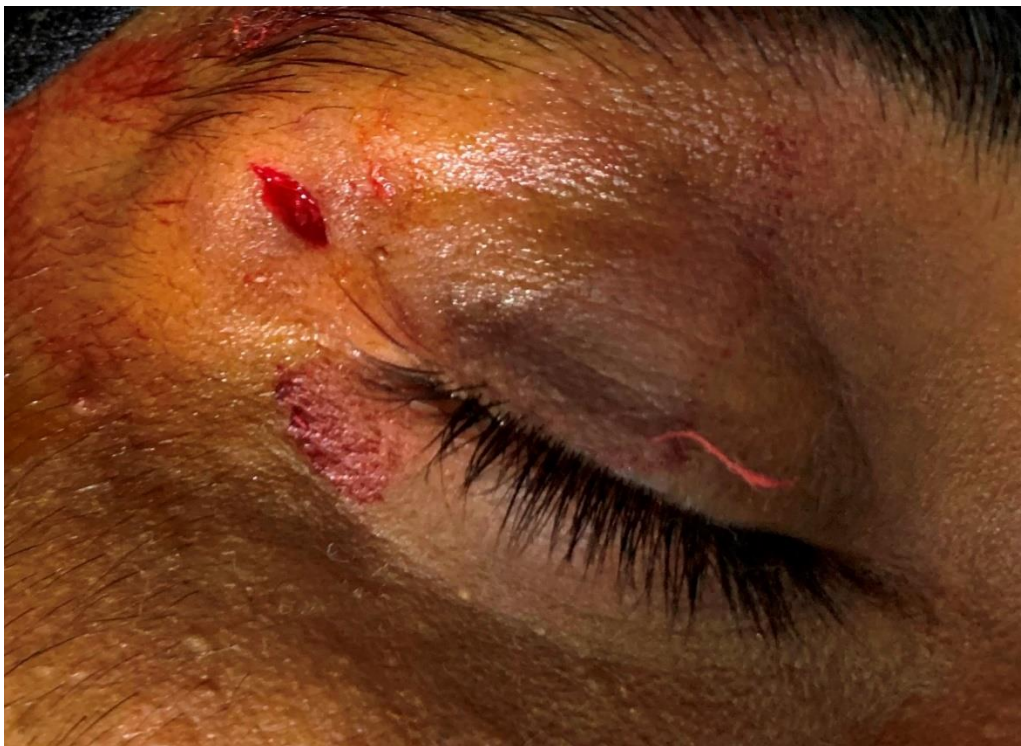Second case a 27year old male also presented to the emergency room with a history of injury with pellet in his right upper eye lid (Photograph-3) on the same day during farmer’s protest. On palpation of the lid the foreign body was suspected. The BCVA in both eyes was 6/6. There was subconjunctival hemorrhage in the right eye. Intraocular pressure was normal in both eyes. Dilated fundus examination was normal in both the eyes. X-ray of the orbit was advised. A rounded metallic foreign body of size 2x2mm was detected on the x-ray (Photograph-4). The wound was explored and the pellet was removed from the right upper eye lid. The wound was sutured with 6-0 Vicryl.



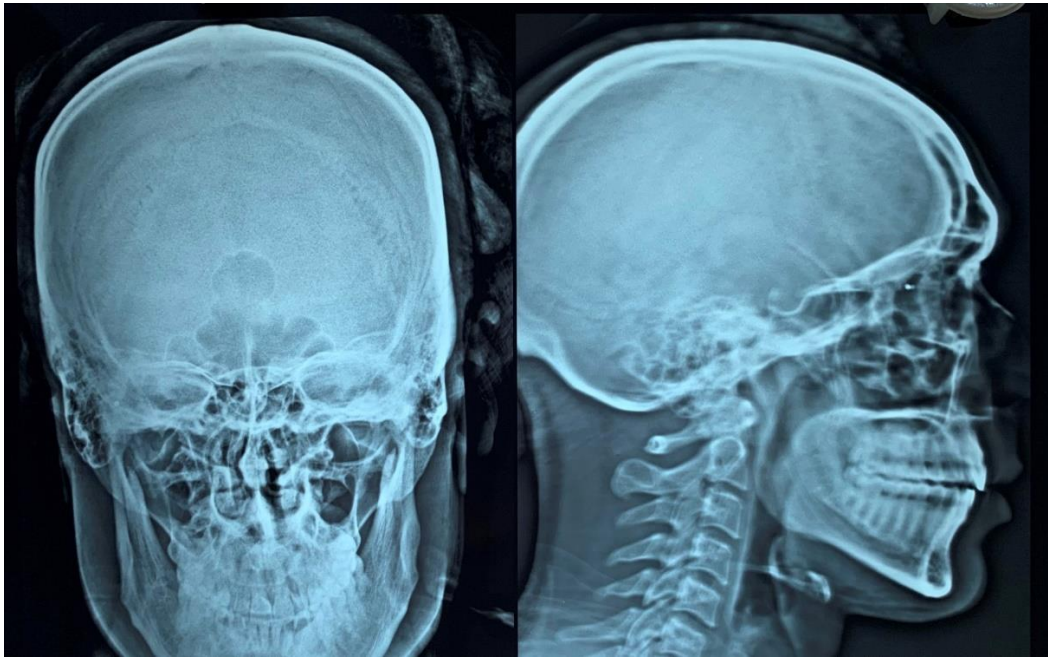
Photograph 1. Photograph showing subconjunctival gun pellet in first case



Photograph 2. Photograph showing 'gun pellet' removed in first case



Photograph 3. Photograph of second case, after removal of subcutaneous gun pellet from the right upper eyelid



Photograph 4. X-ray showing metallic rounded foreign body (gun pellet) in second case

3. DISCUSSION

Ocular injuries with various types guns e.g. pellet guns, shot guns, nerf guns, air gun etc have been reported in the literature.[1-7] The nature of ocular injury is categorized using the Birmingham Eye Trauma Terminology (BETT) system. Both cases were closed globe injuries with pellets in the subconjunctival space in right eye in the first case and subcutaneous space in the right upper eye lid in second case. These pellets when shot at close range usually causes unilateral ocular trauma while shooting at longer range causes binocular lesions. The different lesions caused by these nonmagnetic foreign bodies are often very serious [8]. These pellets are composed of 99% lead. It has also been reported that the retained pellets in the tissues may also rarely cause delayed lead toxicity [9] Sclopetaria or chorioretinitis sclopetaria was first described in the German literature in 1901. It can be caused as a concussion induced choroidal and retinal trauma from a pellet passing adjacent to but not penetrating the globe creating a shock wave causing a concussive wave, meaning scratch, pull or tear [10,11].

Wei X et. al [1] in their retrospective study reported, “a series of 777 pellet gun ocular injuries over a 4-month period in Kashmir. They observed that the majority patients were male (97.7%)”. “In terms of laterality, 94.3% and 5.7%

of the patients sustained monocular and binocular injuries, respectively. In terms of the nature of injury, 76.3% of the eyes had open globe injury while 23.7% of the eyes had closed eye injury”. [1] Long term visual out come in the presence of intraocular pellets in the eye and requiring vitreo-retinal surgery is poor [6].

4. CONCLUSION

Ocular injury with pellet guns can involve anterior and posterior segment, orbital and lid adnexa. Public education on the eye protection for civilians in regions where military and security forces are known to utilize pellet guns may be useful in reducing the incidence of such injuries.

CONSENT

As per international standards or university standards, patient(s) written consent has been collected and preserved by the author(s).

ETHICAL APPROVAL

It is not applicable.

COMPETING INTERESTS

Authors have declared that no competing interests exist.

REFERENCES

1. Wei X, Ang BC, Nazir A, Shah FQ, Qureshi T, Jain A et al. A series of 777 pellet gun ocular injuries over a 4-month period in Kashmir. *Indian J Ophthalmol* 2022;70: 3465-9.
2. Weiss R, He C, Gise R, Parsikia A, Mbekeani JN. Patterns of pediatric firearm-related ocular trauma in the United States. *JAMA Ophthalmol.* 2019;137: 1363–70.
3. Bizrah M, Verma S. Nerf gun eye injuries: traumatic hyphema *BMJ Case Rep* 2017.
4. Khoueir Z, Cherfan G, Assi A. Vitreoretinal surgery for shotgun eye injuries: outcomes and complications. *Eye*; 2015;29:881–7.
5. Tabatabaei SA, Soleimani M, Rajabi MB, Ahmadraji AA, Khodabandeh A, Beheshtnejad A et al. Pellet gun injury as a source of ocular trauma; a retrospective review of one hundred and eleven cases. *Journal of Current Ophthalmology.* 2018; 30:239-44.
6. Shuttleworth GN and Galloway PH. Ocular air-gun injury: 19 cases. *JR Soc Med.* 2001;94:396-9.
7. Blanch RJ, Bindra MS, Jacks AS, Scott RAH. Ophthalmic injuries in British Armed Forces in Iraq and Afghanistan. *Eye.* 2011; 2:218–23.
8. Assaf E, Emadisson H, Bendeddouche K, Forestier F, Bouccara AS. Pellet guns: A persistent threat to eyes. *J Fr Ophthalmol.* 2003;26: 960-6.
9. Bowen DI and Magauran DM. Ocular Injuries caused by Airgun Pellets: An Analysis of 105 Cases. *British Medical Journal.* 1973;1:333-7.
10. Al-Amry M, Al-Taweel H, Al-Enazi N, Alrobaian M and Al-Othaimeen S. Retained periorbital and intracranial air-gun pellets causing sclerokeratitis and visual loss. *Saudi Journal of Ophthalmology.* 2014;28:228-33.
11. Roden D, Cleary P, and Eustace P. A five-year survey of ocular shotgun injuries in Ireland. *British Journal of Ophthalmology.* 1987;71:449-53.

© Copyright (2024): Author(s). The licensee is the journal publisher. This is an Open Access article distributed under the terms of the Creative Commons Attribution License (<http://creativecommons.org/licenses/by/4.0>), which permits unrestricted use, distribution, and reproduction in any medium, provided the original work is properly cited.

Peer-review history:

The peer review history for this paper can be accessed here:

<https://www.sdiarticle5.com/review-history/117445>