



# Adolescent Extra-renal Wilms' Tumour: Rare Manifestation of Retroperitoneal Tumor with Hepatomegaly in District Hospital during Pandemic COVID-19 Era

Nur Bazlaah Bahari <sup>a,b\*</sup>, Aatikah Rashidah Abdul Mun'im <sup>b</sup>,  
Nurul Asyikin Yahya <sup>c</sup>, Khairuzi Salekan <sup>b</sup>,  
Nurasreen Asman Shah <sup>b</sup>, Wan Izzah Wan Jaffar <sup>a,b</sup>  
and Siti Juliana Jahidin <sup>b</sup>

<sup>a</sup> Department of General Surgery, Hospital University Kebangsaan, Malaysia.

<sup>b</sup> Department of General Surgery, Hospital Sultanah Nora Ismail, Batu Pahat, Malaysia.

<sup>c</sup> Department of Pediatric Surgery, Hospital Sultanah Aminah, Johor Bahru, Malaysia.

## **Authors' contributions**

*This work was carried out in collaboration among all authors. All authors read and approved the final manuscript.*

## **Article Information**

### **Open Peer Review History:**

This journal follows the Advanced Open Peer Review policy. Identity of the Reviewers, Editor(s) and additional Reviewers, peer review comments, different versions of the manuscript, comments of the editors, etc are available here: <https://www.sdiarticle5.com/review-history/101857>

**Case Report**

**Received: 15/04/2023**

**Accepted: 19/06/2023**

**Published: 23/06/2023**

## **ABSTRACT**

Wilms' tumour or nephroblastoma is the most common primary renal neoplasm in children, however, it is rarely documented within adolescent age group. Generally, only a few cases have been reported in adolescents even more in extrarenal presentations. This paper discusses a case

\*Corresponding author: E-mail: bazlaah90@gmail.com;

of a 15-year-old adolescent with a huge hepatomegaly. Ultrasonography finding suggested liver tumour possibly hepatoblastoma due to the age. CT scan findings on the other hand suggested retroperitoneal sarcoma. Diagnosis using CT scan for retroperitoneal tumor is often challenging but further tests such as MRI scan was limited due to restricted resources and modalities in the district hospital during covid 19 pandemic. Dilemma of establishing diagnosis through a simple procedure that only acquired expert interventional radiologist was limited due to COVID-19 pandemic. Thus, decision of open biopsy was made for the retroperitoneal mass. Consequently, a complete tumour resection was made for symptomatic relief in view of encapsulated mass noted intra-operatively and pathological staging confirmed as metastatic stage 1 extra-renal Wilms tumour. Radiological staging confirmed of stage 4 disease with lung metastasis in which required multiple course of adjuvant chemotherapy and close follow up. Reassessment CT post-chemotherapy show diseases progression with residual segment VII local liver disease and increasing number of multiple lung metastasis. Wilms' tumour is rare in adolescents, and extra-renal manifestations are even less common. It is essential for general surgeon to maintain a high index of clinical suspicion for Wilms' tumour in adolescents who present with a large retroperitoneal mass and/or abdominal pain.

**Keywords:** Adolescent wilms; tumour; extrarenal wilms; tumour during pandemic COVID-19; retroperitoneal tumour manifest as huge hepatomegaly.

## 1. INTRODUCTION

Wilms' Tumour known as Nephroblastoma, predominantly occurs in children with a peak incidence between 2 to 5 years age group. The mean age at diagnosis is 3 years old and about 80% of cases are diagnosed before the age of five [1]. In Malaysia, incidence of Wilms' Tumour is rare with less than 2.5 cases per million populations yearly. An audit by Cheah *et al.* recorded in 1992, only 37 cases over a 22-year period which translates to 1.6 cases per year in a Malaysian university hospital [2]. Latest data from National Cancer Registry Report (2012-2016), the reported occurrence of Wilms' tumor is scarce with only eight cases reported amongst males aged between 10-15 years old [3]. This data highlights the finite number of Wilms' tumour cases reported within the adolescent age group. Ultimately, Wilms' tumour rarely presented in adolescent age. Extrarenal Wilms' tumour is exceptionally rare with disputed origin and is often misdiagnosed for other common retroperitoneal masses of that region [4]. To the best of our knowledge, there is no reported case of extra-renal Wilms' tumour presented as symptomatic hepatomegaly. In this study, we will present a case of a 15-year-old boy who was initially diagnosed as symptomatic hepatomegaly and radiologically manifested as retroperitoneal tumour but final histopathology confirmed as metastatic stage 1 nephroblastoma (Wilm's tumour).

## 2. CASE REPORT

A 15 year old teenager presented to Hospital Enche' Besar Hajah Kalsom, Kluang in

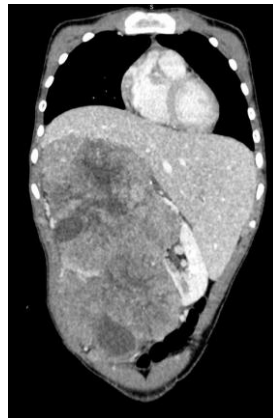November 2020 for abdominal mass with fever. He was then referred to Surgical team Hospital Sultanah Nora Ismail (HSNI) Batu Pahat for further evaluation and management in view of the Covid 19 pandemic. The patient had a 2 months' history of abdominal discomfort, and on and off constipation associated with early satiety for the past 3 weeks. During the period of 2 months he lost a few kilograms of weight. However, no hematuria was noted.

Physical examinations revealed that his abdomen was soft, non tender with palpable right hypochondriac mass exhibit as huge hepatomegaly. The spleen was not enlarged, kidneys were not ballotable and no ascites was noted. His laboratory tests including renal profile, liver profile and urine for examination and microscopic examination were unremarkable. He was seen by our physician and initial diagnosis of hepatomegaly for investigation was made. He was then arranged for abdominal ultrasound which showed heterogenous enlarged liver with predominant solid component mixed with some cystic component. Overall ultrasound findings suggested primary malignant tumour with probable diagnosis of hepatoblastoma based on his age.

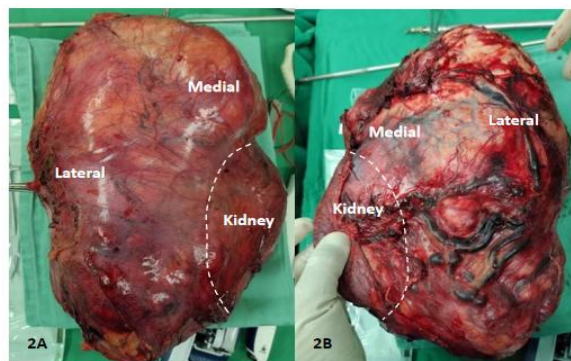
A contrast enhanced computed tomography (CECT) scan of liver 4 phase was done and heterogenous retroperitoneal mass seen at right retroperitoneal region measuring approximately 13.4 x 16.8 x 27.4 cm (AP x W x CC) with central hypodense areas, suggesting central necrosis with multiple adjacent neovascularization. The mass indenting into the inferior aspect of the right

liver lobe and the right kidney was displaced inferiomedially. Differential diagnosis of retroperitoneal sarcoma and exophytic right renal mass was concluded from the CT. However, due to limited resources during Covid 19 pandemic and unavailability of Interventional Radiologist, further biopsy of the mass was unable to proceed. Patient underwent laparotomy for excision and biopsy of the mass. Intraoperatively, the right kidney was also normal but displaced downward by a huge retroperitoneal firm encapsulated retroperitoneal mass. The retroperitoneal mass densely adhered to the right kidney. Failure to separate the mass with the right kidney led to right nephrectomy and complete tumour resection. The retroperitoneal mass was not adhered to the liver and bowel. Multiple mesenteric lymph node about 2cm largest in diameter with no obvious peritoneal seeding was discovered. Gross histopathology examination revealed encapsulated mass weighing 3550 g and measuring 27 × 19.5 × 13.5 cm. Cut surface showed variegated solid cystic

mass with area of haemorrhage and yellowish cut surface. The tumor was sharply demarcated from the renal parenchyma. Microscopically, this well-encapsulated tumour was composed of classical triphasic components: blastemal (40%), epithelial (30%) and stromal component (30%), consistent with nephroblastoma (Wilms' tumor) mixed type: Stage 1 (intermediate risk). Radiological staging confirmed of stage 4 disease with lung metastasis. Post operatively patient was then referred to Hospital Sultan Ismail, Johor Bahru for further treatment. He was under paediatric oncology care for 8 months in which he completed a total of 31 weeks chemotherapy and radiotherapy to abdomen and lungs. Reassessment CT post-chemotherapy show diseases progression with residual segment VII local liver disease and increasing number of multiple lung metastasis. Subsequently patient was referred to paediatric centre in Hospital Tunku Azizah, Kuala Lumpur (National Paediatric Center) for further expert management.



**Fig. 1. Coronal view of contrast enhanced CT abdomen showing a right retroperitoneal mass clinically manifest as huge hepatomegaly**



**Fig. 2. A. Anterior view showing encapsulated resected specimen of retroperitoneal mass. B. Posterior view of resected specimen with arrow pointing towards site of kidney at the medial margin**

### 3. DISCUSSION

Wilms' tumour or nephroblastoma is one of the most common malignant abdominal tumors of childhood, almost exclusively arising from the kidney. It is the most common primary malignant renal tumor in children and the fourth most common type of cancer in children. Based on retrospective study reported in Malaysia for 22 years period done by Cheah et al., Wilms' tumour is usually observed in children aged between 1 month to 4 years old [2]. The oldest Wilms' tumour recorded in Malaysia is an 11 year old boy presented with acute appendicitis [4]. The oldest Wilms' tumour case reported worldwide was in India, reported in August 2017, showed atypical presentation of Wilms' tumour in 28 years old lady [5].

Patients are generally asymptomatic until a large abdominal mass is detected or minimal intestinal disorders are developed. The typical clinical presentation in the pediatric population is a painful abdominal mass (50% of cases), and hypertension or hematuria (less than 30% of cases). However, bilateral renal involvement is unusual, with less than 10% of cases reported [5]. Our patient clinically manifested as symptomatic hepatomegaly in which superiorly the mass could not get above, inferiorly mass was able to get below and the mass was confined to costal margin. This presentation is uncommonly seen. Clinical manifestation of huge hepatomegaly, led to ambiguity in establishing a diagnosis.

Generally, retroperitoneal tumour is one of the spectrums of diseases that pose both diagnostic and surgical management dilemma. Most patients are asymptomatic with abdominal distension being the commonest presentation. Diagnosis is usually obtained using Ultrasonography and CT scan as it is difficult to arrive at diagnosis clinically. The imaging features of Wilms' tumour (renal or extrarenal) are non-specific and the heterogeneous appearance as described in the previous reports was also encountered in our case. Thus a diagnosis of extrarenal Wilms' tumour can be suggested on the basis of imaging findings which can only be confirmed on pathological evaluation. Hence, clinical manifestation of hepatomegaly and radiological findings suggestive of retroperitoneal sarcoma made the diagnosis uncertain.

The pandemic affects the availability of medical resources especially in district areas. Considering the need for lockdown measures, most countries, including Malaysia, have implemented 'Movement Control Orders' (MCOs) as a prevention step to reduce the deadly spread of this disease. For our case, due to unavailability of Interventional Radiologist, further biopsy of the mass was unable to proceed. The role of FNAC and Core needle biopsy remains controversial. In a recent study Chew reported that preoperative biopsy has no value in the clinical and radiological assessment of patients with resectable large retroperitoneal masses [6]. Once diagnosis is made, total tumor resection must be completed urgently.

In this patient the correct diagnosis was made on histopathology examination. The large size of the retroperitoneal mass, with displaced organs, distorted anatomy combined with the lack of prior histological knowledge proved to be challenging. Intraoperative judgement about the characteristics of the tumour, and the decision to determine the extent of resection are important considerations [7]. In case of doubt, a wide resection which should include any infiltrated contiguous structures should be done to achieve adequate margins.

In our case, macroscopically the tumor revealed encapsulated extra renal Wilms' tumor with the tumour sharply demarcated from renal parenchyma. Extra renal Wilms' tumour is uncommon, with the majority of cases occurring in the retroperitoneal as it was in our case. Wilms' tumour that is not arising from the intrarenal area but shares a common capsule with the ipsilateral kidney, is even rarer. Previous authors have created a separate diagnostic category for extrarenal Wilms tumor called "juxtarenal Wilms tumor," in which the capsule of the tumor abuts the capsule of the kidney [8]. Despite its rarity, an extrarenal or even juxtarenal/pararenal Wilms' tumour should be included in the differential diagnosis of retroperitoneal tumour.

Based on a comparative study done in the United State by Satlzman et al (2019) using data from the National Cancer Database, a global survival in five and 10 years was significantly inferior in young adults than children: 79.1% vs 93.1% ( $p < 0.001$ ), and 52% vs 91% ( $p < 0.001$ ). Respectively, the standard of treatment of pediatric Wilms' tumor usually involves

multimodal therapy; even though surgery is the cornerstone of therapy, many patients will require chemotherapy or adjuvant radiotherapy to improve the probability of response and complete remission of the disease [9]. Furthermore, extra renal tumour has a potential for local recurrences as well as distant metastases, the incidence of which is similar to classical Wilms' tumour [10].

Hence careful follow up and multidisciplinary approach of management for patients care should be done. Our patient was under the paediatric oncology care in Hospital Sultan Ismail, Johor Bahru for 8 month but subsequently developed local recurrence with metastasis that required referral to the paediatric centre at Hospital Tunku Azizah, Kuala Lumpur for further management.

#### 4. CONCLUSION

Due to rarity of Wilms' tumour in adolescent with extra-renal manifestation, all cases should be documented. Wilms' tumour should be kept in mind while considering a huge hepatomegaly and with radiologically finding show a retroperitoneal mass. The effect of pandemic COVID-19, make a huge impact to our health care service. In response to this global crisis, the health care service have to transition from the regular health service into an effective pandemic service to decrease the number of fatalities with utilizing the limited resources. The most significant impact to health care service due to COVID-19 is the high demand of the medical staff as well as resources. These, in which make the report valid to be documented for future reference.

#### ETHICAL APPROVAL

As per international standard or university standard written ethical approval has been collected and preserved by the author(s).

#### CONSENT

As per international standard or university standard, Parental written consent has been collected and preserved by the author(s).

#### COMPETING INTERESTS

Authors have declared that they have no known competing financial interests or non-financial interests or personal relationships that could have appeared to influence the work reported in this paper.

#### REFERENCES

1. Norman SW, Christopher JKB, Ronan PO. Bailey & Love's Short Practice of Surgery. 25th edition. Hachette Livre UK: Hodder Arnold. 2008;1006-1007.
2. Cheah PL, Looi LM, Lin HP. Wilms' tumour in Malaysian children: a histopathological study of cases encountered at the University Hospital, Kuala Lumpur over a 22-year period. *Malays J Pathol.* 1992;14(2):111-5. PMID: 1338998.
3. Ministry of Health Malaysia. Malaysia National Cancer Registry Report 2012-2016, 5th Ed. Available: <https://nci.moh.gov.my/index.php/ms/pengumuman/340-national-cancer-registry-report>. Accessed 18 August 2020.
4. Yunus M, Hashmi R, Hasan SH, et al. Extrarenal Wilms' tumor. *J Pak Med Assoc* 2003;53:436-9.
5. Bera, Goutam et al. Wilms' Tumour in an Adult- A Case Report of an Unusual Lesion. *Journal of clinical and diagnostic research: JCDR.* 2017;11,8: ED11-ED12. DOI:10.7860/JCDR/2017/22957.10383
6. Chew R, Reid R PJO' Dywer, V alue of a biopsy in the assessment of a retroperitoneal Mass, *Surgeon.* 2006;4(2): 79-81.
7. Weneger M, DeHesse JG, Kunz W et al, EnBloc resection of giant retroperitoneal lipoma: a case report and review of the literature, *BMC Research Notes.* 2015; 8(1):1038.
8. Coppes MJ, Wilson PC, Weitzman S. Extrarenal Wilms' tumor: staging, treatment, and prognosis. *J Clin Oncol.* 1991;9: 167-174.

9. Saltzman AF, Carrasco A Jr, Amini A, Cost NG: Patterns of care and survival comparison of adult and pediatric Wilms tumor in the United States: a study of the national cancer database. *Urology*. 2020; 135:50-6.
10. Ramachandra C, Attili VS, Dadhich HP, et al. Extrarenal Wilms' tumor: a report of two cases and review of literature. *J Indian Assoc Pediatr Surg*. 2007;12: 145-7.

---

© 2023 Bahari et al.; This is an Open Access article distributed under the terms of the Creative Commons Attribution License (<http://creativecommons.org/licenses/by/4.0>), which permits unrestricted use, distribution, and reproduction in any medium, provided the original work is properly cited.

*Peer-review history:*

*The peer review history for this paper can be accessed here:*  
<https://www.sdiarticle5.com/review-history/101857>