



Evaluation of Hepatoprotective and Antioxidant Activity of Ethanolic Extract of *Artabotrys zeylanicus* Stem against Various Hepatotoxins Induced Hepatotoxicity in Albino Wister Rats

K. Suresh¹, Hindustan Abdul Ahad^{2*} and S. V. Satyanarayana³

¹Jawaharlal Nehru Technological University Anantapur (JNTUA), Ananthapuramu-515001, Andhra Pradesh, India.

²Department of Industrial Pharmacy, Raghavendra Institute of Pharmaceutical Education and Research (RIPER) - Autonomous, KR Palli Cross, Cheyyedu-515721, Ananthapuramu, Andhra Pradesh, India.

³Department of Chemical Engineering, College of Engineering and Director, Academic and Planning, JNTU, Anantapur-515001, Andhra Pradesh, India.

Authors' contributions

This work was carried out in collaboration among all authors. Author KS has designed the study, performed the statistical analysis, wrote the protocol and wrote the first draft of the manuscript. Authors HAA and SVS managed the analyses of the study. All authors read and approved the final manuscript.

Article Information

DOI: 10.9734/JPRI/2020/v32i4731110

Editor(s):

(1) Dr. Rafik Karaman, Al-Quds University, Palestine.

Reviewers:

(1) Doaa Mohamed Elnagar, Ain Shams University, Egypt and King Saud University, Saudi Arabia.

(2) Luay Abed Ali Al-Helaly, University of Mosul, Iraq.

Complete Peer review History: <http://www.sdiarticle4.com/review-history/65340>

Original Research Article

Received 25 November 2020

Accepted 01 February 2021

Published 06 February 2021

ABSTRACT

Aim: The objective of the present study was to investigate the antioxidant and hepatoprotective activity of ethanolic stem extract of *Artabotrys zeylanicus* against paracetamol (PCT), Ethanol (ETN) and Isoniazid and Rifampicin (IR) induced hepatotoxicity in Albino wister rats.

Methodology: The material was dried in shade, they were powdered and extracted with ethanol. Preliminary Phytochemical tests were done. The hepatoprotective activity of the ethanol extract was assessed in Albino wister rats. PCT (3 g/kg), ETN (5 gm/kg) and IR (100 mg/kg) has enhanced

*Corresponding author: E-mail: abdulhindustan@gmail.com;

the levels of various biochemical markers of hepatic damage like Serum Glutamic Oxaloacetic Transaminase (SGOT), Serum Glutamic pyruvic transaminase (SGPT), Alkaline phosphatase (ALP), bilirubin. Antioxidant levels were tested in all the Hepatotoxins treated and untreated groups.

Results: The various biochemical and Histopathological investigations done were Serum Glutamic Oxaloacetic Transaminase (SGOT), Serum Glutamic pyruvic transaminase (SGPT), Alkaline phosphatase (ALP), Bilirubin, antioxidant activity by 1,1-diphenyl 2-picryl hydrazyl (DPPH), Nitro Blue Tetrazolium (NBT), Hydrogen peroxide (H_2O_2), lipid peroxidation, hydroxyl radical and nitric oxide. Treatment of ethanolic extract of stem of *A. zeylanicus* (100mg/kg, 200mg/kg and 400mg/kg body weight) has brought back the altered levels of biochemical markers to the near normal levels in the dose dependent manner. Ethanolic extract of *A. zeylanicus* were observed to inhibit oxidant stress with the maximum value of 71% and 62% at the concentration of 100 μ g/mL. The crude ethanolic extract of *A. zeylanicus* had a calculated IC_{50} value of 62.2 and 63.25 μ g/mL, which is nearly similar to the calculated IC_{50} value of the known antioxidant, ascorbic acid, ie 65.3 μ g/mL. While the rats treated with AZ extract (100, 200 and 400 mg/kg) which were shown as reduction/absence of inflammatory cells, vascular congestion, cellular degeneration, necrosis and vacuoles. In contrast, the lower doses (100 mg/kg) of ethanolic extract of AZ stem shown low protection than at higher dose 400 mg/kg.

Conclusion: Our findings suggested that *A. zeylanicus* ethanol stem extract possessed a potent antioxidant and hepatoprotective activity.

Keywords: *Hepatoprotective; artabotrys zeylanicus; paracetamol; ethanol; isoniazid and rifampicin; hepatotoxins; histopathological.*

1. INTRODUCTION

The liver is the main homeostatic organ in the body. It maintains homeostasis by regulating various physiological functions such as metabolism, secretion and storage [1]. It serves as a first line of defense and prevents toxic effects by detoxifying toxic substances. Various toxic chemicals, alcohols, drugs, infections and autoimmune diseases, through the process of lipid peroxidation and other mechanisms damage liver cells, leading to hepatotoxicity [2].

The liver plays a vital role in the metabolism of various substances, such as carbohydrates: glycogenesis (storage of glucose as glycogen), glycogenolysis (breakdown of glycogen into glucose), gluconeogenesis (production of glucose from a non-carbohydrate source) and protein - deamination amino acids (main detoxification mechanism) [3]. Together with the spleen, it helps reuse the proteins that make up old red blood cells. Liver damage is a key disease process in most chronic liver disease, and long-term liver damage causes liver fibrosis, liver cirrhosis, and even hepatocellular carcinoma [4,5]. Research has indicated that certain herbal extracts and their chemical components can significantly inhibit these pathological processes mentioned above and protect hepatocytes from the etiology of chronic liver damage. In the absence of effective liver protection drugs in modern medicine, a large

number of medicinal preparations are recommended for the treatment of liver ailments and are most often believed to offer significant relief [6]. Attempts are being made globally to obtain scientific evidence for these traditionally reported herbal drugs.

The plant kingdom has provided a diverse array of bioactive molecules which make them a valuable source, from a medical point of view. Due to the enormous limitations of synthetic drugs, little or no harmful effects and increased awareness of natural products, it takes an hour to isolate lead compounds from them [7]. One of those plants currently under investigation for its potential hepatoprotective and antioxidant activity in our laboratory is *Artabotrys zeylanicus* (family: Annonaceae) [8]. Commonly known as Ceylon Green Champa and South Indian tail grape in English [9,10].

Recent studies have shown varying levels of hepatoprotective prosperity in traditional plants found in southern India such as *Phyllanthus maderaspatensis*, [11] *Phyllanthus rheedii* [12], *Thespesia populnea* [13], *Momordica subangulata* [14], *Naregamia alata* [15], *Lygodium flexuosum*[16], *Cheilanthes farinose* [17], *Physalis peruviana* [18] and *Trichopus zeylanicus* [19]. However, many medicinal plants used in remote villages and tribal villages in the southern districts of Andhra Pradesh remain to be studied. *A. zeylanicus* is one of those plants.

This stem of the plant is used in folk medicine to treat liver disease in the Kurnool and Ananthapuramu districts of Andhra Pradesh. In traditional medicine, its roots are used to treat jaundice. Few studies have shown that the plant has antitumor and antimicrobial, antioxidant and antidiabetic activities. In addition, the phytochemical components of *A. zeylanicus* are also reported, indicating the presence of flavonoids, tannins and triterpenes. Polyphenolic flavonoids, in particular, have been shown to exhibit various pharmacological activities, including hepatoprotective activity.

Our study through the literature revealed that to date no attempt has been made to study the hepatoprotective activity of *A. zeylanicus* roots. Therefore, this study was conducted to obtain information on the utility of the ethanolic extract of the *A. zeylanicus* stem against various hepatotoxic models, namely, paracetamol (PCT), ethanol (ETN) and isoniazid and rifampicin-induced liver injury (IR) in rats. as an animal model for developing a successful hepatoprotective drug.

2. MATERIALS AND METHODS

2.1 Animals

Albino Wister rats of both sexes were used to study the crude extracts. The Institute's Animal Ethics Committee approved the project (831/a/19/CPCSEA). Animals were kept at $27 \pm 2^\circ\text{C}$, relative humidity 44-56%, and light and dark cycles of 10 and 14 hours, respectively, for 1 week before and during the experiments. The animals were given a standard diet (Lipton, India) and food was removed 18 hours before the start of the experiment and water ad libitum. All experiments were performed in the morning according to current laboratory animal care guidelines and ethical guidelines [20] for the study of experimental pain in conscious animals.

2.2 Plant Resources and Preparation of Crude Drug Extract

The stems of *A. Zeylanicus* was collected from Tirupati, Andhra Pradesh, India. And the authentication was performed by Dr. K. Madhava Chetty, assistant professor, Department of Botany, Sri Venkateshwara University, Tirupati, Andhra Pradesh. The herbarium sample was submitted to the College's Department of Pharmacognosy (Voucher specimen no-017 /

C112 / suresh-01). The stems were dried in the shade and degreased with petroleum ether. The defatted material was extracted with 95% ethanol using a soxhlet apparatus and then dried under vacuum.

2.3 Phytochemical Studies

All the extracts were subjected for Phytochemical study [21].

2.4 Acute Toxicity Studies

The acute toxicity study for ethanolic extract of stem of *A. Zeylanicus* stems were performed using albino rats. The animals were fasted overnight prior to the experiment and maintained under standard conditions. All the extracts were administered orally in increasing dose and found safe up to dose of 2000 mg/kg for all extracts [22]

2.5 Experimental Animal and Design

The experiment was conducted according to the modified procedures described above [5]. PCT (3 g / kg), ethanol 5 mg / kg and IR (50 + 50 mg / kg) were dissolved in 0.5% CMC for oral administration. The rats were randomly divided into six groups for each model and consisted of six rats. PCT poisoned animals were pooled from P1-P6. E1-E6 represents a group of animals intoxicated by ethanol and the group IR1-IR6 constitutes animals intoxicated by IR. Table 1 shows details of animal groupings for various hepatotoxicity models.

After 48 hours of intoxication, the rats were sacrificed with ether and then sacrificed. Blood was dissected by cardiac puncture into heparinized tubes for evaluation of different levels of AST, ALP and bilirubin enzymes using standard kits available. The liver was immediately removed and washed with ice-cold saline for histological observation. Table 1 shows the groups of animals.

2.6 Biochemical Determinations

The biochemical parameters like serum enzymes: aspartate aminotransferase (AST), Alanine aminotransferase (ALT) [23] serum alkaline phosphatase (ALP) [24] and total bilirubin [25] were assayed using assay kits (Span Diagnostic, Surat).

Table 1. Animal groupings for various hepato toxicity models

PCT Group*	ETN Group*	IR Group*	Served with
P1	E1	IR1	Normal control and was orally given pure water for seven days, and then intraperitoneally injected with 10 ml/kg body weight isotonic 0.9% NaCl
P2	E2	IR2	Hepatotoxicity control and was orally given pure water for seven days and then orally intoxicated.
P3	E3	IR3	Standard, and received Standard drug Silymarin 25gm/kg, orally.
P4	E4	IR4	Ethanol extract of <i>A. Zeylanicus</i> stem at 100 mg/kg, orally, for seven days.
P5	E5	IR5	Ethanol extract of <i>A. Zeylanicus</i> stem at 200 mg/kg, orally, for seven days.
P6	E6	IR6	Ethanol extract of <i>A. Zeylanicus</i> stem at 300 mg/kg, orally, for seven days.

*Each group contains 6 animals

2.7 In Vitro Anti-Oxidant Activity

2.7.1 DPPH-scavenging activity

The free radical scavenging activity of the extract was measured in terms of radical scavenging or hydrogen donation capacity using the stable radical DPPH [26]. A 0.1 mM solution in ethanol and 1.0 ml of this solution was prepared to 3.0 ml of all the extract solution in water at different concentrations (10–100 µg / mL). Thirty minutes later, the absorbance was measured at 517 nm. A lower absorbance of the reaction mixture indicates a greater elimination activity of free radicals. Ascorbic acid was used as a standard drug [26].

2.7.2 Scavenging of hydrogen peroxide (H₂O₂)

A solution of hydrogen peroxide (20 mm) in phosphate buffered saline (pH-7.4) was prepared, various concentrations of extract or standard in methanol (1 ml) were added to 2 ml of peroxide solution. hydrogen in PBS. After 10 min the absorbance was measured at 230 nm [27-30].

2.8 Histopathological Studies

Liver tissue was dissected and fixed in 10% formalin, dehydrated in stepwise ethanol (50-100%), eliminated in xylene and embedded in paraffin. Sections were prepared and then stained with hematoxylin and eosin (H-E) dye for photomicroscopic observation, including cell

necrosis, fat displacement, hyaline regeneration, balloon degeneration [31].

2.9 Statistical Analysis

The data are expressed as mean ±standard error of mean (SEM). The data were analysed using the one – way analysis of variance (ANOVA), and the differences between the groups were determined using the Dunnett post hoc test as provided by the graph pad PRISM V5.02 software. The limit of significance was set at p<0.05 [32].

3. RESULTS

3.1 Phytochemical Study

All extracts subjected for phytochemical study showed the presence of alkaloids, proteins, amino acids, phenolic compounds, glycosides and flavonoids.

3.2 Acute Toxicity Studies

Ethanol and aqueous extracts did not show any sign and symptoms of toxicity and mortality up to 2000 mg/kg dose. Table 2 shows the results of acute toxicity studies.

3.3 In vitro Antioxidant Study

Before proceeding for in vivo activity the efficacy of the plants was tested in vitro. The *in vitro* antioxidant activity was performed by using DPPH free radical and Hydrogen Peroxide scavenging. Results were tabulated in Table 3.

Table 2. Acute oral toxicity study of AZ

Treatment	Body weight (gm)	Mortality (Animals dead)			Toxicity profile
	Rat (n=5)	After 24 hrs	After 7 days	After 14 days	
Ethanol extract of AZ stem	150 ±10.50	0	0	0	Safe

Table 3. *In vitro* antioxidant activity of AZ

Conc. (µg/ml)	% Inhibition		Ascorbic acid
	DPPH free radical	Hydrogen peroxide scavenging	
20	21.8 ± 0.47	25.15± 0.92	31.5 ± 0.15
40	39.6 ± 0.72	28.68± 1.57	54.9 ± 0.92
60	48.3 ± 0.57	32.94± 0.58	61.8 ± 0.38
80	58.1 ± 0.41	48.23± 0.39	70.2 ± 0.72
100	67.35 ±0.29	57.29± 0.91	81.3 ± 0.69
120	71.5 ± 0.47	62.23± 1.26	91.9 ± 0.45
Half maximum inhibitory concentration (IC ₅₀)	62.2	63.25	65.3

3.4 Effect of the Ethanol Extract of AZ Stem on Biochemical Parameters against PCT Induced Hepatotoxicity

AST, ALT, ALP, Bilirubin, SOD, CAT, MDA, and GSH are highly sensitive liver markers and their elevated levels are indicative of liver damage. Table 4 shows the results of the AZ stem cell ethanol extract on various biochemical parameters. There were no marked changes in the levels of these parameters detected in normal control rats. Rats with induced liver injury were injected with IP PCT, representing significantly elevated SGOT, SGPT, ALP, bilirubin, SOD, CAT, MDA, and GSH activities compared to the normal control group. However, a significant decrease in elevated serum enzyme levels can be observed in the AZ treatment (400 mg / kg) compared to the PCT treated group. The dose-dependent effect of AZ is comparable to that of silymarin treatment. These results indicated a protective effect of the AZ stem ethanol extract on PCT-induced liver injury in rats.

Histopathologically, non-PCM-intoxicated liver pretreated with 10% DMSO (normal) shows normal lobular architecture and normal liver cells with well-preserved cytoplasm and well-defined sinusoidal line and nucleus around the perivenular area (Fig. 1 (a)). The PCM-intoxicated section of the liver, pretreated with 10% DMSO, shows infiltration of lymphocytes, presence of hemorrhage and extensive coagulative necrosis of the perivenular and mid-

zonal region with periportal sparing (Fig. 1 (b)). Coagulative necrosis of hepatocytes in PCM-induced liver toxicity is predominantly present in the perivenular zone (zone 3). These pathological changes were found to be less with increasing MEBP dose, indicating the extract's ability to reverse PCM-induced intoxication (Figs. 1(d) - 1(f)). Interestingly, the presence of marked necrosis, inflammation and hemorrhage following PCM treatment (shown by the negative control group) was significantly reduced when pretreated with the extract or silymarin.

3.5 Effect of the Ethanol Extract of AZ Stem on Biochemical Parameters against ETN Induced Hepatotoxicity

The hepatotoxic agent ethanol caused significant liver damage as indicated by the increased levels of liver chemistry biomarkers such as AST, ALT, ALP, Bilirubin, SOD, CAT, MDA and GSH. Rats treated with 100, 200 and 400 mg/kg doses significantly reduced levels of biochemical markers when compared with ETN administered controls. As compared to the lower doses, the higher one (400 mg/kg) demonstrated an improved hepatoprotective activity. Table 5 shows the detailed results of effect of ethanol extract of AZ stem on biochemical parameters against ETN induced hepatotoxicity.

The hepatoprotective effect of the ethanol extract of the AZ stem on ETN-induced liver injury was further confirmed by histopathological

examinations. Non-intoxicated liver with ETN pretreated with 10% DMSO (normal) shows normal lobular architecture and normal liver cells with well preserved cytoplasm and well-defined sinusoidal line and a nucleus around the perivenular area (Fig. 2(a)). Normal histological structures were observed in the liver of rats treated with silymarin (25 g / kg) as shown in Fig. 2(b). Liver cell abnormalities, necrosis and inflammation were observed in ETN-treated rats (Fig. 2(c)). While rats treated with AZ extract (100, 200 and 400 mg/kg) showed reduction/absence of inflammatory cells, vascular congestion, cell degeneration, necrosis and vacuoles. (Fig. 2(d,e,f)). In contrast, lower doses (100 mg/kg) of ethanolic extract of AZ stems showed lower protection than a higher dose of 400 mg/kg.

3.6 Effect of the Ethanolic Extract of AZ Stem on Biochemical Parameters against IR Induced Hepatotoxicity

The AZ ethanolic extract showed significant hepatoprotective activity ($p < 0.05$) against the toxicity patterns induced by isoniazid and rifampicin (50 mg / kg + 50 mg / kg) by improving liver function, as indicated by the reduction of liver enzyme levels compared to the control group. Table 6 shows the detailed results of hepatoprotective activity against the IR-induced hepatotoxicity model. Histopathological studies in liver extracted from IR-induced rats pretreated with 10% DMSO revealed significant damage ($p < 0.05$) in liver architecture, with severe hepatocyte necrosis. Non-IR intoxicated liver pretreated with 10% DMSO (normal) shows normal lobular architecture and normal liver cells with well-preserved cytoplasm and well-defined sinusoidal line and nucleus around the perivenular area (Fig. 3 (a)). Normal histological structures were observed in the liver of rats treated with silymarin (25 g / kg) as shown in Fig. 3 (b). Alterations of liver cells, necrosis, and inflammation were observed in the rats given IR (Fig. 3 (c)). While rats treated with AZ extract (100, 200 and 400 mg / kg) showed reduction / absence of inflammatory cells, vascular congestion, cell degeneration, necrosis and vacuoles. (Fig. 2 (d,e,f) respectively). In contrast, lower doses (100 mg / kg) of ethanolic extract of AZ stems showed lower protection than a higher dose of 400 mg / kg.

4. DISCUSSION

The liver plays an indispensable role in life thanks to its metabolic and detoxifying capabilities. As it is exposed to various endogenous and xenobiotic agents, a large number of intermediate and final products are produced which can cause hepatocellular death and are the main causes of liver disease.[33,34] To ensure an individual's survival and maintain liver function, conventional treatment focuses on symptom management and liver transplantation in severe cases of liver disease.[35] However, no drugs are currently used to increase the detoxifying power of the organ. Therefore, the tests and use of herbal hepatoprotective agents are increasing dramatically. Therefore, it would be absolutely imperative to demonstrate the efficacy of plant extracts in the presence of chemical induced hepatotoxicity [33].

Paracetamol (PCT) and ethanol (ETN) have generally been consumed by humans for reasons such as pyrexia and those who have a habit of drinking alcohol, respectively. Isoniazid and rifampicin (IR) are the most commonly used drugs to treat tuberculosis. All of these agents were known to induce hepatotoxicity.[33] Therefore, the same hepatotoxins were chosen to induce hepatotoxicity in rats and to evaluate the hepatoprotective activity of *Artabotrys zeylanicus*. The rats were treated with ethanolic extract of the *A. zeylanicus* stem. Several studies indicate that PCT, ETN and IR can cause hemorrhagic liver necrosis in humans and experimental animals.[33] Thus, in this study, rats treated with PCT, ETN, and IR resulted in increased rat liver weight through the development of infiltration, vacuolation and inflammation in the liver (Fig. 1b 2b and 3b). PCT, ETN and IR induced hepatotoxicity was used to evaluate the hepatoprotective potential of plant extracts in various animal models. These hepatotoxins are bioactivated by cytochrome P450 into highly unstable reactive free radicals. These can cause cell damage through peroxidation of membrane lipids and covalently bind with other macromolecules within hepatocytes.[34] Damage to the membrane causes the release of cytosolic and endoplasmic enzymes, which show damage to the structure and function of the liver. These manifest as elevations of SGOT, SGPT, ALP, Bilirubin, SOD, CAT, MDA and GSH levels.

Table 4. Effect of the ethanolic extract of AZ stem on biochemical parameters in PCT induced hepatotoxicity

Group	AST U/L	ALT U/L	ALP U/L	BILURUBIN mg/dL	SOD (units/mg liver protein)	CAT (units/mg liver protein)	MDA (nmol/g tissue)	GSH (μ mol/g tissue)
P1	91.87 \pm 1.411	63.83 \pm 0.693	71.50 \pm 0.638	0.245 \pm 0.151	95.35 \pm 1.562	132.8 \pm 0.472	29.9 \pm 0.471	42.9 \pm 0.592
P2	243.5 \pm 2.349	291.5 \pm 1.763	208.5 \pm 0.458	0.957 \pm 0.392	37.93 \pm 1.095	66.2 \pm 0.928	61.2 \pm 0.091	13.2 \pm 0.184
P3	104.5 \pm 0.763**	87 \pm 0.577**	85.50 \pm 0.763**	0.296 \pm 0.113**	86.79 \pm 1.373	116.3 \pm 1.537	32.2 \pm 0.927	38.2 \pm 0.316
P4	203.8 \pm 0.534	261.8 \pm 0.609	181.5 \pm 0.428	0.677 \pm 0.071	45.3 \pm 0.947	68.2 \pm 0.638	56.6 \pm 0.972	17.83 \pm 0.853
P5	198.3 \pm 0.494**	211.3 \pm 0.482**	161.3 \pm 0.631**	0.574 \pm 0.048**	58.6 \pm 0.381**	82.3 \pm 0.753**	48.2 \pm 0.642 **	21.53 \pm 0.851**
P6	171.2 \pm 0.600**	141.2 \pm 0.081**	116.3 \pm 0.286**	0.476 \pm 0.514**	74.86 \pm 0.719 **	98.4 \pm 1.084 **	37.6 \pm 0.371 **	32.91 \pm 0.640 **

**P < 0.001 significant with respect to Control group. Values are expressed as mean \pm S.E; n=6 in each group. statistical analysis one-way ANOVA followed by t-test

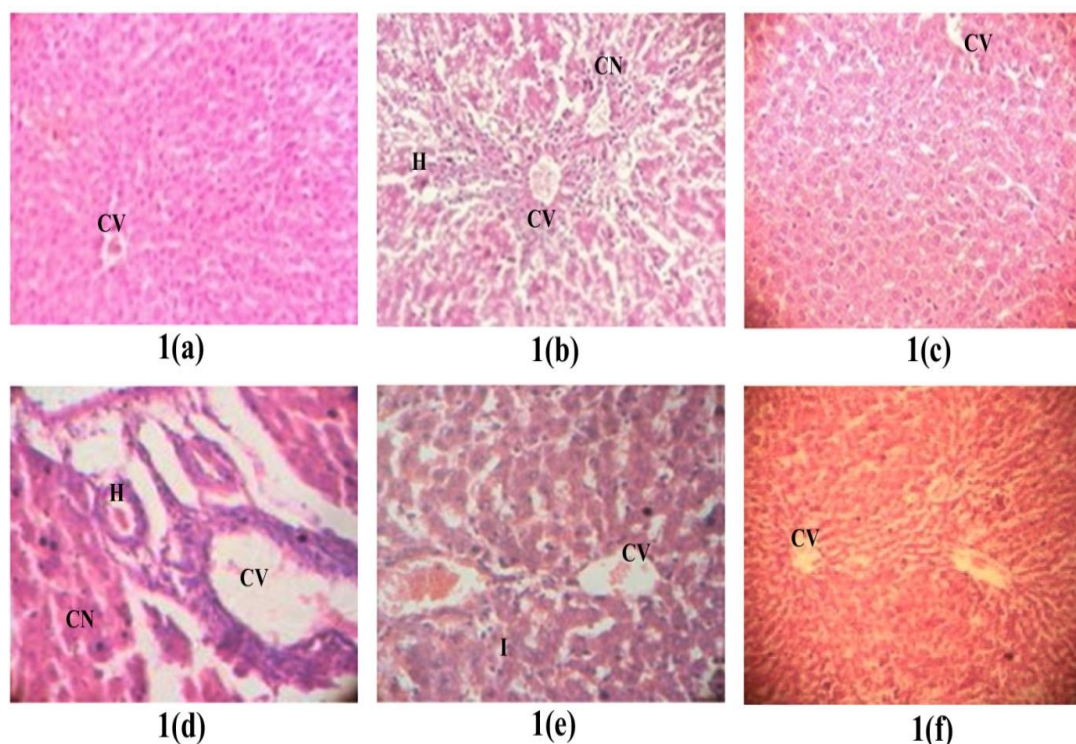


Fig. 1. (a) Normal; (b) Section of liver tissue of 3g/kg PCT treated group showing massive coagulative necrosis, hemorrhage and inflammation; (c) Section of 25gm/kg of silymarin liver tissue pretreated on the liver followed by PCT showing preservation of normal hepatocytes; (d) Section 100 mg/kg AZ liver tissue intoxicated with PCT showing tissue necrosis and inflammation; (e) Section 200 mg/kg AZ liver tissue intoxicated with PCT showing tissue necrosis and inflammation; (f) Section 400 mg/kg AZ liver tissue intoxicated with PCT showing normal histology with mild inflammation. (100x Magnification) CV: centrilobular. CN: coagulative necrosis. I: inflammation. H: haemorrhage

Table 5. Effect of the ethanolic extract of AZ stem on biochemical parameters in ETN induced hepatotoxicity

Group	AST U/L	ALT U/L	ALP U/L	BILURU BIN mg/dL	SOD (units/m g liver protein)	CAT (units/m g liver protein)	MDA (nmol/g tissue)	GSH (μ mol/g tissue)
E1	91.87 \pm 1.411	63.83 \pm 0.693	71.50 \pm 0.638	0.245 \pm 0.151	96.35 \pm 1.562	131.8 \pm 0.472	28.9 \pm 0.471	42.9 \pm 0.592
E2	241.5 \pm 2.349	291.5 \pm 1.763	208.5 \pm 0.458	0.957 \pm 0.392	38.93 \pm 1.095	65.2 \pm 0.928	60.2 \pm 0.091	14.2 \pm 0.184
E3	104.5 \pm 0.763**	84 \pm 0.577**	85.50 \pm 0.763**	0.296 \pm 0.113**	85.79 \pm 1.373	115.3 \pm 1.537	31.2 \pm 0.927	39.2 \pm 0.316
E4	212.2 \pm 0.577	258.5 \pm 0.763	183.8 \pm 1.169	0.693 \pm 0.068	43.9 \pm 0.731	75.2 \pm 0.521	54.6 \pm 1.003	17.07 \pm 0.635
E5	194.2 \pm 0.703**	208.5 \pm 0.412**	157.8 \pm 0.703**	0.565 \pm 0.192**	58.2 \pm 1.179 **	83.1 \pm 0.052 **	48.2 \pm 0.521 **	21.94 \pm 0.168 **
E6	158.5 \pm 0.763**	131.3 \pm 0.881**	112.8 \pm 0.792**	0.461 \pm 0.168**	70.12 \pm 1.153 **	103.9 \pm 0.581 **	39.2 \pm 0.257 **	34.86 \pm 0.921 **

** $P < 0.001$ significant compared to the control group. Values are expressed as mean \pm S.E; $n = 6$ in each group. One-way ANOVA statistical analysis followed by t -test

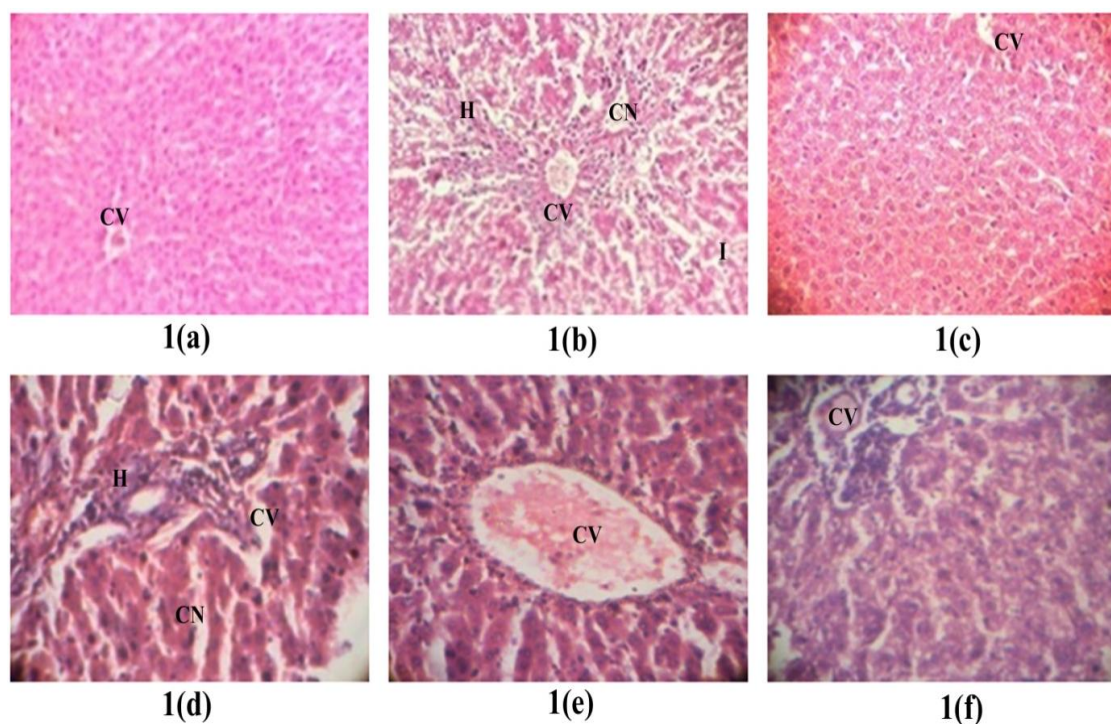


Fig. 2. (a) Normal; (b) Section of liver tissue of 5g/kg ETN treated group showing massive coagulative necrosis, hemorrhage and inflammation; (c) Section of 25gm/kg of silymarin liver tissue pretreated on the liver followed by PCT showing preservation of normal hepatocytes; (d) Section 100 mg/kg AZ liver tissue intoxicated with ETN showing tissue necrosis and inflammation; (e) Section 200 mg/kg AZ liver tissue intoxicated with ETN showing tissue necrosis and inflammation; (f) Section 400 mg/kg AZ liver tissue intoxicated with ETN showing normal histology. (100x Magnification) CV: centrilobular. CN: coagulative necrosis. I: inflammation. H: haemorrhage

Table 6. Effect of the ethanolic extract of AZ stem on biochemical parameters in IR induced hepatotoxicity

Group	AST U/L	ALT U/L	ALP U/L	BILUR UBIN mg/dL	SOD (units/m g liver protein)	CAT (units/m g liver protein)	MDA (nmol/g tissue)	GSH (μ mol/g tissue)
IR1	91.87 \pm 1.411	63.83 \pm 0.693	71.50 \pm 0.638	0.244 \pm 0.151	95.35 \pm 1.562	132.8 \pm 0.472	29.9 \pm 0.471	43.9 \pm 0.592
IR2	243.5 \pm 2.349	291.5 \pm 1.763	208.5 \pm 0.458	0.954 \pm 0.192	39.93 \pm 1.095	64.2 \pm 0.928	62.2 \pm 0.091	13.2 \pm 0.184
IR3	104.5 \pm 0.763**	84 \pm 0.577**	83.50 \pm 0.763**	0.294 \pm 0.113**	86.79 \pm 1.373	114.3 \pm 1.537	33.2 \pm 0.927	38.2 \pm 0.316
IR4	206.5 \pm 1.176	256.5 \pm 0.834	186.5 \pm 0.496	0.657 \pm 0.050	47.2 \pm 1.156	71.2 \pm 0.947	52.8 \pm 0.731	18.90 \pm 0.680
IR5	187 \pm 0.575**	203.8 \pm 0.369**	151.5 \pm 0.436**	0.570 \pm 0.068**	61.3 \pm 0.961**	83.71 \pm 0.567**	48.5 \pm 0.570**	22.37 \pm 0.421**
IR6	143.8 \pm 0.912**	121.8 \pm 0.945**	103.5 \pm 0.672**	0.423 \pm 0.154**	72.80 \pm 0.915**	99.2 \pm 0.269**	37.7 \pm 0.358**	32.48 \pm 0.631**

** $P < 0.001$ significant with respect to control group. Values are expressed as mean \pm S.E.M; n=6 in each group. Statistical analysis one-way ANOVA followed by *t*-test

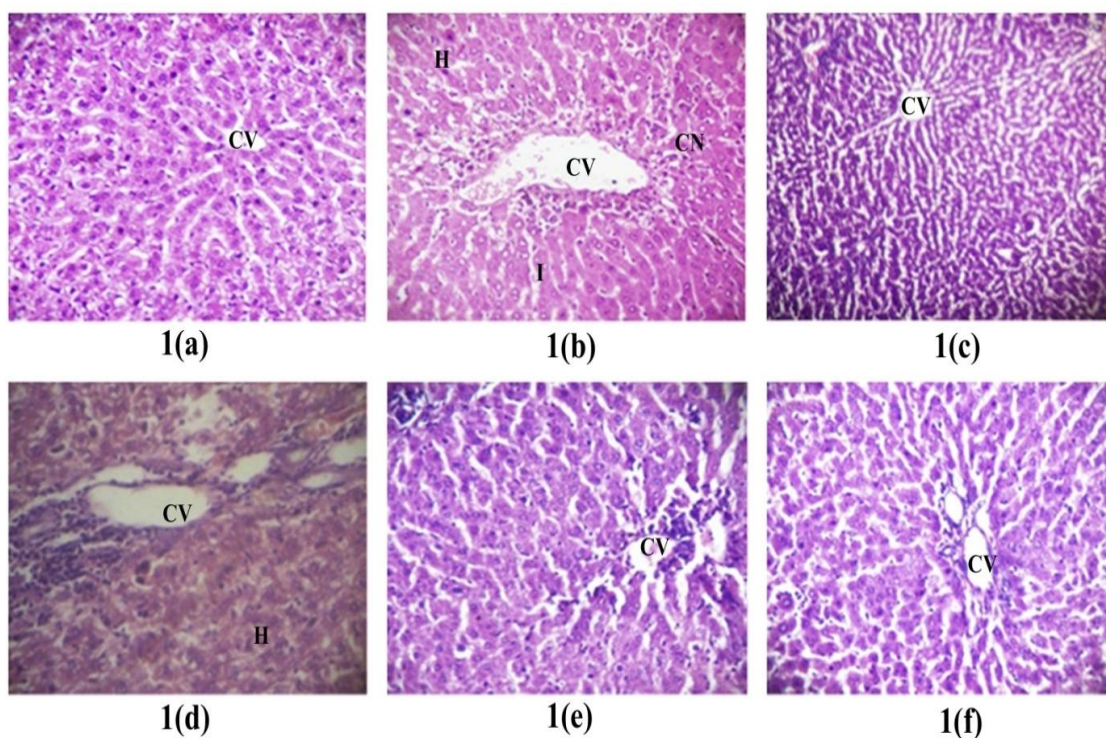


Fig. 3. (a) Normal; (b) Section of liver tissue of 100g/kg IR treated group showing massive coagulative necrosis, hemorrhage and inflammation; (c) Section of 25gm/kg of silymarin liver tissue pretreated on the liver followed by IR showing preservation of normal hepatocytes; (d) Section 100 mg/kg AZ liver tissue intoxicated with IR showing tissue necrosis and inflammation; (e) Section 200 mg/kg AZ liver tissue intoxicated with IR showing tissue necrosis and inflammation; (f) Section 400 mg/kg AZ liver tissue intoxicated with IR showing normal histology. (100x Magnification) CV: centrilobular. CN: coagulative necrosis. I: inflammation. H: haemorrhage

Therefore, measuring the levels of these biomarkers of liver damage can reveal the hepatoprotective activity of the plant extract and solvent fractions. In the present study, the ethanolic extract showed a reduction in the levels of SGOT, SGPT, ALP, Bilirubin, SOD, CAT, MDA and GSH in a dose-dependent manner. 100 mg / kg of AZ ethanolic stem extract did not produce a visible effect on all biomarkers of liver injury at their lowest dose, but medium and high doses managed to produce a significant reduction in AST, ALT and ALP levels (Tables 4-6). This could likely suggest that the lower dose may be less than the minimum effective dose, which cannot cause a significant reduction in liver enzyme levels, and the other two doses may be large enough to cause a significant reduction. Percent reduction of hepatic injury biomarkers showed that 200 mg / kg and 400 mg / kg of the ethanolic extract exerted an effect almost similar to that of the standard (Tables 4-6). The pre and post treatment with ethanolic extract in the two doses (200 mg / kg and 400 mg / kg) except for the 100 mg / kg dose strongly modulated the severity of the liver damage. The return of enzyme levels to near-normal levels in ethanolic rats before and after treatment shows that the ethanolic extract can stabilize liver cell membranes and prevent the escape of enzymes.

The prevention of free radical production and their neutralization, as well as the protection potential of this plant from hepatotoxins, may be other probable reasons for the healing effect of *A. zeylanicus* stem extract. To concentrate or separate the active ingredients, the crude ethanolic extract was fractionated. This study showed that most of the polar components of the plant stem could be due to the available flavonoidal content. The active principle or the principles responsible for the hepatoprotective activity of the ethanolic extract and the solvent fractions of *A. zeylanicus* are, until now, unknown, therefore it has not been identified which compounds are exactly responsible for the antioxidant and hepatoprotective activities. Previous studies have shown that alkaloids and flavonoids have antioxidant activity. Preliminary phytochemical analysis was performed on the crude ethanolic extract and the solvent fractions revealed a variety of secondary metabolites which appeared to be differentially distributed throughout the extract. It is reasonable to suggest that the phytochemicals present in the plant may act individually or synergistically to produce the observed hepatoprotective activity of *A. zeylanicus*. Probably, the flavonoids and

alkaloids present in the raw stem extract exerted a hepatoprotective effect due to their free radical scavenging activity, prevention of lipid peroxidation and cell damage, as such action has been suggested for some other plants. Furthermore, alkaloids and flavonoids are known as natural antioxidants due to their free radical scavenging activity [34].

As the liver is continuously exposed to oxidative stress, the release of free radicals is the main hepatotoxicity mechanism of toxicants. In oxidative stress, the balance between the formation of reactive oxygen species and the amount of antioxidants is disturbed. Oxidative stress causes damage to cell components, such as proteins, lipids and nucleic acids.[33] To confirm the antioxidant activity of the plant extract, in vitro DPPH radical scavenging and hydrogen peroxide scavenging assay were carried out. In these scavenging assay, ethanolic extract of *A. zeylanicus* were observed to inhibit with the maximum value of 71% and 62% at the concentration of 100 µg/mL (Table 3). The crude ethanolic extract of *A. zeylanicus* had a calculated IC₅₀ value of 62.2 and 63.25 µg/mL, which is nearly similar to the calculated IC₅₀ value of the known antioxidant, ascorbic acid, ie 65.3 µg/mL. As it is explained for other plants ethanolic extract might act via their free radical scavenging, neutralization of free radicals and inhibition of necrosis via several pathways.

To sum up, this study provided further evidence that the ethanolic extract, possessed a comparable hepatoprotective activity with that of the standard drug. Results obtained revealed that there was a dose-dependent reduction in all biomarkers of liver injury in pre- and post-treatment. Therefore, this data seems to indicate that the hepatoprotective effect of the plant is distributed to polar bioactive principles contained in the ethanolic fraction. Even though the hepatoprotective mechanism of the plant extract is yet not elucidated, the observed antioxidant activity is one of the anticipated mechanisms. Above all, the ethanolic extract of the stem of *A. zeylanicus* would be rewarded as safe based on the results of acute oral toxicity study. Moreover, isolation and characterization of novel antioxidants will be done in future studies by using HPLC/LC-MS/MS techniques.

5. CONCLUSION

Experimental evidence obtained in the present study demonstrated that the *A. zeylanicus* stem

possesses hepatoprotective activity against PCT, ETN and IR induced liver toxicity. This activity may be due to the presence of flavonoids and other components present in the plant. However, complementary in vitro and in vivo studies will be necessary to confirm the mechanism responsible for this hepatoprotective effect.

DISCLAIMER

The products used for this research are commonly and predominantly use products in our area of research and country. There is absolutely no conflict of interest between the authors and producers of the products because we do not intend to use these products as an avenue for any litigation but for the advancement of knowledge. Also, the research was not funded by the producing company rather it was funded by personal efforts of the authors.

CONSENT

It is not applicable.

ETHICAL APPROVAL

The authors declare that the study was approved by institutional animal ethical committee with the project no. (831/a/19/CPCSEA)

ACKNOWLEDGEMENT

The authors would like to thank management of Mother Theresa Institute of Pharmaceutical Education and Research, Kurnool Dist. A.P. India for their technical support and animal breeding.

COMPETING INTERESTS

Authors have declared that no competing interests exist.

REFERENCES

1. Kousteni S. Fox, the transcriptional chief of staff of energy metabolism. *Bone*. 2012;50(2):437-43.
2. Ingawale DK, Mandlik SK, Naik SR. Models of hepatotoxicity and the underlying cellular, biochemical and immunological mechanism (s): A critical discussion. *Environmental Toxicology and Pharmacology*. 2014;37(1):118-33.
3. Radziuk J, Pye S. Hepatic glucose uptake, gluconeogenesis and the regulation of glycogen synthesis. *Diabetes/Metabolism Research and Reviews*. 2001;17(4):250-72.
4. Aleksunes LM, Manautou JE. Emerging role of nrf2 in protecting against hepatic and gastrointestinal disease. *Toxicologic Pathology*. 2007;35(4):459-73.
5. Ahad HA, Yesupadam P, Rani EM, Padmaja BS, Swamy BK. Phytochemical and anti-inflammatory evaluation of *Alangium lamarckii* root extract. *Der Pharmacia Sinica*. 2011;2(2):119-26.
6. Zhang C, Wang N, Xu Y, Tan HY, Li S, Feng Y. Molecular mechanisms involved in oxidative stress-associated liver injury induced by chinese herbal medicine: An experimental evidence-based literature review and network pharmacology study. *International Journal of Molecular Sciences*. 2018;19(9):2745.
7. Ahad HA, Padmaja BS, Sravanthi M, Ramyasree P, Kavitha K. Phytochemical screening and anti-inflammatory actions of *Alangium salviifolium* root extract. *Natural Product Research*. 2012;26(17):1649-53.
8. Mathew J, George KV. *Artabotrys zeylanicus* var. *kottavasaliyana* (Annonaceae): a new variety from southern Western Ghats. *Int. J. Plant Anim. Environ. Sci*. 2013; 3:153-5.
9. Jindal SL. Flowering shrubs in India. Publications Division Ministry of Information and Broadcasting; 2017.
10. Ahad HA, Kumar CS, Kumar BA, Reddy BA, Shekar AC, Ravindra BV, Venkatnath SL. Development and in vitro evaluation of Glibenclamide aloe barbadensis miller leaves mucilage controlled release matrix tablets. *International Journal of Pharm Tech Research*. 2010;2(2):1018-21.
11. Srirama R, Deepak HB, Senthilkumar U, Ravikanth G, Gurumurthy BR, Shivanna MB, Chandrasekaran CV, Agarwal A, Shaanker RU. Hepatoprotective activity of Indian *phyllanthus*. *Pharmaceutical Biology*. 2012;50(8):948-53.
12. Prakash A, Satyan KS, Wahi SP, Singh RP. Comparative hepatoprotective activity of three *Phyllanthus* species, *P. urinaria*, *P. niruri* and *P. simplex*, on carbon

- tetrachloride induced liver injury in the rat. *Phytotherapy Research*. 1995;9(8):594-6.
13. Yuvaraj P, Subramoniam A. Hepatoprotective property of *Thespesia populnea* against carbon tetrachloride induced liver damage in rats. *Journal of Basic and Clinical Physiology and Pharmacology*. 2009;20(2):169-78.
 14. Ahad HA, Padmaja BS, Sravanthi M, Ramyasree P, Kavitha K. Phytochemical screening and anti-inflammatory actions of *Alangium salviifolium* root extract. *Natural Product Research*. 2012;26(17):1649-53.
 15. Bhar MK, Das SK, Chakraborty AK, Mandal TK, Roy S. Hepatoprotective effect of enliv® on paracetamol-induced liver damage in broiler chicks. *Indian journal of pharmacology*. 2005;37(4):257.
 16. Wills PJ, Asha VV. Protective effect of *Lygodium flexuosum* (L.) Sw. extract against carbon tetrachloride-induced acute liver injury in rats. *Journal of Ethnopharmacology*. 2006;108(3):320-6.
 17. Radhika NK, Sreejith PS, Asha VV. Cytotoxic and apoptotic activity of *Cheilanthes farinosa* (Forsk.) kaulf. against human hepatoma, Hep3B cells. *Journal of Ethnopharmacology*. 2010;128(1):166-71.
 18. Chang JC, Lin CC, Wu SJ, Lin DL, Wang SS, Miaw CL, Ng LT. Antioxidative and hepatoprotective effects of *Physalis peruviana* extract against acetaminophen-induced liver injury in rats. *Pharmaceutical Biology*. 2008;46(10-11):724-31.
 19. Subramoniam A, Evans DA, Rajasekharan S, Pushpangadan P. Hepatoprotective activity of *Trichopus zeylanicus* extract against paracetamol-induced hepatic damage in rats. *Indian Journal of Experimental Biology*. 1998; 36(4):385.
 20. National Research Council. Guide for the care and use of laboratory animals. National Academies Press; 2010.
 21. Yadav RN, Agarwala M. Phytochemical analysis of some medicinal plants. *Journal of Phytology*; 2011.
 22. Akhila JS, Shyamjith D, Alwar MC. Acute toxicity studies and determination of median lethal dose. *Current Science*. 2007:917-20.
 23. Reitman S, Frankel S. A colorimetric method for the determination of serum glutamic oxalacetic and glutamic pyruvic transaminases. *American Journal of Clinical Pathology*. 1957;28(1):56-63.
 24. King J. The hydrolases-acid and alkaline phosphatases. *Practical Clinical Enzymology*; 1965.
 25. Malloy HT, Evelyn KA. The determination of bilirubin with the photoelectric colorimeter. *Journal of Biological Chemistry*. 1937;119(2):481-90.
 26. Marinova G, Batchvarov V. Evaluation of the methods for determination of the free radical scavenging activity by DPPH. *Bulgarian Journal of Agricultural Science*. 2011;17(1):11-24.
 27. Sroka Z, Cisowski W. Hydrogen peroxide scavenging, antioxidant and anti-radical activity of some phenolic acids. *Food and Chemical Toxicology*. 2003;41(6):753-8.
 28. Dash DK, Yeligar VC, Nayak SS, Ghosh T, Rajalingam R, Sengupta P, Maiti BC, Maity TK. Evaluation of hepatoprotective and antioxidant activity of *ichnocarpus frutescens* (Linn.) R. Br. on paracetamol-induced hepatotoxicity in rats. *Tropical Journal of Pharmaceutical Research*. 2007;6(3):755-65.
 29. Acharya KR, Chatterjee SO, Biswas GU, Chatterjee AN, Saha GK. Hepatoprotective effect of a wild edible mushroom on carbon tetrachloride-induced hepatotoxicity in mice. *Int J Pharm Pharm Sci*. 2012;4(3):285-8.
 30. Haldar PK, Adhikari S, Bera S, Bhattacharya S, Panda SP, Kandar CC. Hepatoprotective efficacy of *Swietenia mahagoni* L. Jacq. (Meliaceae) bark against paracetamol-induced hepatic damage in rats. *Ind J Pharm Edu Res*. 2011;45(2):108-13.
 31. Tuer AE, Tokarz D, Prent N, Cisek R, Alami J, Dumont DJ, Bakueva L, Rowlands JA, Barzda V. Nonlinear multicontrast microscopy of hematoxylin-and-eosin-stained histological sections. *Journal of Biomedical Optics*. 2010;15(2):026018.
 32. Brown AM. A new software for carrying out one-way ANOVA post hoc tests. *Computer Methods and Programs in Biomedicine*. 2005;79(1):89-95.
 33. Meharie BG, Amare GG, Belayneh YM. Evaluation of Hepatoprotective activity of the crude Extract and Solvent Fractions of *Clutia abyssinica* (Euphorbiaceae) Leaf Against CCl₄-Induced hepatotoxicity in

- mice. Journal of Experimental Pharmacology. 2020; 12:137-50.
34. Armeni T, Principato G. Glutathione, an over one billion years' ancient molecule, is still actively involved in cell regulatory pathways. In the First Outstanding 50 Years of "Università Politecnica delle Marche". Springer, Cham. 2020;417-429.
35. Hoofnagle JH, Carithers Jr RL, Shapiro C, Ascher N. Fulminant hepatic failure: Summary of a workshop. Hepatology. 1995;21(1):240-52.

© 2020 Suresh et al.; This is an Open Access article distributed under the terms of the Creative Commons Attribution License (<http://creativecommons.org/licenses/by/4.0>), which permits unrestricted use, distribution, and reproduction in any medium, provided the original work is properly cited.

Peer-review history:
The peer review history for this paper can be accessed here:
<http://www.sdiarticle4.com/review-history/65340>