



## **Effect of Dexamethasone in Surgical Extraction of Mandibular Impacted Third Molar**

**Abdul Hayee Shaikh<sup>1</sup>, Kashif Ali Channar<sup>2</sup>, Ajeet Kumar<sup>3</sup>, Naveed Iqbal<sup>3</sup>,  
Junaid Shakeel<sup>3</sup>, Uzma Shahid<sup>4</sup>, Shumaila Shaikh<sup>5</sup>, Nayel Syed<sup>6</sup>,  
Aisha Jabeen<sup>6</sup>, Mirza Tasawer Baig<sup>6\*</sup> and Imran Qureshi<sup>7</sup>**

<sup>1</sup>Paramedical Institute of Sindh, Jamshoro, Pakistan.

<sup>2</sup>Liaquat University of Medical and Health Sciences, Jamshoro, Pakistan.

<sup>3</sup>Sir Syed College of Medical Sciences, Karachi, Pakistan.

<sup>4</sup>Surecell Australia Clinics Clifton, Karachi, Pakistan.

<sup>5</sup>Bibi Aseefa Dental College, SMBBMU, Larkana, Pakistan.

<sup>6</sup>Faculty of Pharmacy, Ziauddin University, Karachi, Pakistan.

<sup>7</sup>Dr. Ziauddin Hospital Clifton, Karachi, Pakistan.

### **Authors' contributions**

*This work was carried out in collaboration between all authors. Authors AHS, KAC, AK, NI and JS designed the study, performed the statistical analysis, wrote the protocol, and wrote the first draft of the manuscript. Authors SS, NS, AJ, MTB and IQ managed the analyses of the study. Authors US and SS managed the literature searches. All authors read and approved the final manuscript.*

### **Article Information**

DOI: 10.9734/JPRI/2020/v32i4731107

#### Editor(s):

(1) Dr. R. Deveswaran, M. S. Ramaiah University of Applied Sciences, India.

#### Reviewers:

(1) Roberto Rossi, Università di Genova, Italy.

(2) Chrysanthakopoulos Nikolaos, University of Athens, Greece.

(3) Mona Ionas, University Lucian Blaga of Sibiu, Romania.

Complete Peer review History: <http://www.sdiarticle4.com/review-history/64698>

**Original Research Article**

**Received 10 November 2020**

**Accepted 17 January 2021**

**Published 06 February 2021**

### **ABSTRACT**

**Objective:** The objective of this study was to determine the role of dexamethasone in mandibular third molar surgical extraction.

**Methodology:** This cross sectional study was conducted in Oral & Maxillofacial surgery department, Liaquat University of Medical & Health sciences Hyderabad / Jamshoro. 50 cases were included in this study by using simple random sampling technique. All patients were divided into two groups. Patients in Group-A were given dexamethasone (DM)8 mg intramuscularly (IM) before surgery and 4 mg 24 hours after surgery and Augmentin tablet 625mg Q12 hrs. and Brufen

\*Corresponding author: E-mail: mirzatasawerbaig@gmail.com;

400 mg Q8 hrs. and patients in group-B were given Augmentin 625 mg BD and Brufen 400 mg TDS post operatively only. The facial swelling was checked before and after surgery. All information was collected and entered in a proforma.

**Results:** The study sample was consisted of 62% men and 38% women. Mean age was  $26.9 \pm 6.64$ . The mean preoperative swelling was  $109.20 \pm 1.190$  mm in control group and  $109.44 \pm 1.083$  in DM group. After 48 hours of surgery, post extraction swelling increased in both group with mean swelling  $114.28 \pm 1.242$  mm in control group and  $114.64 \pm 1.350$  in DM group, after a week of surgery more swelling was reduced in DM group as compared to control group.

**Conclusion:** It is found that Dexamethasone group showed decrease in swelling as compared to control group.

*Keywords: Dexamethasone; impaction; third molar; corticosteroid and surgical extraction.*

## 1. INTRODUCTION

Pain less treatment and optimal quality of life is one of the important prerequisite in every surgery. Maxillofacial surgery in broad spectrum is expanding day by day with new recent advances in procedures and also in research in on different drugs to control post surgical sequel [1]. Removal of third molar is a routine surgical procedure in outpatient departments and at some point of life many people may require. The third molar teeth are last to erupt and have a comparatively high chance of becoming impacted. The removal of third molar is one of the frequently performed procedure in oral surgery.<sup>2</sup> Impacted mandibular 3<sup>rd</sup> molars are often associated with multiple pathologies like, pericoronitis, periodontitis, cystic lesions and pathologic root resorption that can cause unfavorable effects on adjacent tooth [2].

Swelling of face, pain and trismus, which are the three probable sequelae of 3<sup>rd</sup> molar impaction surgery, are unlikable and uncomfortable for the patients and should be minimized. Swelling of the local region is the most frequent usual complication and it usually occur after surgical procedure postoperatively (PO) because of tissue injuries [3-4] to minimize reducing PO discomfort is of important concern, both for patients and doctor. Well skilled surgeon, a time limited operation and by the application of cold dressings have a beneficial better effect on PO edema [5].

The application of steroid therapy to control inflammation in oral surgical procedures has been an era of argument since its inception in 1948. The effectiveness helpful use of Glucocortico-steroids as an anti-inflammatory agent was first reported by Philip Showalter Hench and Edward CK in 1949, who used cortisone to treat rheumatoid arthritis [6]. The use

of Steroids reduces the risk for physiologic processes of inflammation and discomfort. The effects of dexamethasone (DM) have been observed in several studies. DM is a long acting gluco-corticod, which is used for many inflammatory and auto immune diseases [6-7]. The use of corticosteroids (dexamethasone, betamethasone) is another precautionary strategy for limiting postoperative swelling following oral surgical procedures [7].

Dexamethasone has highest anti-inflammatory activity. Many clinical studies have shown that, the use of CSs in oral surgery contributed to reduce PO swelling. It has been found that the use of corticosteroids (CS) also contributed to better control of swelling and trismus [1,4,8]. Therefore the purpose of this study was to determine the role of DM in mandibular third molar removal and to evaluate the anti-inflammatory effects of dexamethasone.

## 2. MATERIALS AND METHODS

This cross sectional study was conducted in department of oral and maxillofacial surgery from January 2019 to March 2020. All Patients with age between 20-40yrs of either gender with impacted mandibular 3<sup>rd</sup> molars were selected. Exclusion criteria were based on selection of patients having limited mouth opening that was less than 15mm and were suffering from acute pericoronitis. The purpose, procedure and risk/benefits of the study were explained to the patients and informed consent was taken regarding their willingness and participation in the study. They were assured of maintaining confidentiality of their personal and other data collected from them. All selected patients were divided into two groups by using random number Table". Patients in Group-A were given dexamethasone 8 mg intramuscularly before surgery and 4 mg 24 hours after surgery and

Augmentin tablet 625 mg Q12 hrs and Brufen 400 mg Q8 hrs and patients in group-B were given Augmentin 625 mg Q12 hrs and Brufen 400 mg Q8 hrs post operatively only [7,8]. The facial swelling was checked before surgery, and after 24 hours (1<sup>st</sup> day), after 48 hours (2<sup>nd</sup> day) and after 7 days. The facial swelling was determined by measuring the distance in millimeters with flexible tape from the corner of the mouth to the tragus of ear and from the lateral canthus of the eye to the angle of the mandible. The sum of these measurements was recorded as the facial size pre and post operatively (Fig. 1). "All the gathered information was noted and entered in a structured proforma" (annexed).

The data were analyzed on SPSS version 16. The demographic variable like age and gender were presented as descriptive statistics. The mean and standard deviation (SD) were calculated for age". The frequency and percentage (%) of post-operative swelling was calculated of both groups.

### 3. RESULTS

A total 50 patients were enrolled in this study. There were 62% men and 38% women (Fig. 1) the mean age was 26.9 with SD 6.64, the minimum and maximum age was 20 years and 40 years respectively (Table 1).

Mesio-angular (46%) type of impaction was most common followed by disto-angular( 30%), Vertical (16%) and Horizontal (8%) (Fig. 2.). Patients undergoing surgical extraction of

mandibular third molars were divided in two groups. One group was control group and other was Dexamethasone group. The mean preoperative swelling was  $109.20 \pm 1.190$  mm in control group and  $109.44 \pm 1.083$  in Dexamethasone group. After 48 hours of surgery, post extraction swelling increased in both group with mean swelling  $114.28 \pm 1.242$  mm in control group and  $114.64 \pm 1.350$  in Dexamethasone group, after a week of surgery more swelling was reduced in Dexamethasone group as compared to control group (Table 2).

### 4. DISCUSSION

Most frequent procedures in Oral and Maxillofacial Surgery is the surgical removal of impacted molars which can lead to instant PO pain, swelling and limited mouth opening [9]. The side effects are manifestations of the body's natural response to surgical insult. Preoperative administration of systemic Corticosteroids (CS) is a pharmacologic approach used commonly to reduce postoperative morbidity after surgery by inhibiting, through a variety of proposed mechanisms, the body's inflammatory response to injury [10]. "Considering that pain, swelling, and trismus are always expected after molar surgery, these patients present an ideal clinical experimental model to study these sequelae and the potential therapeutic effects of anti-inflammatory drugs". However, because clinicians tend to stress such complications when preparing informed consent or the sheets with PO instructions, patients seem to focus more attention on function(ie, chewing, swallowing, and eating) [11].

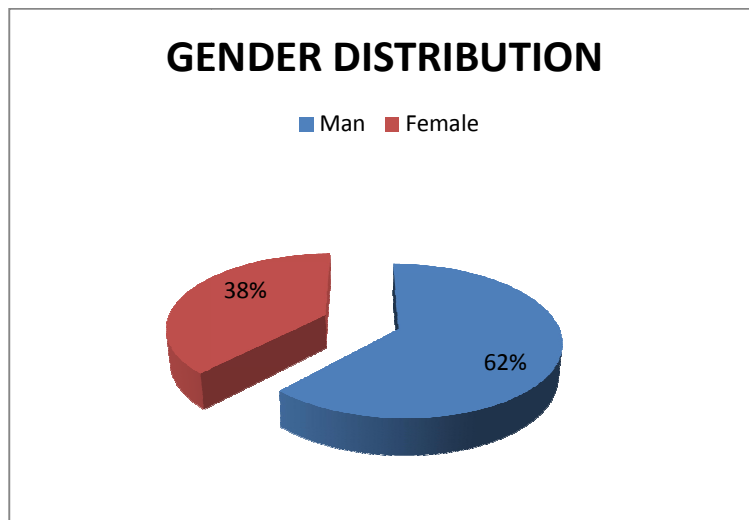
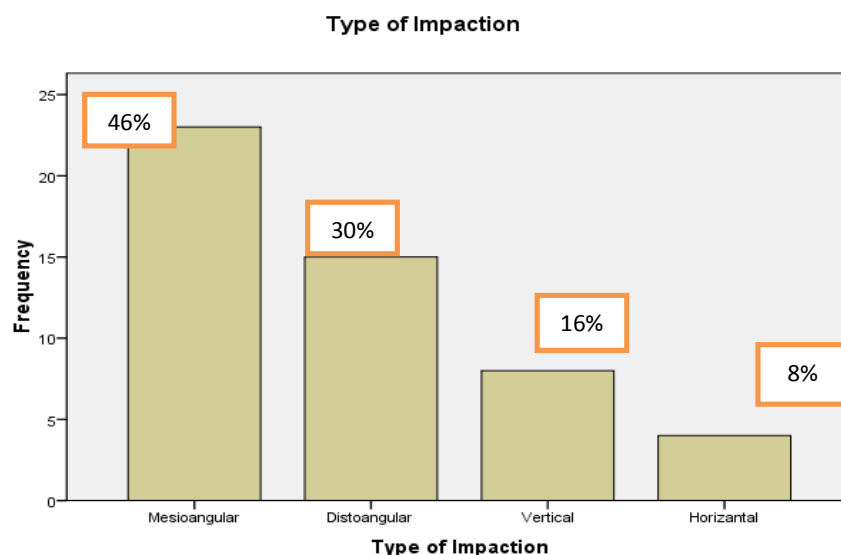


Fig. 1. Gender distribution of participants of the study

**Table 1. Age of patients in years**

<b>Mean</b>	<b>26.92</b>
Std. Error of Mean	.940
Std. Deviation	6.645
Range	20
Minimum	20
Maximum	40



**Fig. 2. Type of impactions**

**Table 2. Comparison of swelling before and after surgery**

Swelling	Control group (mm)	Standard deviation	Dexamethasone (mm)	Standard deviation
Before Surgery	109.20	1.190	109.44	1.083
After 24 hours post-surgery	109.68	1.145	110.04	0.889
After 48 hours post- surgery	114.28	1.242	114.64	1.350
After a week post- surgery	110.60	1.354	108.88	1.092

“Therefore, studies evaluating the effect of third molar surgery or perioperative medications on patients’ Quality of Life (QOL) and correlating the effect with objectively measured sequelae are becoming more important to offer patients the optimal management”. In this trial male participants were more than fifty percent which is in accordance with the study of Channar KA [9] in 2014, and Rajper [5] in 2020 “Stratified analyses by gender were not carried out due to the unavailability of enough individual patient data. None of the individual trials, however, suggested that there might be a gender-dependent effect of CS”. In this study mean age was 26.9 which is in close approximate with the

study results of Bui CH [12] where average age of participants was 24.4 years. “At this age range, the roots of 3<sup>rd</sup> molar (M3s) are completely formed in most of the population”. “Teeth with fully formed roots are more difficult to extract than those with partially formed or no roots, requiring a more invasive surgery than with younger patients [12]. Mesio-angular impaction (46%) followed by disto-angular (30%) was the common type of impaction in this trial. Our findings confirmed with the previous studies conducted by Ishfaq et al. [13], Bui et al. [12], Gbotolorun et al. [14], Quek et al. [15], Unwerawattana [16], where the common type was mesioangular impactions. However, a study among Jordanians found that vertical impactions

were the most common (61.4%) and mesio-angular were only 18% [17].

Similarly, another study in Barcelona has also reported that vertical impactions were the common type followed by mesioangular [18]. It seems that mesio-angular impactions are indubitably the commonest type and this may be due to path of eruption and lack of space in mandible at later age". "Decrease in mouth opening is an outcome of the postoperative swelling, and causing compression on nerves and leads to mild to severe pain [19].

Dexamethasone was chosen for the study because perioperative use of corticosteroids is a pharmacological approach often used for reduction of edema, trismus, and pain after removal of impacted mandibular third molars, and it has shown to be a drug of safe management, if time and dosages are strictly followed [20]. The employed analgesic was Ibuprofen, also a proven drug of safe management. Trismus, measured in this study as a decrease in maximal inter-incisal opening, is a significant postoperative sequelae caused by the edema and swelling associated with the surgical trauma [20]. Limitation of maximal mouth opening after surgery is also due, at least in part, associated with pain. In our study, Ibuprofen alone was found to provide a minor reduction of post-operative trismus, may be acting primarily by reducing patient discomfort upon opening". Although the therapeutic advantage of corticosteroid use is primarily in decreasing postoperative swelling, they have been shown to provide some pain relief [21]. The time course for trismus and concurrent limitations in oral function described in the current study are in agreement with findings of a recent large multicenter trial that indicated symptoms reach a maximum at day 1 or day 2 postoperatively and generally resolve by day 7 [22]. They determined predictor factors for less favorable and more prolonged post-operative outcomes to comprise older age, female gender, both lower third molars requiring bone removal, and longer procedures [1,3]. Our findings that trismus and PO pain are minimized with the use of Ibuprofen and dexamethasone might be most beneficial when prolonged recovery is expected". Srivastava [1] and Channar I. [9] reported that swelling was less with the glucocorticoid administration through post-surgery day three. Future studies are needed to determine the optimal dose, timing, and duration of CS therapy and the role of CS therapy compared with NSAIDs.

## 5. CONCLUSION

It is concluded that the pre-operative administration of CS for patients undergoing mandibular impaction removal has a mild to moderate effect in reducing inflammatory symptoms up to 7 days post-surgery and overall more swelling was reduced in DM group as compared to control group.

## ETHICAL APPROVAL

As per international standard or university standard written ethical approval has been collected and preserved by the authors.

## COMPETING INTERESTS

Authors have declared that no competing interests exist.

## REFERENCES

1. Srivastava N, Shetty A, Kumar P, Rishi D, Bagga V, Kale SG. Comparison of preemptive effect of dexamethasone and methylprednisolone after third molar surgery: A split-mouth randomized triple-blind clinical trial. *Journal of Maxillofacial and Oral Surgery*. 2020;11:1-7.
2. Channar KA, Tareen MK, Hamad J, Warraich RA. Role of antibiotics in surgical removal of asymptomatic mandibular third molar impaction. *J Liaquat Uni Med Health Sci*. 2014;13(03):112-5.
3. Almendros-Marques N, Berini-Aytes L, Gay-Escoda C. Influence of lower third molar position on the incidence of preoperative complications. *Oral Surg Oral Med Oral Pathol Oral Radiol Endod*. 2006;102:725.
4. Zandi. Comparison of corticosteroids and rubber drain for reduction of sequelae after third molar surgery. *J Oral Maxillofac Surg*. 2008;12:29-33.
5. Rajper WA, Channar KA, Larik MD, Majeedano SA, Soomro AA, Hussain A. Comparison of postoperative complications after impacted mandibular third molar extraction with conventional suturing versus tube drainage. *Professional Med J*. 2020;27(7):1408-13.
6. Bamgbose BO, Akinwande JA, Adeyemo WL, Ladeinde AL, Arotiba GT, MO Ogunlewe. MO prospective randomized, open label, pilot clinical trial comparing the effects of dexamethasone co-administered with dilofenac potassium or

- acetomenaphen & diclofenac potassium monotherapy After third molar extraction in adults. *Jr of Oral and Maxillofacial Surgery*. 2006;67:229-40.
7. Troullos ES, Hargreaves KM, Butler DP, Dionne RA. Comparison of non steroidal anti inflammatory drugs, ibuprofen and flurbiprofen with methylprednisolone and placebo for acute pain, swelling, and trismus. 2008;10:1016.
  8. Bamgbose BO, Akinwande JA, Adeyemo WL, Ladeinde AL, Arotiba GT, MO Ogunlewe MO. Effects of coadministered dexamethasone and diclofenac potassium on pain, swelling and trismus following third molar surgery. *Jr Head and face. Medicine Bio Medical Central*. 2005;1-6.
  9. Channar KA, Kumar NUI, Hassan QA, Memon AB. Dexamethasone in control of post-operative sequelae after extraction of mandibular impacted third molars. *Medical Channel*. 2013;19(2):1.
  10. Herrera-Briones FJ, Prados Sánchez E, Reyes Botella C, Vallecillo Capilla M. Update on the use of corticosteroids in third molar surgery: systematic review of the literature. *Oral Surg Oral Med Oral Pathol Oral Radiol*. 2013;116(5):342-51.
  11. Valderas JM, Alonso J. Patient reported outcome measures: A model-based classification system for research and clinical practice. *Qual Life Res*. 2008;17:1125.
  12. Bui CH, Seldin EB, Dodson TB. Types, frequencies and risk factors for complications after third molar extraction. *J Oral Maxillofac Surg*. 2003;61:1379-89.
  13. Ishfaq M, Wahid A, Rahim AU, Munim A. Patterns and presentation of impacted mandibular third molars subjected to removal at khyber college of dentistry peshawar. *Pak Oral Dent J*. 2006;26:221-26.
  14. Gbotolorun OM, Olojede AC, Arotiba GT, Ladeinde AL, Akinwande JA, Bambose BO. Impacted mandibular third molars: presentation and postoperative complications at the Lagos university teaching hospital. *Nig QJ Hosp Med*. 2007;17:26-29.
  15. Quek SL, Tay CK, Tay KH, Toh SL, Lim KC. Pattern of third molar impaction in a singapore chinese population: A retrospective radiographic survey. *Int J Oral Maxillofac Surg*. 2003;32: 548-52.
  16. Unwerawattana W. Common symptoms and type of impacted molar tooth in king chulalongkorn memorial hospital. *J Med Assoc Thai*. 2006;89:134-39.
  17. Bataineh AB, Albashaireh ZS, Hazza'a AM. The surgical removal of mandibular third molars: A study in decision making. *Quintessence Int*. 2002;33:613-17.
  18. Almendros-Marques N, Berini-Ayres L, Gay-Escoda C. Influence of lower third molar position on the incidence of preoperative complications. *Oral Surg Oral Med Oral Pathol Oral Radiol Endod*. 2006;102:725-32.
  19. López-Carriches C, Martínez-González JM, Donado-Rodríguez, M. Analgesic. Efficacy of diclofenac versus methylprednisolone in the control of postoperative pain after surgical removal of lower third molars. *Med Oral Patol Oral Cir Bucal*. 2005;10(5):432-9.
  20. Filho JRL, Maurette PE, Allais M, Cotinho M, Fernandes C. Clinical comparative study of the effectiveness of two dosages of dexamethasone to control post operative swelling, trismus and pain after the surgical extraction of mandibular impacted third molars. *Med Oral Pathol Oral Cir Bucal*. 2008;13(2):129-32.
  21. Graziani F, D'Aiuto F, Arduino PG, Tonelli M, Gabriele M. Perioperative dexamethasone reduces post-surgical sequelae of wisdom tooth removal. A split-mouth randomized double-masked clinical trial. *Int J Oral Maxillofac Surg*. 2006; 35(3):241-6.
  22. Phillips C. Recovery after third molar surgery: Clinical and health related quality of life outcomes. *J Oral Maxillofac Surg*. 2003;61(5):535-44.

© 2020 Shaikh et al.; This is an Open Access article distributed under the terms of the Creative Commons Attribution License (<http://creativecommons.org/licenses/by/4.0>), which permits unrestricted use, distribution, and reproduction in any medium, provided the original work is properly cited.

*Peer-review history:*  
The peer review history for this paper can be accessed here:  
<http://www.sdiarticle4.com/review-history/64698>