

Mucosal Melanoma of the Sino-nasal Tract - A Rare Case Report

Vinita Trivedi¹, Syeda Naseera^{1*}, Manashi Ghosh¹, Richa Chauhan¹,
A. Muneer¹ and Kaustav Mandal¹

¹Department of Radiation Oncology, Mahavir Cancer Sansthan, Patna, Bihar, India.

Authors' contributions

The authors have contributed in designing, analyzing, interpretation and in preparing the manuscript.

Article Information

DOI: 10.9734/JCTI/2017/32167

Editor(s):

(1) Rafael Roesler, Cancer Research Laboratory, University Hospital Research Center, Federal University of Rio Grande do Sul, Brazil.

Reviewers:

(1) Priyanka Agarwal, Maharashtra University of Health Sciences, India.
(2) Bharat Bhushan Dogra, Dr. D Y Patil Medical College & Hospital Pimpri, Pune, India.
Complete Peer review History: <http://www.sciencedomain.org/review-history/18400>

Case Study

Received 11th February 2017
Accepted 15th March 2017
Published 29th March 2017

ABSTRACT

Sino nasal malignant melanoma is a very aggressive and rare neoplasm of the head and neck region. Less than 2% of all mucosal melanomas originate from the sino-nasal region demanding a high index of suspicion to diagnose these tumours. The patients developing sino-nasal melanomas are usually in their sixties and seventies. These patients often present in an advanced stage due to its nature of rapid progression associated with non-specific symptoms. The present case report highlights a rare case of malignant melanoma of the maxillary sinus, involving orbit in a 56 years old male patient.

Keywords: Mucosal melanoma; sino-nasal; aggressive; adjuvant; radiotherapy.

1. INTRODUCTION

Mucosal malignant melanomas arising in the nasal cavity and paranasal sinuses account for 0.3 to 2% of all melanomas and approximately 4% of all head and neck melanomas [1]. The

rarity of the tumour makes it difficult to diagnose and is often mistaken for the more common carcinomas of the sino-nasal region, other differential diagnosis being sarcoma, lymphoma and neuroblastoma. Sinonasal melanomas are highly aggressive tumours. To reflect this

*Corresponding author: Email: naseersyeda@gmail.com

aggressive behavior, the primary cancers limited to mucosa are directly considered of T3 stage according to 8th edition of American Joint Committee on Cancer [2]. By the time, the diagnosis is made, the disease will be usually in a locally advanced stage, eroding the bony wall and involving the adjacent structures like the oral cavity, palate, orbit, infra-temporal fossa, skull base and even brain. Therefore, there will be less scope left for curative approaches. However, conventionally, complete surgical excision with adequate negative margins is the treatment of choice. In cases with incomplete excision or positive margins, post operative adjuvant radiotherapy is recommended. Overall, the disease has a poor prognosis and the 5 year survival ranges from 20 to 40% [3,4].

2. CASE REPORT

A 56 years old male patient presented with complaint of watery discharge from the right eye associated with conjunctival congestion since 15 days. It was associated with headache and decreased visual acuity. He took some symptomatic medication from the ophthalmologist but was not relieved of his symptoms. Rather, the symptoms progressed in the next 10 days with swelling in the right cheek and right eye proptosis. It was associated with epistaxis, nasal obstruction, and decreased olfaction.

Patient is a non-smoker, non-alcoholic, vegetarian and gave no significant occupational history or exposure to any irritant substances. Upon examination there was severely proptotic right eye associated with chemosis, narrowing of the palpebral fissure, and right total ophthalmoplegia. Nasal cavity was filled with blackish mass with blood stained discharge. The right cheek was swollen and inflamed with a foul smelling discharging sinus.

No neck nodes were palpable and ear and oral examination were normal. Apart from the above findings, the rest of the systemic examination was normal. Routine investigations that were done included complete blood picture, liver and renal function tests, random blood sugar and were all within normal limits.

Biopsy was taken from the black mass seen through the right nasal cavity that showed melanoma. Immunohistochemically, the tumour stained positive for HMB-45 and S-100 that confirmed our diagnosis.

Metastatic workup was done for the patient. Findings of CT scan of para nasal sinus showed 6.5x4.3x4.7 cm lesion causing lytic destruction of the right lamina papyracea and floor of the right orbit and extending into the intraconal compartment and reaching upto posterosuperior and lateral aspect of the globe. A FDG-PET CT SCAN was done which correlates with the CT findings and there was normal distribution of radiotracer in the rest of head and neck region, chest, abdomen, genito-urinary system and musculoskeletal system without any focal areas of abnormal metabolism.

The patient was planned for surgery and "right total maxillectomy with right orbital exenteration and disease clearance from the sphenoid and frontal sinuses were performed by the surgeon. Due to proximity to vital structures, a residual disease was left over the right ICA region and over the optic sheath. The histo pathological report showed a blackish brown tumour of size 5.5 x 5.0 x 4.5 cm. section showed a tumour comprising of moderately pleomorphic round polygonal cells arranged in nested pattern with intervening fibrovascular septa. The individual cells have moderate amount of eosinophilic and vacuolated cytoplasm with enlarged nucleus, and prominent eosinophilic nucleolus. Majority of cells showed abundant melanin pigment in their cytoplasm. Antero-medial soft tissue margin, posterior soft tissue margin and medial skin margin are involved by tumour. In view of positive margins, the patient was planned for post operative radiotherapy, 50Gy/20 # @ 2.5GY/# using conformal radiotherapy technique. On first follow up after 6 weeks, the patient was asymptomatic and the disease was loco-regionally controlled. He turned up after 2 months with symptoms of nausea and abdominal discomfort. CECT whole abdomen showed multiple liver metastasis which was histologically proven. Now he is on systemic chemotherapy.

3. DISCUSSION

A primary sino-nasal malignant melanoma is very rare and usually a lethal disease. Overall incidence of the disease is 0.6 to 3.8% accounting for less than 1% of all malignant melanomas [5]. Because of its rarity, sino-nasal mucosal melanoma is poorly understood, characterized and studied. Among the head and neck anatomical location, sinonasal tract is a common primary site for mucosal melanomas [6]. In consequence of their hidden location, mucosal melanomas are usually diagnosed in a loco-

regionally advanced clinical stage, with a rate of 5 -48% regional and 4-14% distant dissemination [7]. Unlike its cutaneous counterpart exposure to sunlight is not an etiological factor for sino-nasal malignant melanoma. Although irritants like tobacco smoking have been implicated, their potential role is still unclear.

Melanomas arise from the aberrant melanocytes of the respective sites. In the nasal cavity, they can be found in the respiratory epithelium, nasal glands, nasal septum, middle and inferior turbinates etc as mentioned in a study by Zak FG et al. [8]. In physiological state, the melanocytes in the mucosa do not produce any melanin, and only contain non-melanised melanosomes. However, they produce substantial amounts of melanin in pathological conditions like Addisons disease and neoplasm [9].

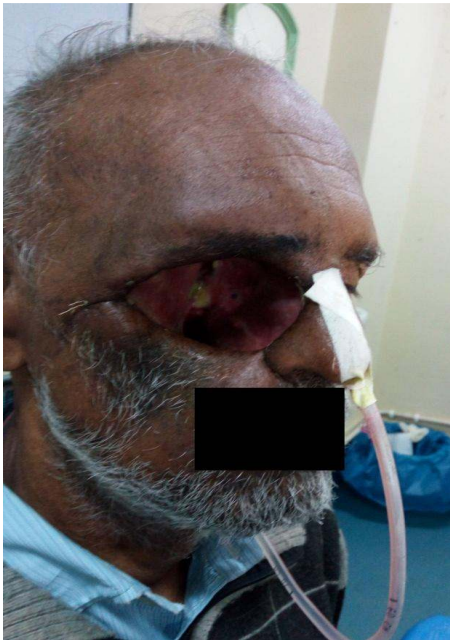

Fig. 1. Post operative photograph of the patient

Sinonasal mucosal melanoma is usually a disease of the elderly, commonly occurring in the seventh decade of life with no sex predilection. Race is an important entity determining the prevalence of mucosal melanomas. 10% of all the melanomas in the Ugandan population are located in the oral or nasal cavity and are mucosal in origin. In Japan, oral cavity mucosal melanomas are relatively common. The reported cases from India account only in numbers as its occurrence in the Indian sub-continent is extremely rare [10].

As was seen in our case, the patients usually present in a locally advanced stage T4a/T4b. The early non-specific symptoms of nasal obstruction, epistaxis, headache, epiphora, conjunctival congestion and chemosis etc are often misdiagnosed for the more common benign conditions like infections, nasal polyp etc. Due to its intrinsic aggressiveness, the features like proptosis, and Sino-cutaneous fistula soon follow the innocuous symptoms. Pain is a less common feature of sino-nasal melanoma. Only in 6% of the cases, swelling of the nose or an actual mass is visible at the vestibule [11].

Unless it is amelanotic as is seen in 10% cases, most of the sino-nasal melanomas are grossly blackish brown to pink in colour, commonly friable, polypoidal in character. Microscopically it shows small rounded or polygonal tumour cells arranged pattern or in lobules. Melanin pigment is found in 70-90% of cells, unless amelanotic. The immune-histochemistry shall confirm the absence of the other commonly occurring carcinoma, angiocentric T cell/killer cell lymphoma. All melanomas be it cutaneous or mucosal react strongly with the α -subunit of S-100, which is a calcium binding protein found in the neural tissues. The frequency of S-100 immuno-reactivity varies from 86-100%. A reactive antigen more specific to melanoma cells is HMB -45 (melanoma cytoplasmic antigen). The diagnostic workup includes complete head and neck examination, imaging of the face and neck in the form of CT scan or MRI. Chest and abdominal imaging or ideally PET CT may be done in all cases of stage IV disease to rule out the possibility of early metastasis.

The conventionally followed treatment of choice for sino-nasal melanoma is complete surgical excision with negative margins. Surgery provides the best chance of controlling the disease [12]. However in many cases the anatomical complexity, limited surgical visualization and proximity to vital structures makes the complete excision with negative margins impossible. Therefore, adjuvant radiotherapy is recommended in all such cases of incomplete resection [13]. According to a study done by Kingdom and Kaplan, post operative radiotherapy appears to have an increase in the disease free intervals and prolonged survival as well. The result of adjuvant radiotherapy will be less favourable if the patient has regional nodal invasion or early distant metastasis at the time of presentation [14].

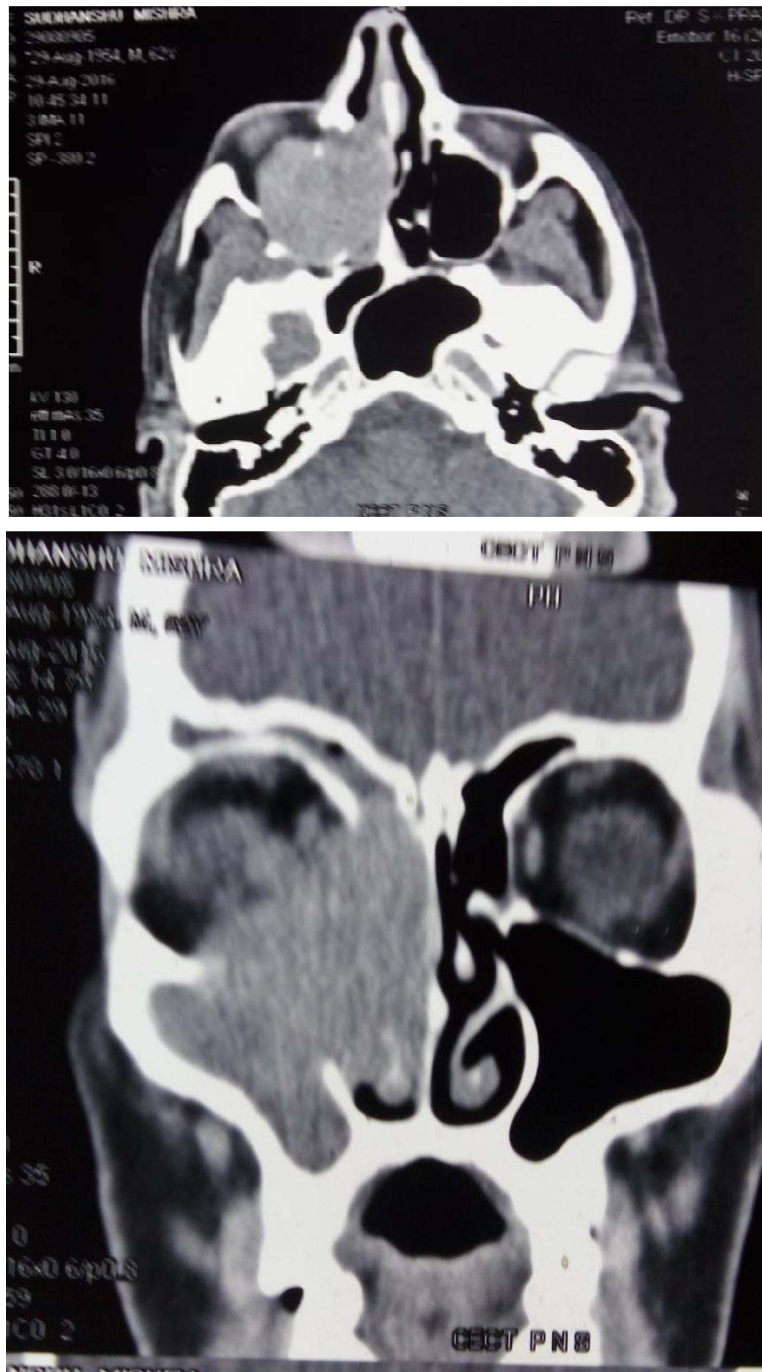


Fig. 2 & 3. Showing pre-operative CT images of the patient

Triple therapy with surgery followed by adjuvant radiotherapy and chemo-immunotherapy were also tried in many cases and the reported studies suggested modest increase in the local control and overall survival [15,16]. The most frequently used chemotherapeutic agents include Dacarbazine and Platinum analogues.

Immunotherapy is effective only in small percentage of patients and increased response rate has been observed when IL-2 and Interferon- α are combined with cisplatin [17].

Compared to skin melanomas, the mucosal melanomas have a lower prevalence of regional

lymphnode invasion, both at presentation and at recurrence. Oral cavity melanomas have higher incidence in lymphnode involvement than the sino-nasal ones. However, frequent recurrences and tendency for early hematogenous metastases despite radical surgery contribute to the grave prognosis of sino-nasal malignant melanomas [18,19]. The occurrence of local recurrence is seen in 31-

85%, as according to many studies. The lung, liver, bone and brain are the most common sites of metastasis [20]. Patients with surgery has better 3-year and 5-year OS rates than those who are treated without surgery (40.7% and 34.1% vs 21.4% and 14.3%, respectively). Patients who presents with metastasis at presentation is associated with worse prognosis [3,4].

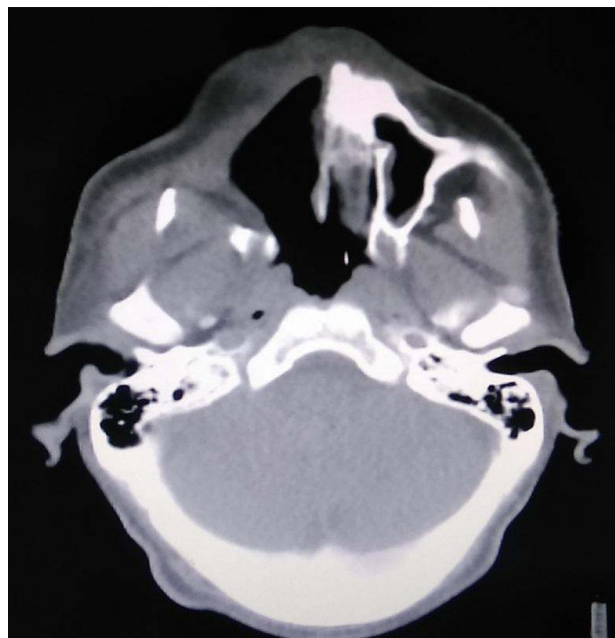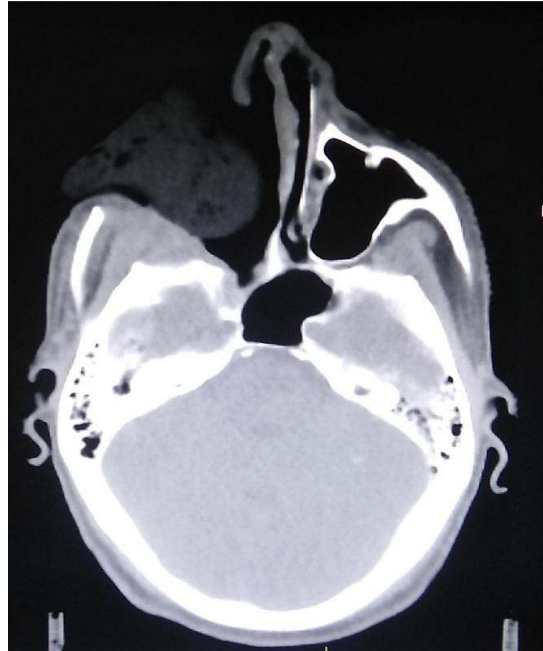


Fig. 4 & 5. Showing post-operative CT images with tissue equivalent prosthesis *in situ*

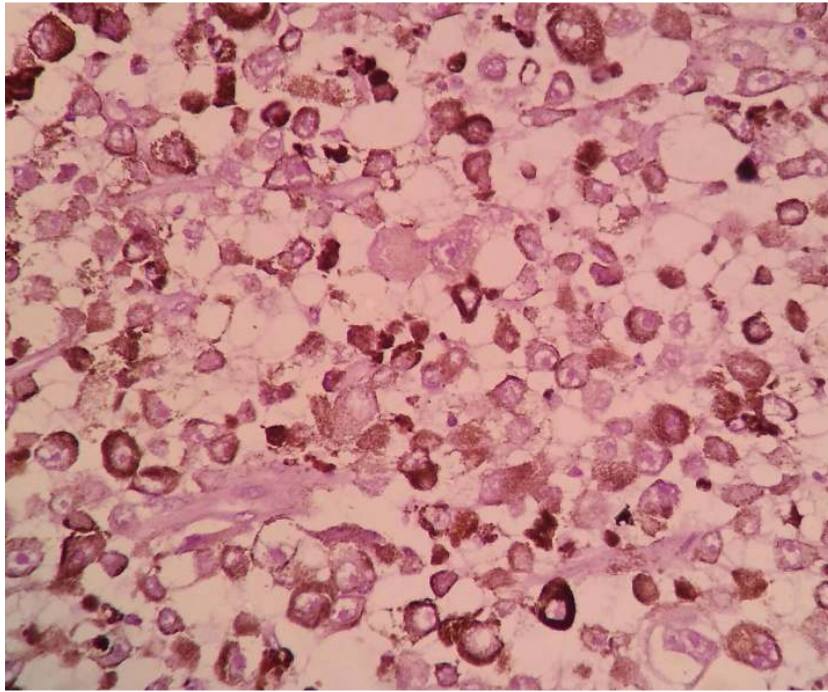


Fig. 6. Showing H&E x40, postoperative biopsy specimen

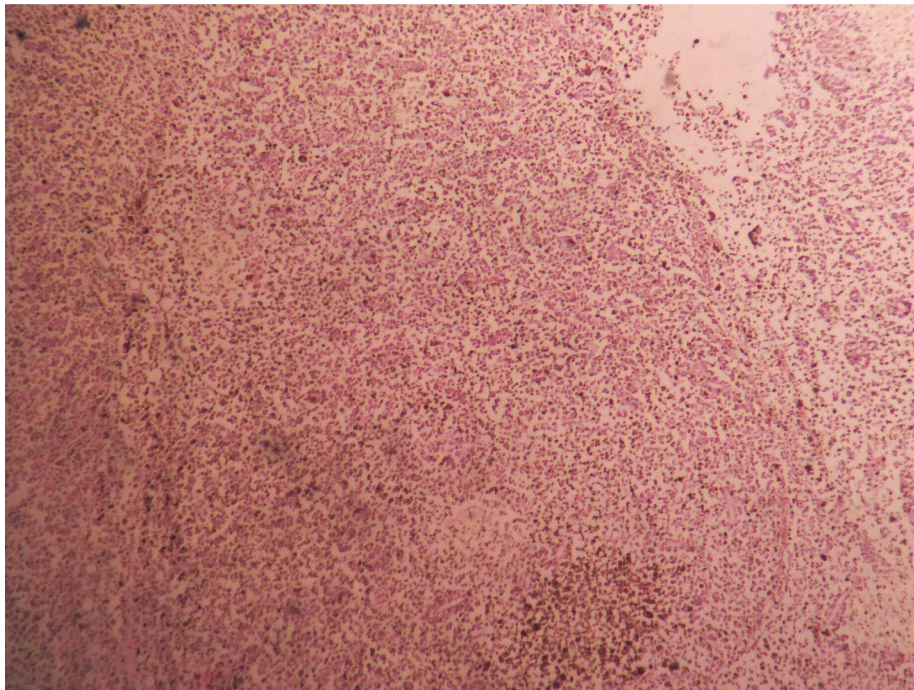


Fig. 7. Showing H&E x10, postoperative biopsy specimen

According to a study at Memorial Sloan Kettering cancer centre, clinical stage at presentation, tumour thickness >5 mm, vascular invasion on histological studies and development of distant metastasis are the only independent predictors of outcome in

mucosal melanomas of the head and neck region [21].

4. CONCLUSION

Sino-nasal mucosal melanoma is an unusual clinical entity. Favourable outcome, though less often possible can be expected only in cases of early detection and prompt surgical excision followed by adjuvant Radiotherapy.

However, despite aggressive therapy, the prognosis in these patients is usually grim with a morality rate more than 50%. Surgery remains the main stay of treatment although the role of adjuvant radiotherapy and chemotherapy is on its pace. A clearer understanding of the biology of the disease may help standardize the treatment modalities and inturn improve the outcome.

CONSENT

As per international standard or university standard, patient's written consent has been collected and preserved by the author.

ETHICAL APPROVAL

Ethical committee approval has been taken.

COMPETING INTERESTS

Authors have declared that no competing interests exist.

REFERENCES

1. Lund VJ, Stammberger H, Nicolai P, Castelnuovo P, Beal T, Beham A, Bernal-Sprekelsen M, Braun H, Cappabianca P, Carrau R, Cavallo L. European position paper on endoscopic management of tumours of the nose, paranasal sinuses and skull base. *Rhinology. Supplement.* 2009;22:1-43.
2. AJCC. 8th edition
3. Sun CZ, Li QL, Hu ZD, Jiang YE, Song M, Yang AK. Treatment and prognosis in sinonasal mucosal melanoma: A retrospective analysis of 65 patients from a single cancer center. *Head Neck.* 2014; 36:675–681.
DOI: 10.1002/hed.23355
[PubMed]
4. Jangard M, Hansson J, Ragnarsson-Olding B. Primary sinonasal malignant melanoma: A nationwide study of the Swedish population, 1960–2000. *Rhinology.* 2013;51:22–30.
[PubMed]
5. Chang AE, Karnell LH, Menck HR. The National cancer data base report on cutaneous and noncutaneous melanoma: A summary of 84,836 cases from the past decade. The American College of Surgeons Commission on Cancer and the American Cancer Society. *Cancer.* 1998; 83:1664-78.
6. Mendenhall WM, Amdur RJ, Hinerman RW, Werning JW, Villaret DB, Mendenhall NP. Head and neck mucosal melanoma. *Am J Clin Oncol.* 2005;28:626-30.
7. Gilligan D, Slevin NJ. Radical radiotherapy for 28 cases of mucosal melanoma in the nasal cavity and sinuses. *Br J Radiol.* 1991;64(768):1147-50.
8. Zak FG, Lawson W. The presence of melanocytes in the nasal cavity. *Ann Otol Rhinol Laryngol.* 1974;83:515–9.
9. Warszawik-Hendzel O, Slowinska M, Olszewska M, Rudnicka L. Melanoma of the oral cavity: Pathogenesis, dermoscopy, clinical features, staging and management. *J Dermatol Case Rep.* 2014;8(3):60-6.
10. Dwivedi R, Samanta N, Agarwal S. Primary malignant melanoma of the nasal cavity and paranasal sinuses: A rare cause of epistaxis in the elderly. *Int J Head Neck Surg.* 2007;2(1).
11. Batsakis JG, Regezi JA, Solomon AR, et al. The pathology of head and neck tumors: Mucosal melanomas. *Head Neck Surg.* 1982;4:404–418.
DOI: 10.1002/hed.2890040509
[PubMed]
12. Jayaraj SM, Hern JD, Mochloulis G, Porter GC. Malignant melanoma arising in the frontal sinuses. *J Laryngol Otol.* 1997; 111:376-8.
13. Berthelsen A, Andersen AP, Jensen S, Hansen HS. Melanomas of the mucosa in the oral cavity and the upper respiratory passages. *Cancer.* 1984;54:907-12.
14. Kingdom TT, Kaplan MJ. Mucosal melanoma of the nasal cavity and paranasal sinuses. *Head Neck.* 1995; 17:184–189.
DOI: 10.1002/hed.2880170303
[PubMed]
15. Owens JM, Roberts DB, Myers JN. The role of postoperative adjuvant radiation therapy in the treatment of mucosal

- melanomas of the head and neck region. Arch Otolaryngol. 2003;129:864–868. DOI: 10.1001/archotol.129.8.864 [PubMed]
16. Temam S, Mamelie G, Marandas P, Wibault P, Avril MF, Janot F, Julieron M, Schwaab G, Luboinski B. Postoperative radiotherapy for primary mucosal melanoma of the head and neck. Cancer. 2005;103:313–319. DOI: 10.1002/cncr.20775 [PubMed]
17. Saida T, Kawachi S, Takata M, et al. Histopathological characteristics of malignant melanoma affecting mucous membranes: A unifying concept of histogenesis. Pathology. 2004;36(5):404-13. [Medline]
18. Vandenhende C, Leroy X, Chevalier D, Mortuaire G. Sinonasal mucosal melanoma: Retrospective survival study of 25 patients. J Laryngol Otol. 2012; 126:147–151. DOI: 10.1017/S0022215111002519 [PubMed]
19. Huang SF, Liao CT, Kan CR, Chen IH. Primary mucosal melanoma of the nasal cavity and paranasal sinuses: 12 years of experience. J Otolaryngol. 2007;36:124–129. DOI: 10.2310/7070.2007.0010 [PubMed]
20. Sanderson AR, Gaylis B. Malignant melanoma of the sinonasal mucosa: Two case reports and review. ENT- Ear, Nose & Throat Journal. 2007;86:287-290.
21. Patel SG, Prasad ML, Escrig M, et al. Primary mucosal malignant melanoma of the head and neck. Head Neck. 2002; 24(3):247-57. [Medline]

© 2017 Trivedi et al.; This is an Open Access article distributed under the terms of the Creative Commons Attribution License (<http://creativecommons.org/licenses/by/4.0>), which permits unrestricted use, distribution, and reproduction in any medium, provided the original work is properly cited.

Peer-review history:
The peer review history for this paper can be accessed here:
<http://sciencedomain.org/review-history/18400>