



## **Histomorphological Characteristics and Distribution of Prostatic Carcinoma Foci Using Multiple Site-Specific Labelled Core Biopsies in a tertiary Hospital in Southwestern Nigeria**

**S. A. Omenai<sup>1</sup>, I. M. Mashor<sup>2</sup>, I. N. C. Chibuzo<sup>3</sup>, S. Adebayo<sup>4</sup>, O. B. Shittu<sup>4</sup> and J. O. Ogunbiyi<sup>5\*</sup>**

<sup>1</sup>Department of Anatomical Pathology, Edo State University Uzairue, Nigeria.

<sup>2</sup>Department of Morbid Anatomy, Bingham University Teaching Hospital, Nigeria.

<sup>3</sup>Department of Urology, Stepping Hill Hospital, UK.

<sup>4</sup>Department of Surgery, College of Medicine, University of Ibadan, Nigeria.

<sup>5</sup>Department of Pathology, College of Medicine, University of Ibadan, Nigeria.

### **Authors' contributions**

*This work was carried out in collaboration among all authors. Authors SAO and INCC designed the study and performed the statistical analysis, authors SAO and IMM wrote the protocol and wrote the first draft of the manuscript. Authors OBS, SA and INCC biopsied and managed the patients and author JOO managed the analyses of the study. Authors SAO and INCC managed the literature searches. All authors read and approved the final manuscript.*

### **Article Information**

DOI: 10.9734/JCTI/2021/v11i230147

#### Editor(s):

(1) Dr. Sung-Chul Lim, Chosun University, South Korea.

#### Reviewers:

(1) Thabish Syed, Velammal Medical College & Research Institute, India.

(2) Estabraq A. Mahmoud, Ibn Al-Haitham University, Iraq.

(3) Abeer Mahmoud Ali Ibrahim, Alexandria University, Egypt.

Complete Peer review History: <http://www.sdiarticle4.com/review-history/67571>

**Original Research Article**

**Received 22 February 2021**

**Accepted 27 April 2021**

**Published 03 May 2021**

### **ABSTRACT**

**Background and Objective:** There are many evolving prostatic biopsy sampling techniques aimed at improving diagnostic accuracy, localization, prognostication and dictating prostate cancer treatment options. This study analysed the histomorphology, spatial distribution and prognostic implications of site-specific core biopsies of the prostate gland.

**Methods:** Double-sextant prostate biopsy cores, representing the medial and lateral aspects of the left and right apices, mid-gland and bases of the glands, were microscopically examined

\*Corresponding author: Email: [f\\_ogunbiyi@yahoo.com](mailto:f_ogunbiyi@yahoo.com);

prospectively over an 18-month period. These were obtained by transrectal ultrasound guidance. H&E stained slides were examined for the presence, volume, Gleason score and ISUP grade-group of cancer.

**Results:** Ninety-one patients aged 48 to 88 years (median age 70 years) were seen. In 68.1% of cases all anatomical zones of an examined prostate gland (apices, mid-gland and bases) had cancer. Overall, the apical region of the prostate gland had cancer in 35.6% of cases, the mid-gland portion 33.8% of the time while the basal region was positive in 30.6% of the cases. Tumour was restricted to mid-gland in 5.5% of cases, the apex in 4.4%, whilst it was restricted to the base in 2.2% of the cases. At least a core from all sextant biopsy sites had cancer in 42.9% of cases. Carcinoma volume was least in basally located cancers. ISUP grade group 5 was most frequently seen and grade group 2 was the least seen.

**Conclusion:** Prostatic carcinomas in our region have poor prognostic indicators such as poor differentiation, high tumour volume, and in most cases involves biopsy cores from all anatomical zones of the prostate.

*Keywords: Prostate cancer, site distribution, labelled biopsy cores, site-specific.*

## 1. INTRODUCTION

Prostatic carcinoma is the most common cancer in men and has the highest cancer mortality rates in African men [1,2]. The majority of patients in Nigeria are reported to present with high grade tumours and a significant proportion have extra-prostatic disease [3,4]. Histological diagnosis forms the gold standard, with transrectal ultrasound (TRUS) guided biopsies being the "standard of care" [5]. To improve diagnostic yield various ultrasound guided techniques with modifications have been used in obtaining the tissue cores, including the conventional sextant biopsies, 11, 13 cores biopsies, alternate areas sextant biopsies, double sextant, saturation and 3 fan-shaped biopsies [6–9]. The American Urological Association (AUA) recommends the double sextant systematic biopsy for routine diagnostic use [8,10,11].

The prostate gland reaches the maximum adult weight of approximately 20g by age 25-30yrs. The apex of the prostate gland is at the urogenital diaphragm while the base is at the bladder neck [12]. The peripheral zone constitutes all of the apical areas of the gland, extending posteriorly near the capsule [12]. The peripheral zone is where carcinomas mainly arise from and they are usually multifocal.

In addition to higher yield and fewer false negative results following systematic double sextant biopsies, findings from these biopsies provide prognostic information, better estimation of tumour volume, prediction of the final pathological stage of prostate cancer following radical prostatectomy and prediction of the presence of multifocal tumours [13,14].

Tumour location has prognostic importance as patients with apical cancers tend to have larger and more poorly differentiated tumours with higher incidence of positive margins [15]. Cancers at the apex and base of the prostate predict extracapsular extension most likely due to weakness of the capsule due to penetration of the capsule by neurovascular bundles in these regions [16]. So, finding significant percentage of positive cores in the apex and base of the prostate is a poor prognostic indicator. The percentage of prostate cores positive in the dominant lobe (right or left depending on side with most positive cores) can predict serum PSA slightly better, compared to total percentage of prostate cores involved by cancer [17].

This study was conducted to describe the histomorphology and intraglandular distribution of prostatic carcinoma and to discuss their prognostic implications among Nigerian men as seen at the University College Hospital, Ibadan.

## 2. METHODS

This a descriptive study of the histomorphological characteristics of prostate cancer in Nigerian men. Cases reviewed were part of a multi-centre prospective study of prostate cancer genetics with ethical clearance from the institutional review board. We analysed prostate cancer cases seen from January 2017 to June 2019 in the Department of Pathology of the Hospital. TRUS guided biopsies were taken, which included targeted biopsies. 18-Gauge core biopsy needles were used to obtain 12 cores (double sextant biopsy) of tissue per case with two cores in a single cassette, taken from the medial and lateral aspects of each mapped out

region, labelled as left apex, left mid-gland, left base, right apex, right mid-gland, and right base. Data such as age and serum PSA levels were retrieved from the request cards.

Histological sections were examined and the percentage of cancer in each involved core (tumour volume) was noted. The average tumour volume was calculated by adding all the percentage scores of cancers in the involved cores and dividing the total value by the total number of biopsied cores [17,18]. The ISUP grade group, Gleason grade, Gleason score and the specific biopsy site of each of the cores involved by cancer were recorded. The laterality of cancer to either left, right, or both sides of the prostate gland was noted. We also noted the localization of the cancer to either, apex, mid portion or base of the gland. The data was entered into SPSS 23 and analysed. The frequencies, median, means, and mode were determined. The chi square test of significance was used for relationship of Gleason score and zonal distribution of positive cores. The Kruskal-Wallis H parametric test was used to test for association between percentage cancer in cores and anatomical zone of biopsies.  $P \leq 0.05$  was considered significant.

### 3. RESULTS

A total of 91 cases were diagnosed and recruited during this review period. The patients' ages ranged from 48 to 88 years with a median age of 70 years. The most common distribution was involvement of the entire anatomical zones (apices, mid-gland and bases) of glands by cancer, representing 68.1% of cases. Tumour was restricted to mid-gland in 5.5% and the apex in 4.4% of the cases whilst it was restricted to base in 2.2% of the cases (Table 1). In 86.8% of cases the cancer involved both the left and right lobes and was restricted to the right and left lobes in 7.7% and 5.5% of the cases respectively (Table 1). ISUP grade group 5 was most common followed by grade group 4 with grade group 2 being the least (Fig. 1). The mean percentage of carcinoma volume is 39.3% with the minimum core involvement being 5% and maximum involvement being 90%.

The average number of biopsy regions involved by cancer was four regions in a patient. In 42.9% (39 patients) of cases, biopsy cores from all the sextant regions examined had cancer whilst cancer was restricted to a single biopsy region in only 8.8% (8 cases) (Table 1).

The average tumour volume (ATV) was  $45.46 \pm 22.44\%$ , with 91.2% of cases having ATVs  $>10\%$  (Table 2). Prostate biopsies from the base had significantly lower percentage of cancer volume compared to biopsies from the apex and mid gland (Fig. 2). A Kruskal-Wallis H test showed that there was a statistically significant difference in the estimated cancer volume between the different anatomical zones of prostate biopsies [ $\chi^2(6) = 30.5, p < 0.001$ ]. This persisted with use of the prognostic cut-off of 50% (Table 2). Overall, the apical region of the prostate gland was positive for cancer in 35.6% of cases, the mid-gland portion was positive in 33.8% of the time while the basal region was positive in 30.6% of the time. The zonal involvement was significantly related to the Gleason score with pan-regional cancers having a higher Gleason score ( $p=0.009$ ) and ISUP ( $p=0.007$ ) (Table 2).

There was no statistical difference in the distribution of cancer within the lobes but, the left lobe had fewer cases of high-grade cancers when the cancer was localized to it (Fig. 3).

Gleason scores 6 to 10 were seen in this study with the modal score being the poorly differentiated Gleason score 9 (Fig. 4). Only 11.0% of patients had a Gleason score 6, with cancers involving variable zones or the entire gland.

The minimum serum PSA was 5 ng/ml while the highest was 22,134 ng/ml with a median of 130.5 ng/ml. More than half (55.2%) of the patients had PSA values  $\geq 100$  ng/ml. There was no statistically significant difference between the PSA values generated by cancers in different zones.

### 4. DISCUSSION

Prostate carcinoma is a common cause of cancer morbidity and mortality in elderly men and the gold standard of diagnosis is prostate biopsy with histology. Many modifications to obtaining diagnostic tissue cores have been described in order to increase yield and possibly predict prognosis [7,15,19]. Peller et al. Badalament et al. and Tombal et al. in their studies demonstrated that the number of cores positive for cancer and the Gleason score of cases were strongly predictive of pathological stage and tumour volume [20–22]. In this study, on the average, 4/6 sextant biopsy regions were positive for cancer per individual in the entire study population. Peller et al. demonstrated that

four or more positive sextant core regions with a high Gleason score were more likely to be pT3 tumours [20].

In context, we note that there was no anatomical region of the prostate that was spared of cancer in this study. This might be due to the fact that men in the study were not PSA-screened but were symptomatic for prostate cancer or had nodular prostates. We found out that in almost 70% of cases the cores were positive irrespective of where in the gland the biopsy had been obtained. Even though we had not set out

with a specific intent of using pre-published biopsy search methods, our detection of pan distribution of cancer in 68% of cases is similar to that obtained using the transperineal template-guided saturation biopsy (TTSB) technique as reported by Merrick et al. in their study on men undergoing active surveillance, with prior negative TRUS-guided prostate biopsies but who had cancer-positive cores on transperineal biopsies [23]. This observation could imply that prostatic tumours from our patients are large tumours or simple that they are multifocal tumours like most.

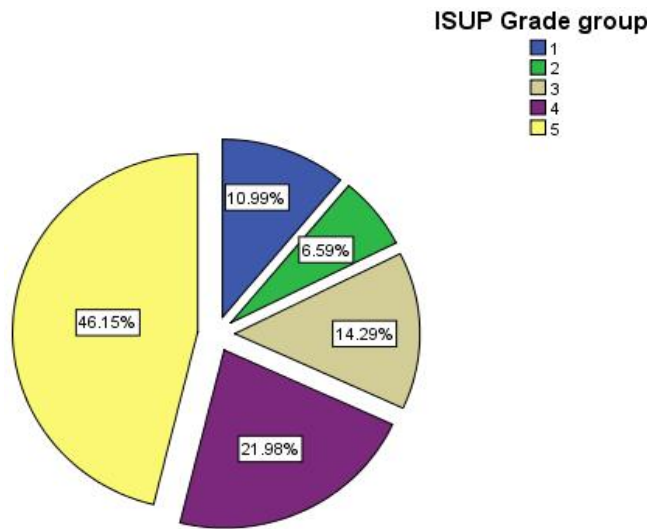


Fig. 1. Pie chart showing frequency of ISUP grade groups

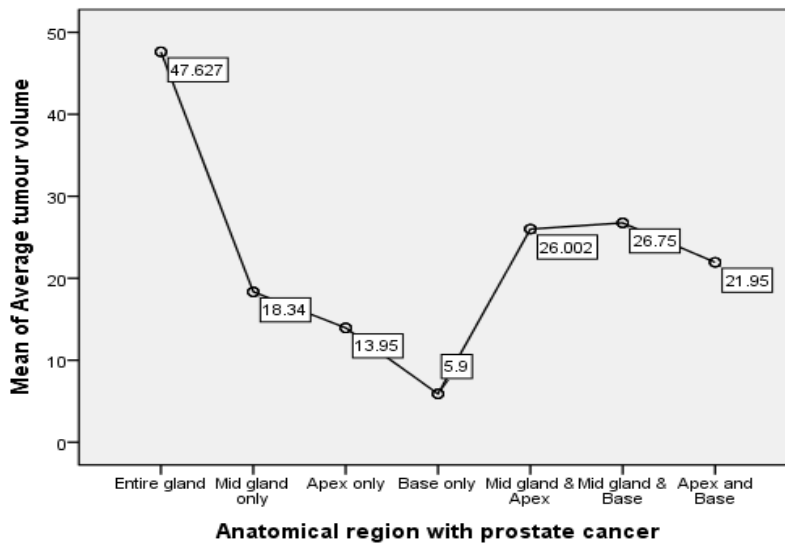


Fig. 2. Simple plot showing mean average cancer volume by anatomical region of prostate cancer

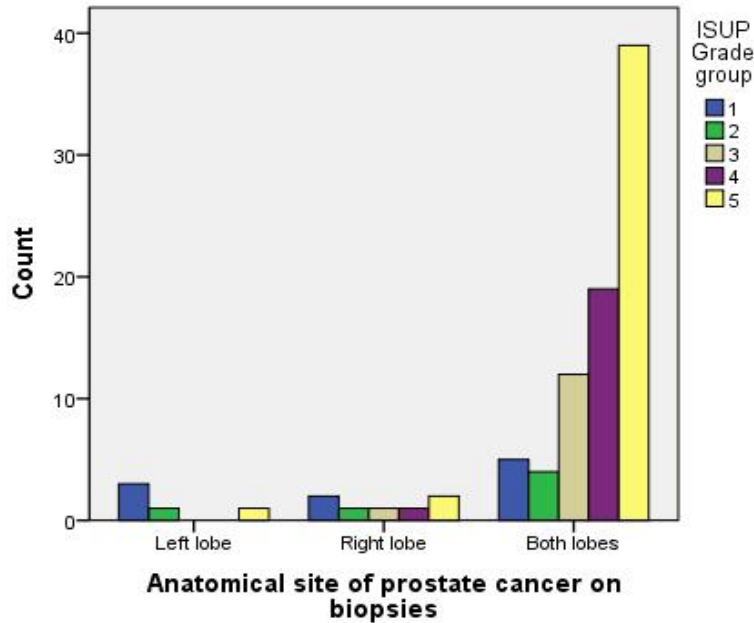


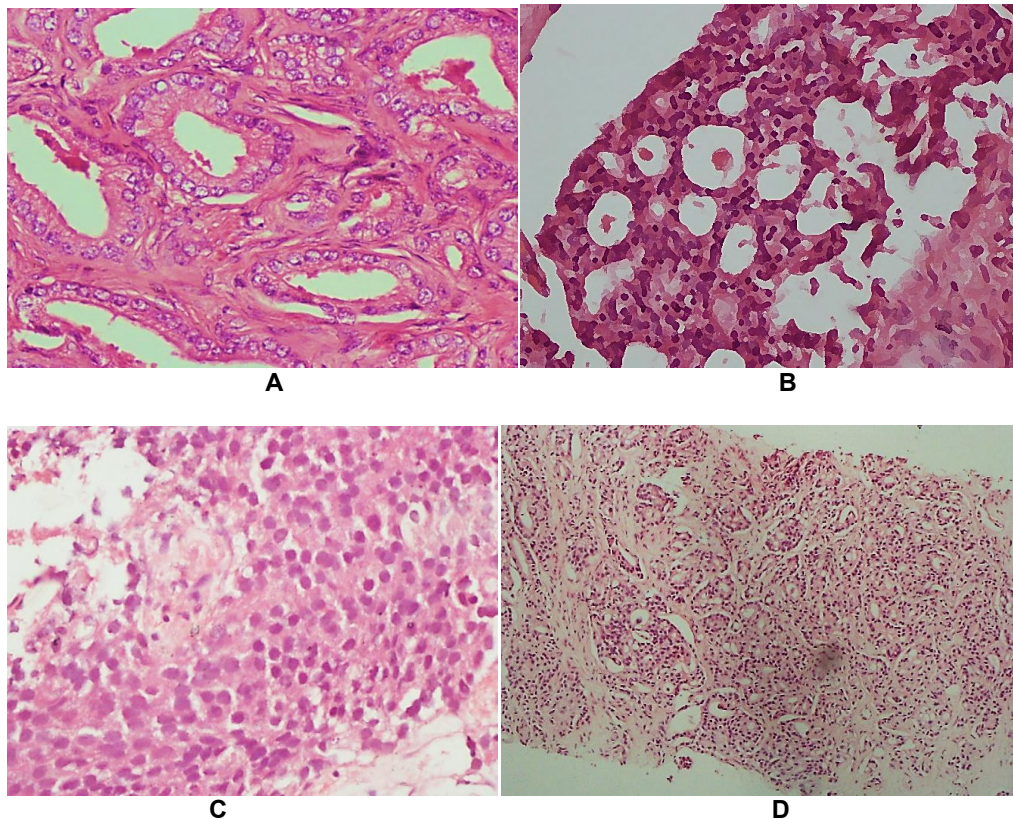
Fig. 3. Bar chart showing distribution of ISUP grade group within the prostate lobe

Table 1. Table showing frequency of some variables

Variable	Frequency of cases (n)	Percentage (%)
<b>1. Double Sextant biopsy region involved by cancer.</b>		
Left Apex (LA)	70	76.9
Left Mid (LM)	69	75.8
Left Base (LB)	58	63.7
Right Apex (RA)	72	79.1
Right Mid (RM)	66	72.5
Right Base (RB)	64	70.3
<b>2. Anatomical zones of prostate gland involved by cancer</b>		
Apical, mid and base	62	68.1
Mid-gland and Apex	9	9.9
Base and Apex	5	5.5
Mid-gland and Base	4	4.4
Mid-gland only	5	5.5
Apex only	4	4.4
Base only	2	2.2
<b>3. Biopsy Lobes involved by cancer.</b>		
Both lobes	79	86.8
Right lobe alone	7	7.7
Left lobe alone	5	5.5
<b>4. Number of regions with cancer in individual cases.</b>		
Only 1	8	8.8
Only 2	7	7.7
Only 3	15	16.5
Only 4	11	12.1
Only 5	11	12.1
All 6	39	42.9

**Table 2. Table comparing the PSA, tumour volume, gleason score and grade group of cancers in different prostatic zones**

Zonal anatomy (frequency)	Gleason score	ISUP Grade group	PSA (ng/ml)	Average tumour volume	ATV prognostics (cut-off: 50%)	
Entire gland	62	8±1	4±1	1199.25±3693.17	51.84±18.65	≥50
Apex only	4	8±1	4±2	260.69±312.62	47.51±27.24	≥50
Mid-gland only	5	8±2	3±2	34.85±15.76	21.67±12.58	<50
Base only	2	7±1	3±1	34.78	5.90±5.52	<50
Apex & Mid-gland	9	7±1	3±1	46.76±41.06	21.40±10.30	<50
Apex & base	5	9±1	5±1	621.38±415.99	25.93±20.73	<50
Mid-gland & base	4	7±1	3±1	68.35± 55,05	32.95±27.94	<50
Total	91	8±1	4±1	903.70±3121,66	45.46±22.44	≥50



**Fig. 4. Photomicrographs showing; A) Well-formed Gleason pattern 3 glands (H&E x400), (B) Cribriform Gleason pattern 4 glands (H&E x100) (C) Gleason pattern 5 solid nest of cells in a prostate core (H&E x100) (D) High tumour volume in a prostate core (H&E x40)**

Although there appears to be increasing awareness of prostate cancer amongst Nigerian men with resultant earlier presentations, it is evident that late presentation is still common [24,25].

Although the most common tumour distribution pattern by side was involvement of both the left and right lobes of the gland, positive core biopsies from the right lobes were marginally more than those from the left lobes when only a single lobe was involved in this study. Poorly differentiated and high-grade tumours were present in all regions of the gland, although when only the left lobe was positive for cancer it had relatively higher incidence of low-grade carcinoma compared to other localized disease on core biopsies. This is interesting as it has been documented that due to most physicians being right-handed and the patient conventionally being positioned left decubitus for the digital rectal examination, many right-sided tumours are missed [26]. We cannot ascertain if the positioning or handedness played any role on

marginal occurrence of more positive biopsy cores from the right lobe.

Freedland et al. demonstrated that the percentage of cancer in cores from the dominant lobe was a good predictor of advanced pathology [17]. Positive cores from the non-dominant site may be smaller secondary tumours which do not determine adverse outcomes [17]. This is unlikely, because prostate cancer is a heterogeneous disease that usually presents with multifocal tumours; field cancerization mechanism has been suggested to underlie this process, suggesting that there are areas in a prostate gland that have cells which are more prone to malignant transformation [27]. Contextually, although there was no statistically significant difference in the lobar involvement, this may suggest a need for the clinician to make a conscious effort to examine the right lobe in better detail or may even drive a change in the position to accommodate the clinician's handedness and avoid missed unilateral lesions.

Biopsies from the apices and mid-gland also showed greater number of positive cores compared to the biopsies from the base in our study. Multiple prior reports have shown the apex to have the highest involvement with cancer, followed by the mid-gland and base [15,19,28,29]. This is despite a high false negative rate from TRUS-guided biopsies for apical tumours due to the difficulty angulating the needle, the narrow breadth and the potential for anteriorly-located tumours in this location [30]. A larger apical tumour volume increases detection, but also increases the risk of positive margins following radical prostatectomy [30]. On the contrary, the results of a multicenter international study in Austria and Italy showed that there was a homogenous distribution of cancer within the peripheral zone with no predilection for the apex, mid-gland or base of the gland [31]. However, these used an 18-core schema (six per apex/mid-gland/base) that may have improved the yield from less commonly preponderant areas. Although involvement of greater than 5% of base or apex biopsies of the prostate has been adjudged a good predictor of extra-prostatic extension [16], another study found no relationship between an apical tumour and positive surgical margins or extraprostatic extension, but positive surgical margins and extraprostatic extension were associated with positive cores from the base [32]. These discrepancies in conclusions may be due to variations in patient selection criteria and sample sizes.

This study shows that the average volume of cancer cells was higher in the mid gland and apex, with high tumour volumes above 10ml recorded. The zonal distribution of the tumour volumes was similar to the finding in a study by Ogori et al. [15]. A possible explanation for the high tumour volumes in the mid gland and apex would be due to the high glandular density within these regions [12]. The sole case with isolated involvement of the base had a Gleason score of 7 (ISUP grade 2) and tumour volume of 2ml. Higher tumour volumes, or its derivative, the relative tumour volume, have been inconsistently associated with PSA recurrence, locally invasive or disseminated disease, higher tumour grade and mortality [33,34]. Cheng et al. [34] prognostically categorized tumour volume into  $\leq 3$ ,  $>3$  to  $<10$  and  $\geq 10$ ml. The study showed 91.2% of patients had percentage tumour volumes above 10%, further adding to the poor prognostic indices in our environment. While the percentage volume of cores positive for cancer is

one of the strongest predictors for pathological stage [35], we observed that a significant percentage of prostate cancer in our environment occurred within the apex and mid-gland and were high grade carcinomas. This prevalence of high grade tumours may contribute to the relatively poor management outcome of men with prostate carcinomas in our environment [3,36]

## 5. LIMITATIONS

Surgical or radiological staging correlates were not available for pathological correlation due to late patient presentation. The small number of patients limited the power of conclusions drawn.

## 6. CONCLUSION

This study has shown that there is high average tumour volume and poorly differentiated cancers, with predominant involvement of the apex and mid-gland in this environment. Despite the difficulty of obtaining biopsy tissue from the apex, efforts should be made in getting cores from this site in patient work-up as it would help in stratification. Although site-specific labelling for prostate biopsies will mean increased work load for the surgeons and pathologists, we advocate for it because it provides extra prognostic and predictive information for the appropriate management of our patients.

## CONSENT

It is not applicable.

## ETHICAL APPROVAL

Cases reviewed were part of a multi-centre prospective study of prostate cancer genetics with ethical clearance from the institutional review board.

## COMPETING INTERESTS

Authors have declared that no competing interests exist.

## REFERENCES

1. Jedy-Agba E, Curado MP, Ogunbiyi O, Oga E, Fabowale T, Igbinoba F, et al. Cancer incidence in Nigeria: A report from population-based cancer registries. *Cancer Epidemiol.* 2012;36(5):271–8.
2. Rebbeck TR, Devesa SS, Chang B,



- Bunker CH, Cheng I, Cooney K, et al. Global patterns of prostate cancer incidence, aggressiveness, and mortality in men of African descent. *Prostate Cancer*; 2013.
3. Bassey I-AE, Isiwale EM, Debua A. Prognostication studies of prostate cancer in black Africa: Findings from Calabar, South-South, Nigeria. *Int J Contemp Med Res [IJCMR]*. 2018;5(5).
  4. Sapira MK, Eke N, Nwofor AM. Ethnicity and prostate cancer in southern Nigeria: A preliminary report. *Niger J Surg*. 2015;21:96–101.
  5. Mottet N, Bellmunt J, Briers E, Bolla M, Bourke L, Cornford P, et al. Members of the EAU – ESTRO – ESUR –SIOG prostate cancer guidelines panel. EAU – ESTRO – ESUR – SIOG Guidelines on Prostate Cancer. Edn. presented at the EAU Annual Congress Amsterdam 2020. EAU Guidelines Office. Place published: Arnhem, The Netherlands. 2020;978-94-92671-07-3.
  6. Bauer JJ, Zeng J, Zhang W, Mcleod DG, Sesterhenn IA, Connelly RR, et al. Lateral biopsies added to the traditional sextant prostate biopsy pattern increases the detection rate of prostate cancer. *Prostate Cancer Prostatic Dis*. 2000;3(1):43–6.
  7. Babaian RJ, Toi A, Kamoi K, Troncoso P, Sweet J, Evans R, et al. A comparative analysis of sextant and an extended 11-core multisite directed biopsy strategy. *J Urol*. 2000;163:152–7.
  8. Bjurlin MA, Carter HB, Schellhammer P, Cookson MS, Gomella LG, Troyer D, et al. Optimization of initial prostate biopsy in clinical practice: Sampling, labelling, and specimen processing. *J Urol*. 2013;189(6):2039–46.
  9. Cormio L, Scattoni V, Lorusso F, Perrone A, Montorsi F, Carrieri G. Prostate cancer detection rates in different biopsy schemes. Which cores for which patients? *World J Urol*. 2014;32(2):341–6.
  10. Optimal techniques of prostate biopsy and specimen handling - American urological association [Internet]; 2020.
  11. Hanna N, Wszolek MF, Mojtahed A, Nicaise E, Wu B, Gelpi-Hammerschmidt FJ, et al. Multiparametric magnetic resonance imaging-ultrasound fusion biopsy improves but does not replace standard template biopsy for the detection of prostate cancer. *J Urol*. 2019;202(5):944–51.
  12. Hammerich KH, Ayala GE, Wheeler TM. Anatomy of the prostate gland and surgical pathology of prostate cancer. Cambridge University, Cambridge; 2009.
  13. Laniado ME, McMullen I, Walker MM, Patel A. Use and rationale of a multicompartment microcassette for site-specific biopsies of the prostate in a consecutive cohort of men. *Prostate Cancer Prostatic Dis*. 2003;6(1):50–2.
  14. Singh PB, Saw NK, Haq A, Blades RA, Martin FL, Matanhelia SS, et al. Use of tissue ink to maintain identification of individual cores on needle biopsies of the prostate. *J Clin Pathol*. 2008;61(9):1055–7.
  15. Ohori M, Abbas F, Wheeler TM, Kattan MW, Scardino PT, Lerner SP. Pathological features and prognostic significance of prostate cancer in the apical section determined by whole mount histology. *J Urol*; 1999.
  16. Badalament RA, Miller MC, Peller PA, Young DC, Bahn DK, Kochie P, et al. An algorithm for predicting non-organ confined prostate cancer using the results obtained from sextant core biopsies with prostate specific antigen level. *J Urol*. 1996;156:1375–80.
  17. Freedland SJ, Aronson WJ, Terris MK, Kane CJ, Amling CL, Dorey F, et al. The percentage of prostate needle biopsy cores with carcinoma from the more involved side of the biopsy as a predictor of prostate specific antigen recurrence after radical prostatectomy results from the shared equal access regional cancer hospital (SEAR). *Cancer*. 2003;98(11):2344–50.
  18. Grossklaus DJ, Coffey CS, Shappell SB, Jack GS, Chang SS, Cookson MS. Percent of cancer in the biopsy set predicts pathological findings after prostatectomy. *J Urol*. 2002;167(5):2032–6.
  19. Moussa AS, Meshref A, Schoenfield L, Masoud A, Abdel-rahman S, Li J, et al. Importance of additional “Extreme” initial detection of prostate cancer. *Urology*. 2010;75(5):1034–9.
  20. Peller PA, Young DC, Marmaduke DP, Marsh WL, Badalament RA. Sextant prostate biopsies a histopathologic correlation with radical prostatectomy specimens. *Cancer*. 1995;75:530–8.
  21. Tombal B, Tajeddine N, Cosyns JP, Feyaerts A, Opsomer R, Wese FX, et al. Does site-specific labelling and individual processing of sextant biopsies improve the

- accuracy of prostate biopsy in predicting pathological stage in patients with T1c prostate cancer? BJU Int. 2002;89(6):543–8.
22. Badalament RA, Miller MC, Peller PA, Young DC, Bahn DK, Kochie P, et al. An algorithm for predicting nonorgan confined prostate cancer using the results obtained from sextant core biopsies with prostate specific antigen level. J Urol. 1996;156(4):1375–80.
  23. Merrick GS, Gutman S, Andreini H, Taubenslag W, Lindert DL, Curtis R, et al. Prostate cancer distribution in patients diagnosed by transperineal template-guided saturation biopsy. Eur Urol. 2007;52:715–24.
  24. Ikuerowo S, Doherty A, Bioku M, Abolarinwa A, Adebayo A, Oyeleke S, et al. Outcome of radical retropubic prostatectomy at the Lagos State University Teaching Hospital. Niger Med J. 2016;57(4):238–41.
  25. Badmus TA, Adesunkanmi KA, Yusuf BM, Oseni GO, Eziyi AK, Bakare TIB, et al. Burden of Prostate Cancer in Southwestern Nigeria. Urology. 2010;76(2):412–6.
  26. Ploussard G, Nicolaiew N, Mongiat-Artus P, Terry S, Allory Y, Vacherot F, et al. Left lobe of the prostate during clinical prostate cancer screening: The dark side of the gland for right-handed examiners. Prostate Cancer Prostatic Dis. 2014;17(2):157–62.
  27. Trujillo KA, Jones AC, Griffith JK, Bisoffi M. Markers of field cancerization: Proposed clinical applications in prostate biopsies. Prostate Cancer; 2012.
  28. Satoh T, Matsumoto K, Fujita T, Tabata KI, Okusa H, Tsuboi T, et al. Cancer core distribution in patients diagnosed by extended transperineal prostate biopsy. Urology. 2005;66(1):114–8.
  29. Introini C, Naselli A, Vigliercio G, Spina B, Truini M, Puppo P. Can biopsy be a reliable predictor of spatial distribution of prostate cancer? Comparison of a novel biopsy regimen with radical prostatectomy findings. Urology. 2006;68(6):1301–4.
  30. Sazuka T, Imamoto T, Namekawa T, Utsumi T, Yanagisawa M, Kawamura K, et al. Analysis of Preoperative detection for apex prostate cancer by transrectal biopsy. Prostate Cancer. 2013;2013:1–6.
  31. Brossner C, Winterholer A, Roehlich M, Dlouhy-Schutz E, Serra V, Sonnleithner M, et al. Distribution of prostate carcinoma foci within the peripheral zone: analysis of 8,062 prostate biopsy cores. World J Urol. 2003;21:163–6.
  32. Touma NJ, Chin JL, Bella T, Sener A, Izawa JI. Location of a positive biopsy as a predictor of surgical margin status and extraprostatic disease in radical prostatectomy. BJU Int. 2006;97(2):259–62.
  33. Wolters T, Roobol MJ, van Leeuwen PJ, van den Bergh RCN, Hoedemaeker RF, van Leenders GJLH, et al. Should pathologists routinely report prostate tumour volume? The Prognostic Value of Tumour Volume in Prostate Cancer. Eur Urol. 2010;57(5):821–9.
  34. Cheng WS, Frydenberg M, Bergstralh EJ, Larson-Keller JJ, Zincke H. Radical prostatectomy for pathologic stage C prostate cancer: Influence of pathologic variables and adjuvant treatment on disease outcome. Urology. 1993;42(3):283–91.
  35. Sebo TJ, Bock BJ, Chevillie JC, Lohse C, Wollan P, Zincke H. The percent of cores positive for cancer in prostate needle biopsy specimens is strongly predictive of tumor stage and volume at radical prostatectomy. J Urol. 2000;163(1):174–98.
  36. Olatokunbo MO, Adekunbiola AFB, Shonibare A, Fatimah BA, Chidozie CA, Olayinka AA. The clinicopathologic pattern of prostatic carcinoma in lagos, Nigeria. North Am J Med Sci. 2009;6(2):71–5.

© 2021 Omenai et al.; This is an Open Access article distributed under the terms of the Creative Commons Attribution License (<http://creativecommons.org/licenses/by/4.0>), which permits unrestricted use, distribution, and reproduction in any medium, provided the original work is properly cited.

*Peer-review history:*

*The peer review history for this paper can be accessed here:*  
<http://www.sdiarticle4.com/review-history/67571>