



The Histopathological Study of Gastrointestinal Polyps

Vidhya Subramanian¹, G. Bheema Rao² and J. Thanka^{2*}

¹Department of Pathology, A.C.S Medical College and Hospital, Chennai-600 077, Tamil Nadu, India.

²Department of Pathology, Sree Balaji Medical College and Hospital (Affiliated to Bharath Institute of Higher Education and Research), Chennai, Tamil Nadu, India.

Authors' contributions

This work was carried out in collaboration among all authors. All authors read and approved the final manuscript.

Article Information

DOI: 10.9734/JPRI/2021/v33i19B31342

Editor(s):

(1) Dr. Syed A. A. Rizvi, Nova Southeastern University, USA.

Reviewers:

(1) Sheida Jamalnia, Shiraz University of Medical Sciences, Iran.

(2) Igna Cornel, University of Agricultural Science and Veterinary Medicine of Banat from Timisoara, Romania.

Complete Peer review History: <http://www.sdiarticle4.com/review-history/66778>

Received 24 January 2021

Accepted 29 March 2021

Published 02 April 2021

Original Research Article

ABSTRACT

Polyps covered by non-neoplastic squamous epithelium may develop anywhere in the esophagus. Squamous polyps may be divided in to two types: Inflammatory polyps and squamous papillomas. To study the incidence and morphology of Gastro Intestinal Tract polyps from specimens received at Sree Balaji Medical College and Hospital, Chennai. To analyze the incidence and morphological features of malignancies associated with polyps. Of the 102 cases, intestinal cancer was found predominately 51(50%) followed by stomach. The ages ranged from 17 to 77 yrs and average was 44 yrs. The female ratio was 0.77. Expression of P53 was varied with the property of the polyps and it could be a useful marker for determining the treatment regime.

Keywords: Polyps; inflammatory; papillomas.

1. INTRODUCTION

A polyp is a nodule or mass that projects above the level of the surrounding mucosa and

protrudes into the lumen of the gut. Polyps of the Gastro Intestinal Tract are common in the 6th to 7th decade, though they may occur at any age. Polyps may develop as a result of epithelial or stromal cell hyperplasia, inflammation, ectopia,

*Corresponding author: E-mail: thanka.path@bharathuniv.ac.in;

or neoplasia [1-3]. If the Polyp is attached to the surface by a narrow elongated stalk, it is said to be pedunculated; If no stalk is present, it is said to be sessile.

Polyps of the gastrointestinal tract (GIT) are classified as non-neoplastic or neoplastic. The non-neoplastic polyps include inflammatory polyps, hyperplastic polyps, and hamartomatous polyps. Neoplastic polyps are called adenomas and broadly classified as benign and malignant [4-5].

GIT polyps may be sporadic or can be familial. Sporadic polyps may be asymptomatic, may be discovered by doing investigation for other disease conditions or identified while doing the autopsy [6]. Familial adenomatous polyposis is an autosomal dominant syndrome caused by a mutation of APC gene at chromosome 5q21 [7-8]. This is characterized by the early onset of numerous colonic adenomas with an inevitable progression to colorectal carcinoma. If it is detected at early, the prophylactic resection of the colon would be done as early as possible, can decrease incidence and mortality from colorectal carcinomas [9-10]. Various genetic studies and familial syndromes have helped to understand the pathogenesis of polyps especially in the case of colonic cancer arising from adenomatous polyps [11]. The incidence of neoplastic polyps are increased due to westernization of diet. Various endoscopic techniques have helped the identification and sampling of polyps and polypoidal lesions in various parts of gastrointestinal tract [12,13,14]. Clinical details and endoscopic findings are necessary to interpret these lesions correctly. Polypoidal lesions may mimic polyps endoscopically like mesenchymal and lymphoid tumors [15-17]. Though the p53 expression is one of the major determining factor, it is not clear that whether its expression could be used for classification of the polyps. This

questions would be addressed in the present paper.

2. MATERIALS AND METHODS

A total of 102 specimens that were identified as polyps in the gastrointestinal tract were studied at Sree Balaji Medical College and Hospital, Department of Pathology. The specimens included both endoscopic biopsies (polypectomy) and intestinal resection specimens (Ref. No. 002/SBMC/IHEC/2014-26).

The specimens were collected along with relevant clinical details including age, sex, clinical presentation, and family history of polyposis or GI cancers. The specimens were fixed using 10% Neutral Buffered Formalin and processed as for routine histopathological studies. H & E stain, special stains, and immunohistochemistry were applied wherever necessary [18,19].

3. RESULTS

The study conducted at Sree Balaji Medical College & Hospital in the Department of Pathology during a period of 22 months from February 2014 to November 2015. A total of 102 cases of Gastrointestinal Polyps were studied. The majority of lesions were situated in the large intestine, constituted 51(50%) cases followed by the stomach which constituted 36(35.29%) cases. The incidence of intestinal polyps was reported as 14(13.73%) cases. 1(0.98%) polyp was studied from the esophagus.

Histopathologically, 62 (60.78%) cases of non-neoplastic polyps were reported and 40 (39.22%) cases of neoplastic polyps were reported. Hyperplastic polyps were most common among non-neoplastic polyps, it accounts for 32(31.37%). Adenomatous polyps were most common among neoplastic polyps, which accounts for 40 (39.22%).

Table 1. Distribution of polyps in the gastro-intestinal tract

	Esophagus	Stomach	Small intestine	Large intestine
No. of cases (%)	1 (0.98%)	36 (35.29%)	14 (13.73%)	51 (50%)
Commonest site and type	Lower End / Hyperplastic	Antrum / Hyperplastic	Ileum / Hyperplastic	Left Colon / Adenomatous polyp

In Stomach - Female patients outnumbered males in the ratio 0.7:1 (M:F)

Table 2. GI Polyps distribution as per age and gender

	Esophagus	Stomach	Small intestine	Large intestine
Age Range	60 Years	17 - 77 Years	13 – 96 Years	4 - 81 Years
Mean Age	60 Years	44 Years	35 Years	47 Years
No. of Male Patients	0	15	11	29
No. of Female Patients	1	21	3	22
Male : Female Ratio	0 : 1	0.7 : 1	3.7 : 1	1.3 : 1

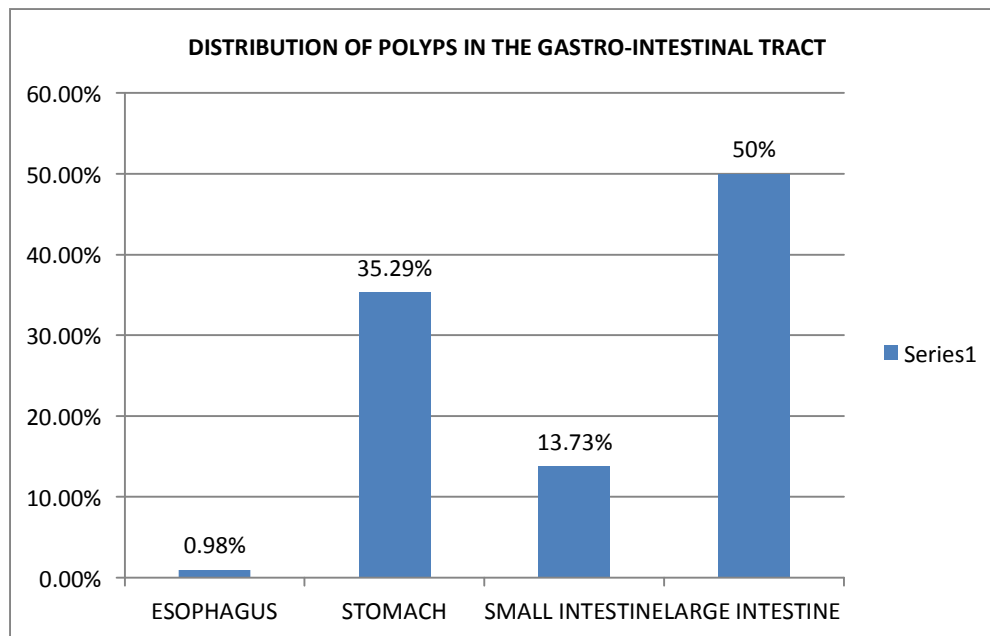


Chart 1. Distribution of polyps in the gastro-intestinal tract

Table 3. Non-neoplastic and neoplastic polyps

Non-neoplastic Polyps	Site				No. of Cases	%
	Esophagus	Stomach	Small Intestine	Large Intestine		
Hyperplastic Polyp	1	17	4	10	32	31.37
Inflammatory polyps	0	6	4	8	18	17.65
Peutz-Jeghers polyp	0	1	2	1	4	3.92
Juvenile Polyp	0	0	0	1	1	0.98
Fibro Epithelial Polyp	0	0	0	1	1	0.98
Fundic gland polyps	0	5	0	0	5	4.90
Brunner Gland Adenoma	0	0	1	0	1	0.98
Total	1	29	11	21	62	60.78

Neoplastic Polyps	Site				No. of cases	%
	Esophagus	Stomach	Small intestine	Large intestine		
Tubular adenoma	0	2	1	12	15	14.71
Villous Adenoma	0	2	1	6	9	8.82
Tubulo Villous Adenoma	0	1	1	10	12	11.76
Femilial adenomatous polyp	0	1	0	0	1	0.98
Adenomatous polyp with adenocarcinoma	0	1	0	2	3	2.94
Total	0	7	3	30	40	39.22

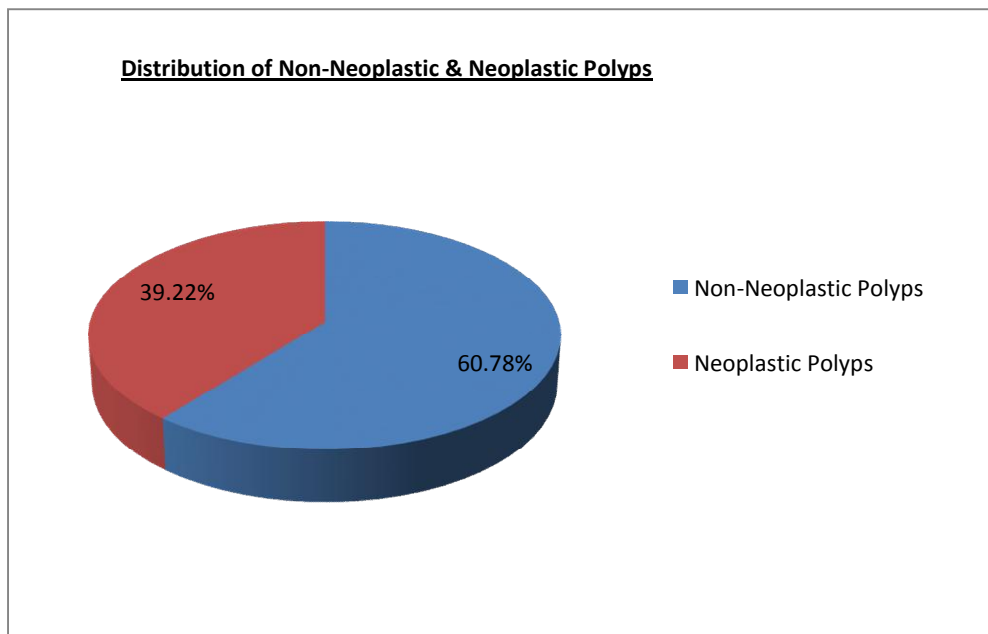


Chart 2. Non-neoplastic and neoplastic polyps

Table 4. Distribution of polyps in stomach based on site and histological type

Polyps	OGJ & Cardia	Fundus	Body	Antrum	Pylorus	No. of cases
Hyperplastic polyps		3	3	7	4	17
Fundic gland polyps	1	4				5
Inflammatory polyps		2	3		1	6
Adenomatous polyp			1	2	2	5
Peutz-Jeghers polyp				1		1
Femilial adenomatous polyp					1	1
Adenocarcinoma with adenomatous polyp				1		1
Total						36

One case of the hyperplastic polyp was noted in the esophagus. Polyps of the stomach constitute 36(35.29%) of total cases in my study. The age group ranged from 17 yrs to 77 yrs with a mean age of 44 yrs. In my study, female patients outnumbered males in the ratio of 0.7:1. The commonest site of involvement was antrum and the commonest lesion was a hyperplastic polyp.

14 (13.73%) cases of polyps were seen in the small intestine. The predominant site of involvement in this study was the ileum, constituting 8 cases. Hyperplastic polyps were 4, followed by 4 inflammatory polyps, 2 cases of Peutz-Jeghers polyps, 3 cases of adenomatous polyps, and one case of Brunner's gland adenoma were recorded.

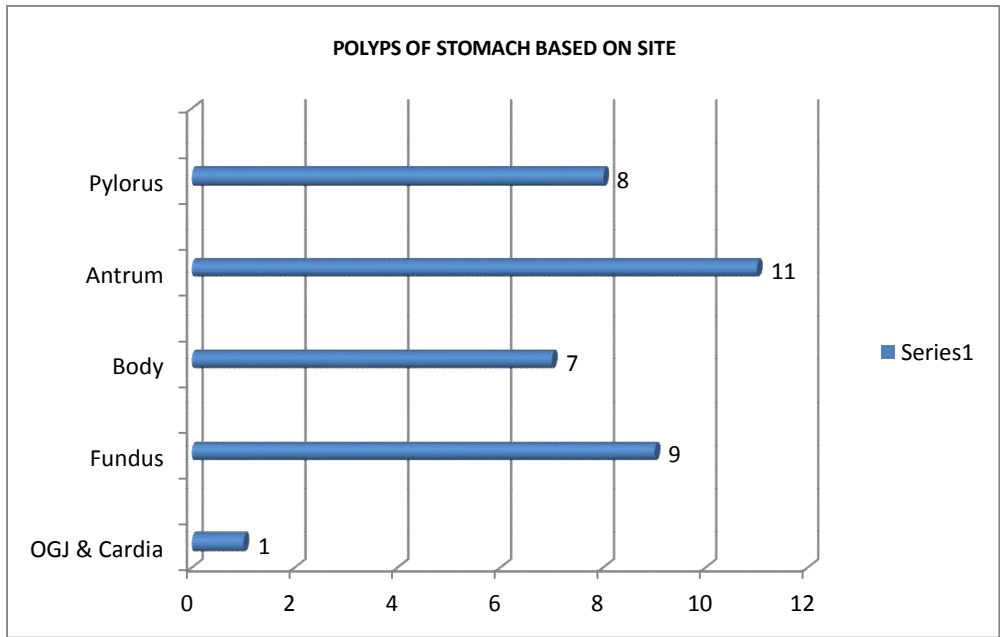


Chart 3. Polyps of stomach based on site

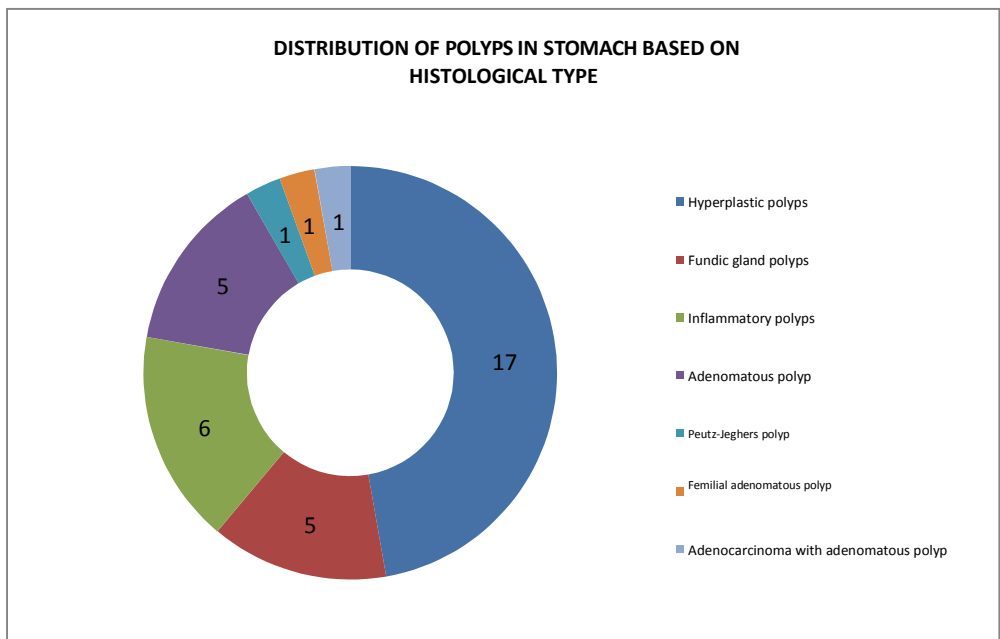


Chart 4. Distribution of polyps in stomach based on histological type

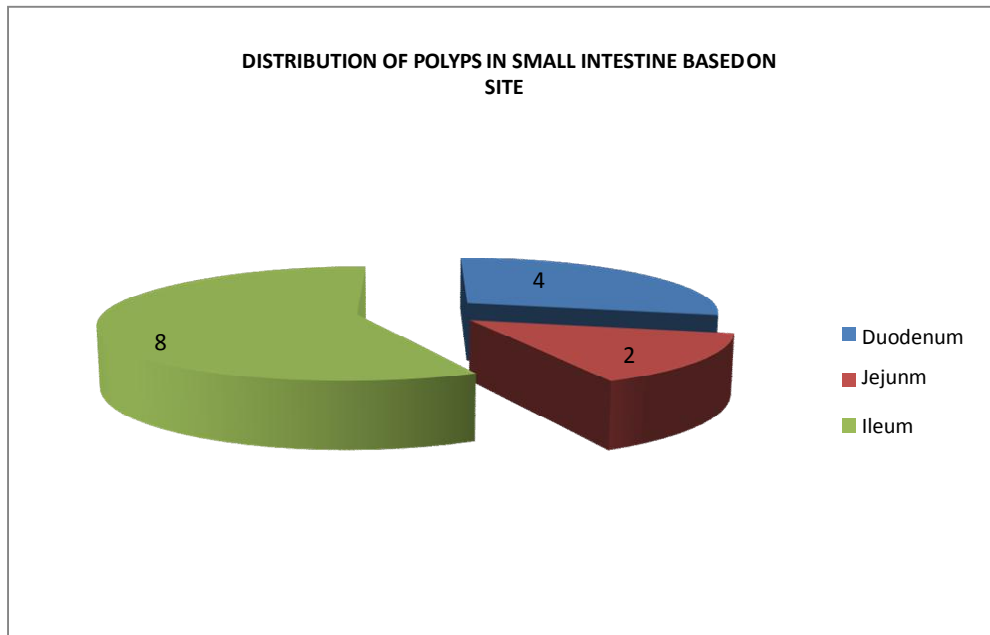


Chart 5. Distribution of polyps in small intestine based on site

Table 5. Distribution of polyps in small intestine based on site & histological type

Polyps	Duodenum	Jejunm	Ileum	No. of cases
Hyperplastic polyps	1	1	2	4
Inflammatory polyps	1		3	4
Adenomatous polyp	1		2	3
Peutz-Jeghers polyp		1	1	2
Brunner Gland Adenoma	1			1
Total				14

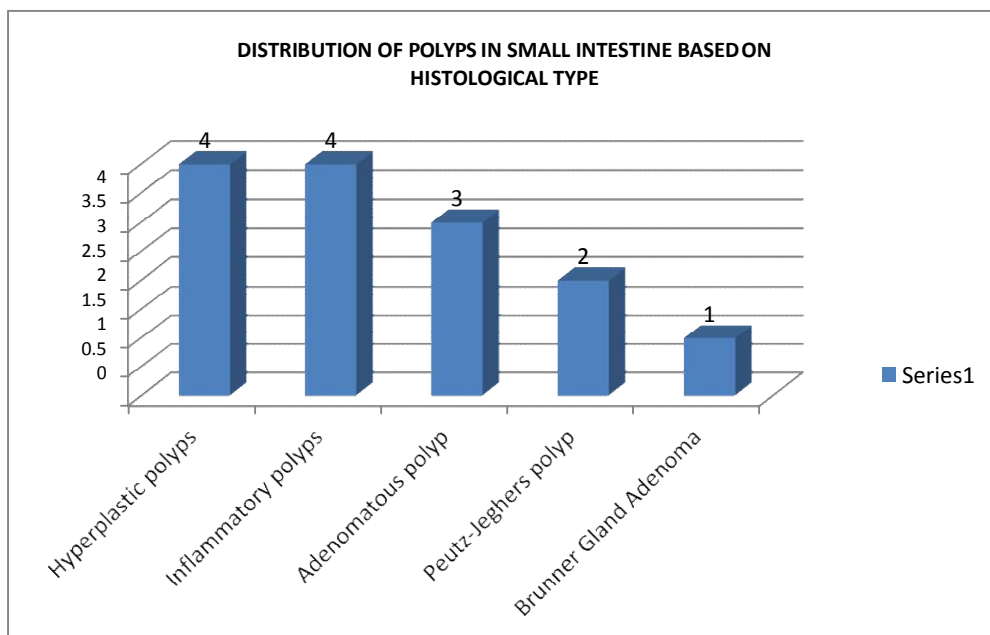


Chart 6. Distribution of Polyps in small intestine based on histological type

51 cases of large intestinal polyps reported which constitute 21 cases of non-neoplastic and 30 cases of neoplastic polyps. Most of the adenomatous polyps located at Colon 28 cases out of 51.

3.1 Immunohistochemistry

Expression of P53 is a good indicator of malignant changes of colonic polyps, Increased expression of P53 is helpful to identify high-risk patients and for their treatment. p53 applied for 40 (39.22%) cases of adenomatous polyps in which 27 (67.5%) cases were positive, whereas 13 (32.5%) cases were negative. Expression of P53 more expressed in Adenomatous polyp with adenocarcinoma 3(100%) cases, Familial adenomatous polyp 1(100%) followed by Tubulo villous adenoma 10(83.3%), Villous adenoma 7(77.8%), and Tubular adenoma 6(40%).

Table 6. Distribution of polyps in large intestine based on site

Site	No. of cases
Caecumc	3
Colon	28
Rectum	15
Anal Canal	5
Total	51

Table 7. Distribution of polyps in caecum based on histological type

Polyps	No. of cases
Inflammatory polyps	2
Adenomatous polyp	1
Total	3

Table 8. Distribution of polyps in colon based on site and histological type

Histological Type	No. of Cases							
	ASC	Transverse	Desc	Sig	Dysplasia		Malignant	Total
					Mild	Mod		
Tubulous Adenoma	2		4	2				8
Villous Adenoma						1 (SIG)	1 AC/SIG +2 (AC/DSC)	4
Tubulo Villous Adenoma	1		1	1		2 (DSC)	1 (AC/ASC) + 1 AC/MF)	7
Hyperplastic Polyp	2				4			6
Inflammatory Polyp	1		1					2
Peutz-Jeghers Polyp	1							1
Total								28

Table 9. Distribution of polyps in rectum based on histological type

Polyps	No. of cases
Inflammatory Polyp	3
Adenomatous Polyp	6
Hyperplastic Polyp	2
Fibro Epithelial Polyp	1
Juvenile Polyp	1
Adenomatous Polyp with Adenocarcinoma	2
Total	15

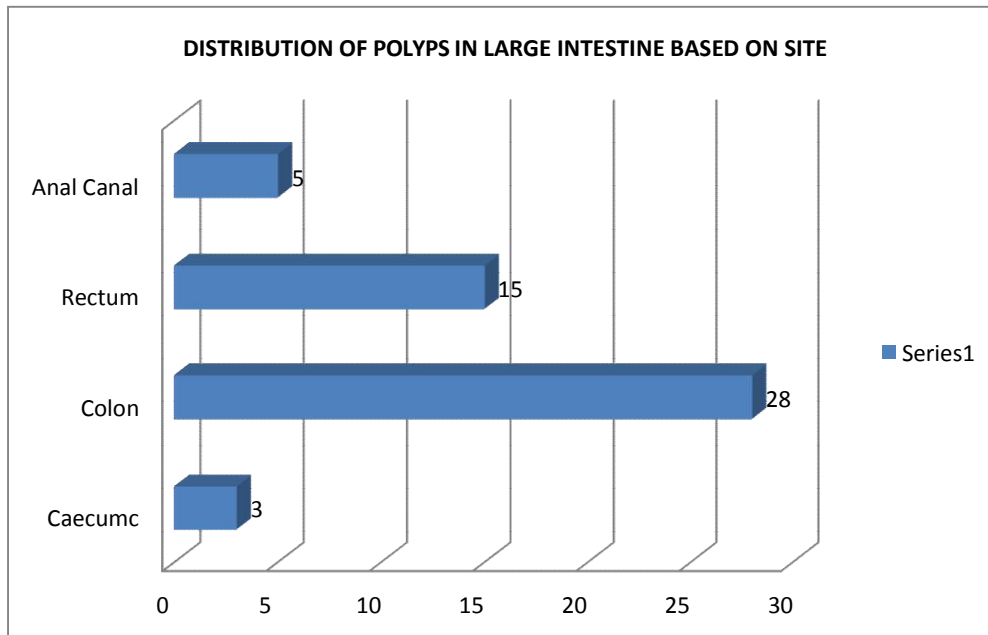


Chart 7. Distribution of polyps in large intestine based on site

Table 10. Distribution of polyps in anal canal based on histological type

Polyps	No. of cases
Inflammatory Polyp	1
Adenomatous Polyp	2
Hyperplastic Polyp	2
Total	5

Table 11. P53 expression in adenomatous polyps

Neoplastic Polyps	Total	P53 Positive	%	P53 Negative	%
Tubular adenoma	15	6	40	9	60
Villous Adenoma	9	7	77.8	2	22.2
Tubulo Villous Adenoma	12	10	83.3	2	16.7
Familial adenomatous polyp	1	1	100	0	0
Adenomatous polyp with adenocarcinoma	3	3	100	0	0
Total	40	27		13	

4. DISCUSSION

Polyps of the gastrointestinal tract have varying incidence depending on the size and morphology of the lesion. This study is hospital-based and reflects the incidence of gastrointestinal polyps at Sree Balaji Medical College and Hospital. 102 Gastrointestinal polyps were received; 62 (60.78%) cases of non-neoplastic polyps and 40 (39.22%) cases of neoplastic polyps were reported [19,20]. Esophageal polyps are very

rare, in my study; one case of the hyperplastic polyp was reported. In the stomach, 36(35.29%) cases were reported, it includes Hyperplastic polyps 17(47.2%) in number, Fundic gland polyps 5(13.8%) in number, Inflammatory polyps 6(16.6%) in number, Adenomatous polyps 5(13.8%) in number, Peutz-jeghers polyp one, Familial adenomatous polyp one and Adenomatous polyp with adenocarcinoma one. Hyperplastic polyps are commonly seen in the antrum. In my study out of 17 hyperplastic

polyps, 11 were located in the antrum, which correlates with the previous study [16].

In the small intestine, 14 (13.73%) cases were seen, it constitutes 4(28.5%) hyperplastic polyps, 4 (28.5%) inflammatory polyps, 3(21.4%) adenomatous polyps, 2(14.2%) cases of peutz-jeghers polyps and 1(7.1%) case of brunner gland adenoma. Peutz-Jeghers polyps may be sporadic or syndromic, with sporadic cases reported in various sites such as duodenum, stomach [20,21,22], jejunum [23,24], and rectum [24]. In my study, one PJ polyp was located in antrum another one in ilium. A large Japanese study showed that 15 out of 25 lesions seen in duodenum were Hyperplastic polyps. In my study, 4 hyperplastic polyps out of 14 cases seen, and 2 of 4 polyps were located in ilium, one in duodenum and one in jejunm. In the large intestine, 51(50%) cases were seen, which include 21 cases of non-neoplastic polyps and 30 cases of neoplastic polyps. In a study by Lee et al. [7] in Singapore on 1014 cases, 170(16.8%) were found to be adenomatous polyps while the study by Rickett RR et al. in New Jersey, USA showed an incidence of adenomatous polyps as 64.32%. Tony et al conducted a study in 124 cases and found 99(79.8%) cases of adenomatous polyps. In the present study, out of 102 cases, Large intestinal polyps 51(50%) remained the predominant population with most

of them being adenomatous polyps 40(39.22%), which correlates with the study by Lee et al. [7]. The predominant population of colonic polyps in this study was formed by adenomatous polyps 40(39.22%). Of these, 15(37.5%) tubular adenomas were 15(37.5%) Followed by tubulovillous adenoma 12(30%), villous adenoma 9(22.5%), and adenomatous polyps with carcinoma 4(10%). P53 nuclear stain applied for 43 (39.22%) cases of adenomatous polyps in which 27 (26.47%) cases were positive, whereas 13 (12.75%) cases were negative. Tubular villous adenoma 10(83.3%) cases showed more positive expression than villous adenoma 7(77.8%) and Tubular adenoma 6(40%). One Familial adenomatous polyp with malignancy showed 100% expression, which is co-relate with Shanmugam et al. [25] study, who have studied the expression of p53 and bcl2 in normal colonic epithelium, contiguous colorectal adenomas and cancers and found that expression of p53 and Bcl-2 progressively increased from normal-appearing epithelium to adenomas to carcinomas. They also concluded that the presence of p53 in the adenomatous epithelium is an indicator of aggressive behavior of colonic lesions and that these patients are more likely to develop aggressive invasive cancer [26,27].

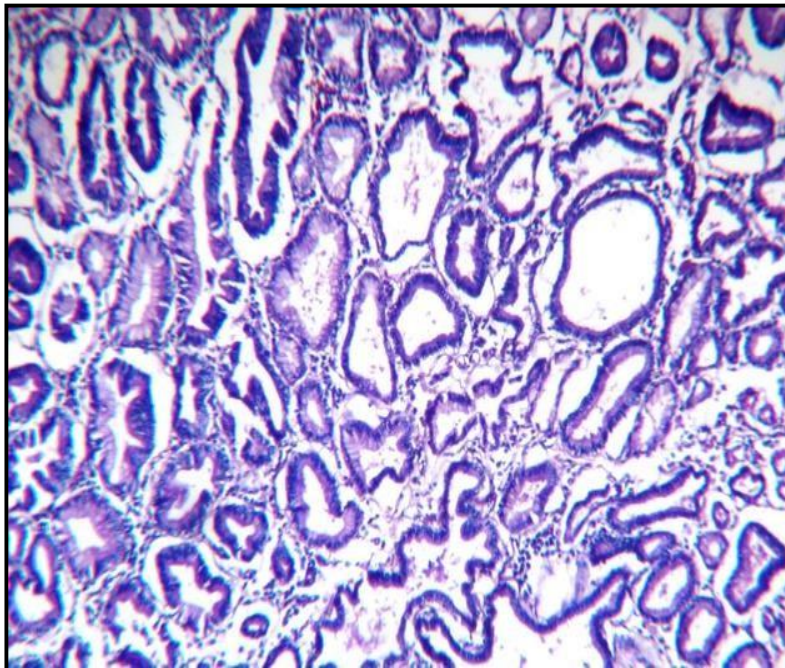


Fig. 1. Familial adenomatous polyps of stomach

10x: Multiple polyps and one focus showing increased stratification of lining epithelium, infiltration into muscle (malignant transformation) H & E 10x & 40x.

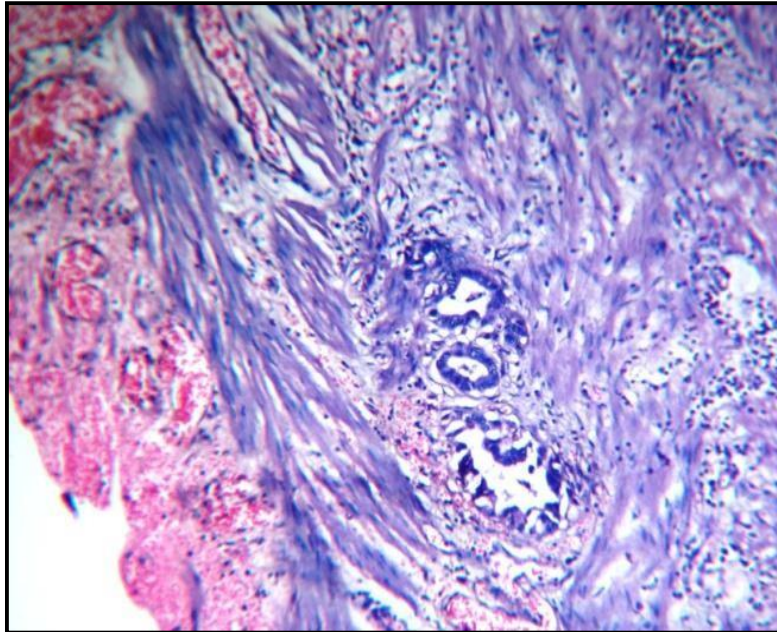


Fig. 2. Multiple polyps and one focus showing increased stratification of lining epithelium

Familial Adenomatous Polyps of Colon:

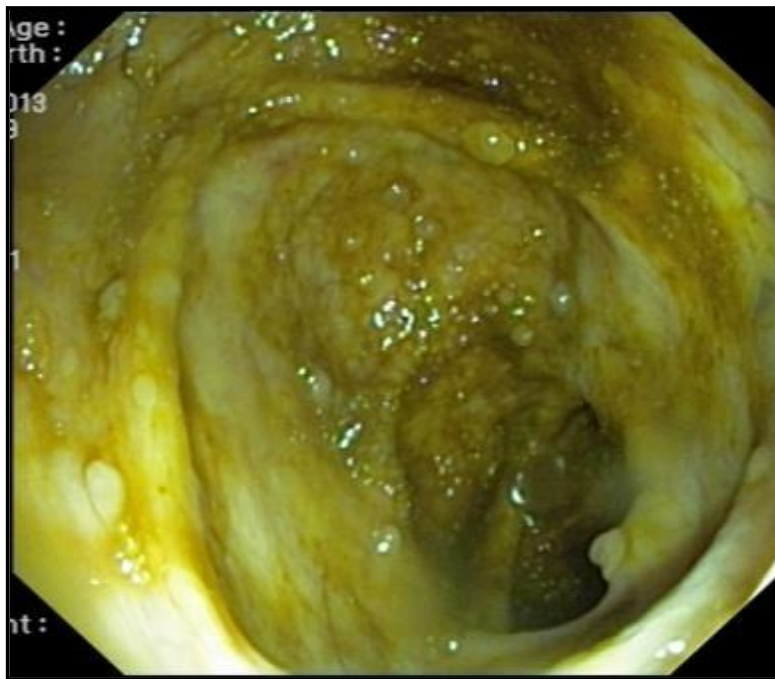


Fig. 3. Colonoscopy showing multiple polyps (Endoscopic Picture)

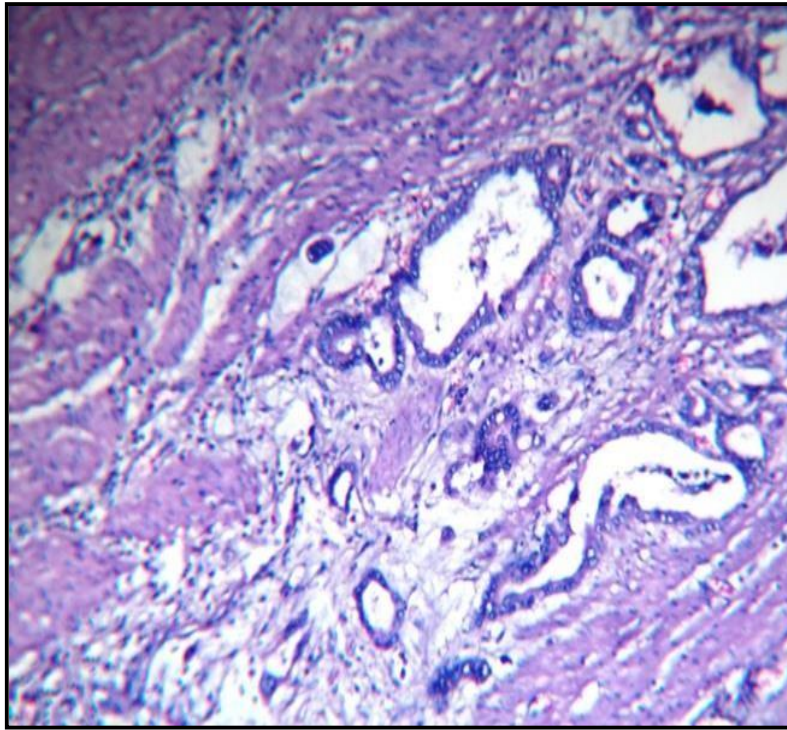


Fig. 4. Multiple colonic polyps H & E 40x

P53 expression in adenomatous polyp:

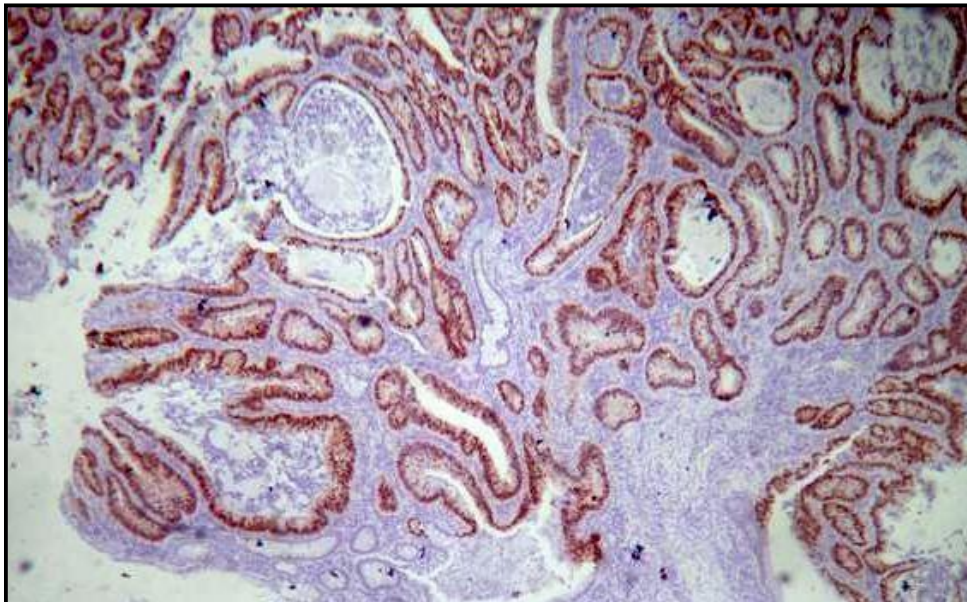


Fig. 5. Adenomatous polyp showing strong positivity for p53. x10

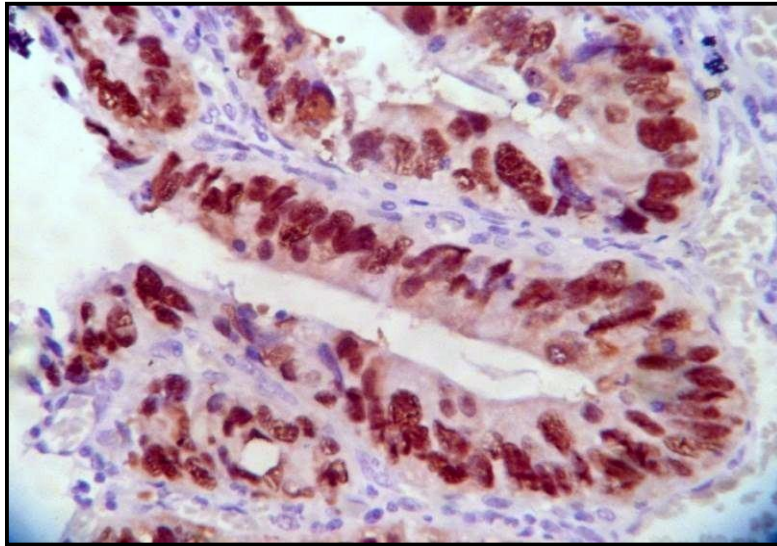


Fig. 6. p53 nuclear staining - strong positivity. x40

5. CONCLUSION

Polyps in the gastrointestinal tract may vary from asymptomatic incidental findings to invasive malignancies. Various investigatory modalities are being developed and available in developing countries for screening and diagnosis of these lesions. The morphology of the polyps are well defined to delineate them from one another. Though surveillance programs have been framed, it is imperative to establish cost-effective screening guidelines, to detect the lesions earlier. Genetic studies are needed to predict the malignant transformation of adenomatous polyps. In this regard, p53 could be a feasible marker for determining the therapeutic plans on polyps management.

CONSENT

It is not applicable.

ETHICAL APPROVAL

As per international standard or university standard written ethical approval has been collected and preserved by the author(s).

ACKNOWLEDGEMENTS

The encouragement and support from Bharath University, Chennai is gratefully acknowledged. For provided the laboratory facilities to carry out the research work.

COMPETING INTERESTS

Authors have declared that no competing interests exist.

REFERENCES

1. Williams AR, Balasooriya BA, Day DW. Polyps and cancer of the large bowel: A necropsy study in Liverpool. *Gut*. 1982; 23(10):835-42.
2. Konishi F, Morson BC. Pathology of colorectal adenomas: A colonoscopic survey. *J Clin Pathol*. 1982;35(8):830-41.
3. Burt RW, Bishop DT, Cannon LA, Dowdle MA, Lee RG, Skolnick MH. Dominant inheritance of adenomatous colonic polyps and colorectal cancer. *N Engl J Med*. 1985;312(24):1540 -4.
4. Aitken JF, Bain CJ, Ward M, Siskind V, MacLennan R. Risk of colorectal adenomas in patients with a family history of colorectal cancer: Some implications for screening programmes. *Gut*. 1996;39(1): 105-8.
5. Pollock AM, Quirke P. Adenoma screening and colorectal cancer. The need for screening and polypectomy is unproved. *Br J Med*. 1991;303:3-4.
6. Torlakovic E, Skovlund E, Snover DC, Torlakovic G, Nesland JM. Morphologic reappraisal of serrated colorectal polyps. *Am J Surg Pathol*. 2003;27(1):65-81.
7. Lee YS. Adenomas, metaplastic polyps and other lesions of the large bowel: An

- autopsy survey. *Ann Acad Med Singapore*. 1987;16(3):412-20.
8. Vatn MH, Stalsberg H. The prevalence of polyps of the large intestine in Oslo: An autopsy study. *Cancer*. 1982;49(4):819-25.
 9. Goldstein NS, Bhanot P, Odish E, Hunter S. Hyperplastic-like colon polyps that preceded microsatellite-unstable adenocarcinomas. *Am J Clin Pathol*. 2003; 119(6):778-96.
 10. Al-Tassan N, Chmiel NH, Maynard J et al. Inherited variants of MYH associated with somatic G:C-->T:A mutations in colorectal tumors. *Nat Genet*. 2002;30(2):227-32. Epub 2002 Jan 30.
 11. Jose Tony, Harish K, Ramachandran TM, Sunilkumar K, Varghese Thomas. Profile of colonic polyps in a southern Indian population. *Indian J Gastroenterol*. 2007; 26:127-129
 12. Gardner EJ. Follow-up study of a family group exhibiting dominant inheritance for a syndrome including intestinal polyps, osteomas, fibromas and epidermal cysts. *Am J Hum Genet*. 1962;14:376-90.
 13. Ismuil-Beigi F, Horton PF. Pope CE II. Histological consequences of gastroesophageal reflux in man. *Gastroenterology*. 1970;58:163-174.
 14. American Gastroenterological Association Medical Position Statement on the Management of Barrett's Esophagus. *Gastroenterology*. 2011;140:1084-1091.
 15. Hamilton S R et al. The molecular basis of Turcot syndrome. *N Engl J Med*. 1995;332: 839-847.
 16. Jass JR, Young PJ, Robinson EM. Predictors of presence, multiplicity, size and dysplasia of colorectal adenomas. A necropsy study in New Zealand. *Gut*. 1992;33(11):1508-14.
 17. Williams AR, Balasooriya BA, Day DW. Polyps and cancer of the large bowel: A necropsy study in Liverpool. *Gut*. 1982;23(10):835-42.
 18. Thurberg BL, Duray PH, Odze RD. Polypoid dysplasia in Barrett's esophagus: a clinicopathologic, immunohistochemical, and molecular study of five cases. *Hum Pathol*. 1999;30(7):745-52.
 19. Sanna CM, Loriga P, Dessi E, et al. Hyperplastic polyp of the stomach simulating hypertrophic pyloric stenosis. *J Pediatr Gastroenterol Nutr*. 1991;13:204-208.
 20. Hizawa K, Iwai K, Esaki M, Suekane H, Inuzuka S, et al. Endosonographic features of Brunner gland hamartomas which were subsequently resected endoscopically. *Endoscopy*. 2002;34:956-958.
 21. Fujimaki E, Nakamura S, Sugai T, Takeda Y. Brunner gland adenoma with a focus of p53 -positive atypical glands. *J Gastroenterol*. 2000;35:155-158.
 22. Nascimbeni R, Burgart LJ, Nivatvongs S, et al: Risk of lymph node metastasis in T1 carcinoma of the colon and rectum. *Dis Colon Rectum*. 2002;45:200-206.
 23. Haggitt RC, Glotzbach RE, Soffer EE et al: Prognostic factors in colorectal carcinomas arising in adenomas: Implications for lesions removed by endoscopic polypectomy. *Gastroenterology*. 1985;89: 328-336.
 24. Cooper HS, Deppisch LM, Ghourley WK, et al: Endoscopically removed malignant colorectal polyps: Clinicopathologic correlations. *Gastroenterology*. 1995;108: 1657-1665.
 25. Chandrakumar Shanmugam, Venkat R. Katkooi, Nirag C. Jhala, William E. Grizzle, Gene P. Siegal and Upender Manne. p53 Nuclear Accumulation and Bcl-2 Expression in Contiguous Adenomatous Components of Colorectal Adenocarcinomas Predict Aggressive Tumor Behavior *J Histochem Cytochem*. 2008;56:305.
 26. Kaklamanis L, et al. Bcl-2 protein expression: association with p53 and prognosis in colorectal cancer: *British Journal of Cancer*. 1998;77(11):1864-1869.
 27. John D. Bancroft, Marilyn Gamble. *Theory and Practice of histological techniques*, 5th edition, Churchill Livingstone; 2002.

© 2021 Subramanian et al.; This is an Open Access article distributed under the terms of the Creative Commons Attribution License (<http://creativecommons.org/licenses/by/4.0>), which permits unrestricted use, distribution, and reproduction in any medium, provided the original work is properly cited.

Peer-review history:

The peer review history for this paper can be accessed here:
<http://www.sdiarticle4.com/review-history/66778>