

Piotr Kubicki¹, Artur Szlubowski², Dariusz Jastrzębski¹, Damian Czyżewski³, Dariusz Ziara¹

¹Department of Lung Diseases and Tuberculosis, School of Medicine with the Division of Dentistry in Zabrze, Medical University of Silesia, Katowice, Poland

²Pulmonology Department, Clinical Hospital No. 1, Zabrze, Poland

³Department of Thoracic Surgery, Medical University of Silesia, Zabrze, Poland

Comparison of the diagnostic effectiveness between an expert and a student in the diagnosis of sarcoidosis by transbronchial biopsy of mediastinal lymph nodes under the control of endosonography

Abstract

Introduction: Endobronchial ultrasound-guided transbronchial needle aspiration (EBUS-TBNA) of mediastinal lymph nodes is currently considered to be the most effective minimally invasive diagnostic method in patients with suspected stage I and II sarcoidosis. However, diagnostic effectiveness depends on the experience and skills of the doctor which is dependent on the number of correctly performed procedures. The aim of the study is to compare the diagnostic effectiveness of the EBUS-TBNA test obtained by an expert in this field vs that of his student.

Material and methods: in patients with a clinical and radiological suspicion of sarcoidosis, EBUS-TBNA procedures were performed by an expert (over 1000 previously performed tests) and by his student who completed basic training (15 procedures performed). In the expert's opinion, the student was experienced enough to perform the EBUS-TBNA on his own. Previously, more than 100 conventional fiberoptic bronchoscopies had been performed by the student. During that time, he had been working in the department of pulmonary diseases and tuberculosis for two years. The sensitivity, specificity, positive predictive value (PPV), negative predictive value (NPV), positive likelihood ratio (LR+), negative likelihood ratio (LR-), and accuracy of the EBUS-TBNA test in diagnosing sarcoidosis were calculated. Statistical evaluation was made using ROC curves for the expert and for the student.

Results: The study included 215 patients between 22–68 years of age with suspected sarcoidosis who were diagnosed between 2013–2016. 124 EBUS-TBNA tests were performed by the expert, and 91 procedures were performed by the student. The presence of sarcoid granulomas was confirmed by a biopsy in 165 (76.7%) patients. In terms of the diagnosis of sarcoidosis, a higher sensitivity and accuracy of the EBUS test was found in the procedures done by the expert (76.7% and 95.3%, respectively) as compared to the results obtained by the student (66.1% and 93.1%, respectively). However, these differences were not statistically significant ($p = 0.11$). All tests were assessed in a hospital pathology unit, but not necessarily by one person, which may be a limitation of our research. In this study, only cytological smears were taken into consideration.

Conclusions: In the diagnosis of sarcoidosis, the student, after appropriate training by an expert, achieved a comparable level of diagnostic effectiveness with EBUS-TBNA after performing 90 tests independently.

Key words: sarcoidosis, EBUS-TBNA, learning curves

Adv Respir Med. 2021; 89: 241–246

Introduction

Sarcoidosis is a systemic disease with an unknown etiology that is characterised by de-

veloping noncaseating granulomas in different organs [1]. The most commonly affected areas (in approx. 90% of patients) are the lungs and mediastinal lymph nodes [2].

Address for correspondence: Piotr Kubicki, Department of Lung Diseases and Tuberculosis, School of Medicine with the Division of Dentistry in Zabrze, Medical University of Silesia, Katowice, Poland; e-mail: pm.kubicki@gmail.com

DOI: 10.5603/ARM.a2021.0050 | Received: 13.08.2020 | Copyright © 2021 PTChP | ISSN 2451–4934 | e-ISSN 2543–6031

This article is available in open access under Creative Commons Attribution-Non-Commercial-No Derivatives 4.0 International (CC BY-NC-ND 4.0) license, allowing to download articles and share them with others as long as they credit the authors and the publisher, but without permission to change them in any way or use them commercially.

Diagnosing the illness on the basis of clinical images and radiological changes is often inadequate and demands more thorough procedures that allow for the histopathological examination of noncaseating granulomas. In a lot of cases, it is necessary to differentiate sarcoidosis from diseases such as tuberculosis, mycobacteriosis, aspergillosis, cryptococcosis, histoplasmosis, allergic alveolitis, pneumoconiosis (e.g. berylliosis), from drug-induced reactions, and from interstitial lung diseases like lymphoid interstitial pneumonia (LIP), necrotising sarcoid granulomatosis, bronchocentric granulomatosis, and Langerhans cells histiocytosis. In rare cases, akin to those afflicted with Löfgren's syndrome, a diagnosis can be made without an additional organ biopsy [3].

In the case of lesions located outside the lumen of the bronchial tree, classic fiberoptic bronchoscopy is inadequate and more modern methods of bronchoscopy are needed to establish a diagnosis [4].

In the last decade, a new innovative approach known as the endobronchial ultrasound technique (EBUS) was introduced. This innovation consists of a bronchoscope with an integrated ultrasound probe. It allows for the assessment of different mediastinal structures and pulmonary cavities (especially lymph nodes and vascular structures) as well as bronchial lesions in real-time. The ultrasound bronchoscope also allows for performing aspiration transbronchial needle biopsies (TBNA) in enlarged lymph nodes. This technique is useful in the diagnosis of sarcoidosis as well as other diseases accompanied by enlargement of the lymph nodes. These diseases include metastasis of breast or lung cancer, tuberculosis of the lymph nodes, reactive adenopathy or sarcoid reaction in the course of RA, collagen diseases, IPF, reactive inflammatory changes, etc. Data from the past few years concerning the EBUS technique indicates its safety and effectiveness in diagnosing and evaluating the stage of lung cancer, sarcoidosis, as well as other mild causes of swollen mediastinal lymph nodes and pulmonary cavities [5, 6].

In the case of confirmed sarcoidosis classified as being in the first or second stage, a biopsy can be performed on enlarged lymph nodes under ultrasound control (EBUS-TBNA) and/or transesophageal endoscopic ultrasound-guided fine needle aspiration (EUS-FNA), thus avoiding mediastinoscopy. A combination of both methods of ultrasound (EBUS, EUS) increases the ability to recognize sarcoidosis in 83-90% of cases with a specificity of nearly 100% [7].

Since the EBUS-TBNA technique has a high diagnostic efficiency, there has been a very urgent need to train specialists in endoscopic diagnostics. There are recommendations from the European Respiratory Society (ERS) regarding EBUS training; however, there is no clear position on how best to train clinicians in EBUS and how to assess their competence. It is still not specified what the minimum number of procedures performed during training should be [8]. Publications concerning the number of procedures required before satisfactory performance is obtained by doctors performing bronchoscopies give divergent results. A study regarding an operator's learning curve in a large group of patients with suspected sarcoidosis has not yet been described. The data published so far contains some suggestions for interventional pulmonological procedures, but they arose largely due to the availability of the EBUS technique mainly used in lung cancer patients [9, 10].

Work objective

The aim of the study was to compare the diagnostic effectiveness of the EBUS-TBNA test when performed by an expert (AS) (who had performed >1000 tests and had conducted trainings and courses in the field of endosonography in Poland and abroad) and when performed by his student (PK). The student, a specialist in lung diseases, performed over 100 conventional fiberoptic bronchoscopies over a 2-year period in the department of pulmonary diseases and tuberculosis. The student completed basic training at the turn of 2013/2014, performing 15 EBUS-TBNA procedures under supervision. The expert positively assessed the student's skills in terms of intubation with the EBUS apparatus and smooth movement in the bronchial tree, correct identification of mediastinal nodal stations and lung cavities using the EBUS technique, ability to coordinate teamwork (medical and nursing) during an endosonographic examination, and correct performance with regards to the biopsy itself and pap smears.

In order to evaluate the individual who was performing the EBUS-TBNA procedure, the following procedures were assessed: indications for the procedure, preparation and sedation/anesthesia of the patient, assessment of the size of nodes, number of biopsies performed, and above all, assessment of the collected material for cytological examination (if there was a lymph node).

Material and methods

The results of the EBUS-TBNA study were evaluated retrospectively from a group of 215 patients 22–68 years of age referred to our clinic in 2013–2016 with suspected stage I and II sarcoidosis. EBUS-TBNA studies were performed on a BF-UC 180F apparatus and 22-gauge NA-201SX-40/22 needles (Olympus Medical Systems Corporation, Tokyo, Japan) were used for biopsy. All procedures were performed under local anesthesia and shallow intravenous analgesation with fentanyl (0.05–0.1 mg iv) and midazolam (1–5 mg iv). Nodes ≥ 10 mm were selected for biopsy and punctured 3–5 times. The expert performed 124 EBUS-TBNA tests, and his student performed 91 procedures independently without supervision. The tests were carried out without the use of the cytological ROSE technique (Rapid On-Site Evaluation), which is the initial cytological assessment of the suitability of the material for cytological evaluation.

The sensitivity, specificity, positive predictive value (PPV), negative predictive value (NPV), positive likelihood ratio (LR+), negative likelihood ratio (LR-), and the EBUS accuracy for the diagnosis of sarcoidosis obtained by the expert (AS) and the student (PK) were calculated. The comparison of the diagnostic effectiveness of the expert and the student was made by comparing the area under the ROC curves showing the dependence of the specificity and sensitivity of the procedures. $P < 0.05$ was considered to be statistically significant.

Results

The presence of sarcoid granulation tissue (non-caseating) was detected in 165 (76.7%) patients based on cytological examination of the EBUS-TBNA test. All tests were assessed in a hospital pathology unit, but not necessarily by one person, which may be a limitation of our research. In this study, only cytological smears were taken into consideration.

In the remaining 50 patients (23.3%), the final diagnosis, other than sarcoidosis, was obtained on the basis of histological examination using techniques other than EBUS-TBNA as part of a 6 month clinical follow-up. The diagnoses in this subgroup of patients are summarized in Table 1.

In terms of the diagnosis of sarcoidosis, a higher sensitivity and accuracy of the EBUS-TBNA test was found when the procedure was performed by the expert (AS) (76.7% and 95.3%, respectively) than when performed by the student (PK) (66.1% and 93.1%, respectively) (Table 2).

However, these differences were not statistically significant ($p = 0.11$) (Figure 1). In the diagnosis of sarcoidosis, the student, after receiving appropriate training from the expert, achieved a comparable level of EBUS-TBNA diagnostic effectiveness after performing 90 tests on his own.

During the tests and after their completion, no complications were observed in both the expert and student groups.

Table 1. Other diagnoses obtained in a subgroup of 50 referred patients with initial suspicion of sarcoidosis

No.	Diagnosis (other than sarcoidosis)	Number of patients	[%]
1	Reactive inflammatory changes	14	6.5
2	Pneumoconiosis	13	6
3	Reactive adenopathy or sarcoid reaction in the course of RA, collagen diseases, IPF	11	5.1
4	Metastasis of breast cancer	3	1.4
5	Suspicion of Hodgkin's and/or non-Hodgkin's lymphoma	3	1.4
6	Lung cancer metastasis	3	1.4
7	Tuberculosis of the lymph nodes	2	8
8	Thyroid cancer metastasis	1	0.4
	Total	50	23.3

IPF — idiopathic pulmonary fibrosis; RA — rheumatoid arthritis

Table 2. Comparison of the EBUS examination effectiveness obtained by the expert and the student

	Number of patients	Sensitivity	Specificity	PPV	NPV	LR+	LR-	Accuracy
Total	215	72.7%	94.0%	97.6%	51.1%	12.1	0.29	77.7%
Expert	124	76.7%	95.3%	98.8%	45.5%	16.1	0.24	79.8%
Student	91	66.1%	93.1%	95.4%	56.3%	9.6	0.36	74.7%

LR- — negative likelihood ratio; LR+ — positive likelihood ratio; NPV — negative predictive value; PPV — positive predictive value

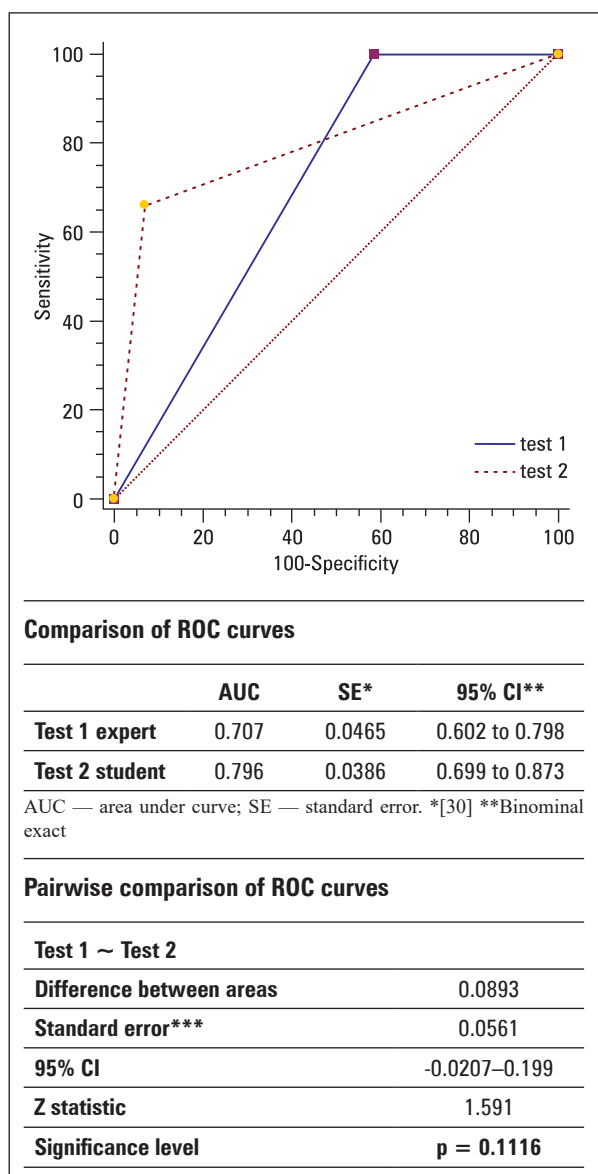


Figure 1. The analysis of the area under the ROC curves for the expert and the student did not confirm statistical differences ($p = 0.11$). Test 1 — ROC curve of the expert; Test 2 — ROC curve of the student

Discussion

The study showed that, after performing the initial 90 EBUS-TBNA tests, the skills of the student-pulmonologist were sufficient not only to perform the procedure independently, but also to achieve the effectiveness similar to that achieved by the expert in terms of diagnosis of sarcoidosis. Despite the limitations of the EBUS technique resulting from the size of the apparatus, this procedure is used wherever extrabronchial lesions are within the scope of examination (due to diameter of the device), as well as wherever there is a possibility of bending the ultrasound head to fit into the necessary area. Continuous reduction of the size of

bronchoscopic devices in line with technological progress (their diameter is reduced, the angle of the ultrasound head bend increases) leads to surprising diagnostic possibilities such as penetration of more distant corners of the bronchial tree with the possibility of entering high-lobe bronchi and taking cytologically adequate needle biopsies [11].

However, despite this technical progress, the results obtained depend primarily on the skill and training level of the examiner. This is indicated by published studies assessing the learning curve for EBUS-TBNA [12–14].

A retrospective study evaluating the so-called learning curve of the EBUS-TBNA procedure based on the diagnostic sensitivity achieved by two thoracic surgeons indicated that only 10 procedures were enough to achieve a minimum degree of competence [14]. On the other hand, a prospective study from Australia found that the diagnostic effectiveness of EBUS-TBNA achieved by two pulmonologists significantly improved after 20 procedures, but only reached its peak after 50 [12].

According to Bellinger *et al.* [15], in order to achieve an acceptable minimum standard, it is sufficient to perform only 25 EBUS-TBNA tests during training. As indicated by other authors [16, 17], 95% diagnostic accuracy in the case of various mediastinal pathologies (metastasis of cancer, sarcoidosis, and others) is achieved after 100 independently performed procedures, and almost 100% accuracy is possible only after an extended learning process and as many as 160 procedures [16]. A similar opinion is expressed by Medford *et al.* [18] after assessing the accuracy of EBUS-TBNA obtained by two operators (98.4% and 97.6%, respectively) only after exceeding 122 and 163 procedures, each. After only 50 examinations were performed, both operators did not achieve 90% accuracy in the diagnosis of various mediastinal pathologies. These discrepancies led to a discussion on the number of procedures required in the EBUS-TBNA teaching process [12] and the adoption of at least 50 tests performed being set as the standard in the recommendations of the American College of Chest Physicians to obtain appropriate competencies before performing EBUS on their own [10, 19]. An extremely important aspect in the process of learning the EBUS-TBNA technique is the predisposition and skills of the doctors in training. A UK study confirmed significant differences in the learning process even among experienced bronchoscopists, as two of the five assessed operators were still in the so-called ‘learning phase’ after performing as many as 100 procedures [13].

According to expert recommendations [20], the use of low or high fidelity simulators (class 2C) is suggested during the training of EBUS-TBNA operators. In the case of bronchoscopy and the EBUS technique, the significance and reliability of a similar tool [21] (EBUS-STAT) has already been assessed. EBUS-STAT evaluates the bronchoscope introduction, navigation, image acquisition, vascular imaging, nodal imaging, single station biopsying, and image modification. It also includes a knowledge test of CT and EBUS imaging. According to some authors [22], not all of the above-mentioned teaching components have the same value in acquiring final competencies, but EBUS virtual reality simulators may play a positive role in assessing the operator's skills before performing an individual procedure in humans. Unfortunately, the above-mentioned simulation studies did not check whether the skills demonstrated during such simulations directly translate into the improvement of skills during the test in humans. These studies involved a small number of operators and the results showed a significant variation in the learning process of EBUS-TBNA. At the same time, it was indicated that 55 to 60 simulations should be performed independently before achieving the appropriate competencies [23].

On the other hand, Wahidi *et al.* [24] compared the learning curves of the EBUS-TBNA procedure obtained by various specialists in lung diseases and found that an average of 13 tests are needed to perform the first successful procedure. Diametrically different results are presented by Stather *et al.* [25] who assessed the learning curves of the EBUS procedure in nine interventional pulmonologists and confirmed large differences in diagnostic effectiveness depending on the presented operator abilities. Some of the evaluated operators still achieved an increase in the diagnostic effectiveness of EBUS only after 200 self-performed tests. When assessing EBUS-TBNA operators, the authors of an expert panel [20] suggested using the proven EBUS skill assessment tests to objectively assess skill levels. This study shows that the expert's opinion on the student's skills was very important.

In a meta-analysis by Agrawal *et al.* [26], a systematic review of the effectiveness and safety of EBUS-TBNA in the diagnosis of sarcoidosis was performed. The results of this diagnostic performance are similar. In the cited study, the diagnostic efficiency of EBUS-TBNA ranged from 54% to 93% with an average diagnostic accuracy of 79% (95% CI: 71–86). Interestingly,

there was no statistical difference in accuracy in studies using ROSE (Rapid On-Site Evaluation) (80.1%) compared to those without ROSE (81.3%). Compared to conventional bronchoscopic techniques, the EBUS-TBNA provides safe and minimally invasive access to the mediastinal lymph nodes and cavities with a total diagnostic accuracy of 79.1%. Therefore, this technique is recommended when diagnosing patients with suspected sarcoidosis who have enlarged lymph nodes of the mediastinum and hilar areas. When trying to assess the skills of endoscopists, as well as the ability to learn new techniques, the previously mentioned methods are used in combination with the so-called 'causality analysis'. The CuSum (cumulative sum) algorithm belongs to algorithms based on the control of statistical processes. This method detects deviations from the baseline indicators in the monitoring system. Unlike conventional methods, CuSum allows for the detection of small, sudden changes. The CuSum chart is based on the differences between the mean values and the reference value. If the process of executing EBUS-TBNA procedures is correct, it is expected that the points plotted on the CuSum chart will align around zero along the horizontal axis. If the points plotted on the graph start to form a line inclined towards the vertical axis, it means that there is a systematic error and the analyses performed with the given method should be suspended until the problem is solved.

A report by Kemp *et al.* [13] suggests that the use of CuSum cards in the learning curve analysis for EBUS is more important than the various methods previously described. It turns out that even experienced bronchoscopists differ in their learning speed. One possible reason for the different course of learning curves could be the proportion of large and small (< 10 mm) lymph nodes undergoing biopsy. However, according to Fernandez [27], out of 354 biopsies, 90 nodes were less than 10mm in size and the EBUS-TBNA method still showed 91.17% sensitivity, 100.0% specificity, and a negative predictive value of 92.9%. Also, in the diagnosis of sarcoidosis, neither the thickness of the needles used in EBUS-TBNA, nor the number of samples taken, concerning both the number of lymph nodes and the number of biopsies, were related to the diagnostic performance [28]. In a prospective study by Garwood *et al.* [29], the accuracy exceeded 80% with five biopsies, but no further increase after seven biopsies. Finally, what should be emphasized is that results may largely depend on the predisposition and manual skills of the examiner [13].

In summary, EBUS-TBNA is a valuable technique in the diagnosis of sarcoidosis, even when performing this procedure without the presence of a cytologist. Improvement in EBUS-TBNA performance in patients with suspected sarcoidosis should be expected as the bronchoscopist acquires greater experience. We postulate that the bronchoscopist should perform at least 90 tests to achieve competence.

Conflict of interest

None declared.

References:

1. Costabel U, Hunninghake GW. ATS/ERS/WASOG statement on sarcoidosis. *European Respiratory Journal*. 1999; 14(4): 735, doi: [10.1034/j.1399-3003.1999.14d02.x](https://doi.org/10.1034/j.1399-3003.1999.14d02.x).
2. Baughman RP, Teirstein AS, Judson MA, et al. Clinical characteristics of patients in a case control study of sarcoidosis. *Am J Respir Crit Care Med*. 2001; 164(10 Pt 1): 1885–1889, doi: [10.1164/ajrccm.164.10.2104046](https://doi.org/10.1164/ajrccm.164.10.2104046), indexed in Pubmed: [11734441](https://pubmed.ncbi.nlm.nih.gov/11734441/).
3. Crouser, E. D. Diagnosis and detection of sarcoidosis an official american thoracic society clinical practice guideline. *Am. J. Respir. Crit. Care Med*. 2020; 201: E26–E51.
4. Ziara D, Jastrzębski D, Labus E. Postępy w diagnostyce sarkoidozy płuc. *Pneumonologia i Alergologia Polska*. 2012; 80(4): 355–364.
5. Tremblay A, Stather DR, MacEachern P, et al. A randomized controlled trial of standard vs endobronchial ultrasonography-guided transbronchial needle aspiration in patients with suspected sarcoidosis. *Chest*. 2009; 136(2): 340–346, doi: [10.1378/chest.08-2768](https://doi.org/10.1378/chest.08-2768), indexed in Pubmed: [19188547](https://pubmed.ncbi.nlm.nih.gov/19188547/).
6. Gu P, Zhao YZ, Jiang LY, et al. Endobronchial ultrasound-guided transbronchial needle aspiration for staging of lung cancer: a systematic review and meta-analysis. *Eur J Cancer*. 2009; 45(8): 1389–1396, doi: [10.1016/j.ejca.2008.11.043](https://doi.org/10.1016/j.ejca.2008.11.043), indexed in Pubmed: [19124238](https://pubmed.ncbi.nlm.nih.gov/19124238/).
7. Annema JT, Versteegh MI, Veselić M, et al. Endoscopic ultrasound-guided fine-needle aspiration in the diagnosis and staging of lung cancer and its impact on surgical staging. *J Clin Oncol*. 2005; 23(33): 8357–8361, doi: [10.1200/JCO.2005.01.1965](https://doi.org/10.1200/JCO.2005.01.1965), indexed in Pubmed: [16219935](https://pubmed.ncbi.nlm.nih.gov/16219935/).
8. Unroe MA, Shofer SL, Wahidi MM. Training for endobronchial ultrasound: methods for proper training in new bronchoscopic techniques. *Curr Opin Pulm Med*. 2010; 16(4): 295–300, doi: [10.1097/MCP.0b013e32833a047a](https://doi.org/10.1097/MCP.0b013e32833a047a), indexed in Pubmed: [20531196](https://pubmed.ncbi.nlm.nih.gov/20531196/).
9. Bolliger CT, Mathur PN, Beamis JF, et al. ERS/ATS statement on interventional pulmonology. *European Respiratory Society/American Thoracic Society*. *Eur Respir J*. 2010; 19(2): 356–372, doi: [10.1183/09031936.02.00204602](https://doi.org/10.1183/09031936.02.00204602), indexed in Pubmed: [11866017](https://pubmed.ncbi.nlm.nih.gov/11866017/).
10. Ernst A, Silvestri GA, Johnstone D. Interventional pulmonary procedures: Guidelines from the American College of Chest Physicians. *Chest*. 2003; 123(5): 1693–1717, doi: [10.1378/chest.123.5.1693](https://doi.org/10.1378/chest.123.5.1693), indexed in Pubmed: [12740291](https://pubmed.ncbi.nlm.nih.gov/12740291/).
11. Wada H, Hirohashi K, Nakajima T, et al. Assessment of the new thin convex probe endobronchial ultrasound bronchoscope and the dedicated aspiration needle: a preliminary study in the porcine lung. *J Bronchology Interv Pulmonol*. 2015; 22(1): 20–27, doi: [10.1097/LBR.0000000000000123](https://doi.org/10.1097/LBR.0000000000000123), indexed in Pubmed: [25590479](https://pubmed.ncbi.nlm.nih.gov/25590479/).
12. Steinfurt DP, Hew MJ, Irving LB. Bronchoscopic evaluation of the mediastinum using endobronchial ultrasound: a description of the first 216 cases carried out at an Australian tertiary hospital. *Intern Med J*. 2011; 41(12): 815–824, doi: [10.1111/j.1445-5994.2009.02142.x](https://doi.org/10.1111/j.1445-5994.2009.02142.x), indexed in Pubmed: [20002848](https://pubmed.ncbi.nlm.nih.gov/20002848/).
13. Kemp SV, El Batrawy SH, Harrison RN, et al. Learning curves for endobronchial ultrasound using cusum analysis. *Thorax*. 2010; 65(6): 534–538, doi: [10.1136/thx.2009.127274](https://doi.org/10.1136/thx.2009.127274), indexed in Pubmed: [20522852](https://pubmed.ncbi.nlm.nih.gov/20522852/).
14. Groth SS, Whitson BA, D’Cunha J, et al. Endobronchial ultrasound-guided fine-needle aspiration of mediastinal lymph nodes: a single institution’s early learning curve. *Ann Thorac Surg*. 2008; 86(4): 1104–9; discussion 1109, doi: [10.1016/j.athoracsur.2008.06.042](https://doi.org/10.1016/j.athoracsur.2008.06.042), indexed in Pubmed: [18805141](https://pubmed.ncbi.nlm.nih.gov/18805141/).
15. Bellinger C, Chatterjee A, Adair N, et al. Training in and experience with endobronchial ultrasound. *Respiration*. 2014; 88(6): 478–483, doi: [10.1159/000368366](https://doi.org/10.1159/000368366).
16. Medford ARL. Learning curve for endobronchial ultrasound-guided transbronchial needle aspiration. *Chest*. 2012; 141(6): 1643, doi: [10.1378/chest.12-0317](https://doi.org/10.1378/chest.12-0317), indexed in Pubmed: [22670034](https://pubmed.ncbi.nlm.nih.gov/22670034/).
17. Fernández-Villar A, Leiro-Fernández V, Botana-Rial M, et al. The endobronchial ultrasound-guided transbronchial needle biopsy learning curve for mediastinal and hilar lymph node diagnosis. *Chest*. 2012; 141(1): 278–279, doi: [10.1378/chest.11-1986](https://doi.org/10.1378/chest.11-1986), indexed in Pubmed: [22215843](https://pubmed.ncbi.nlm.nih.gov/22215843/).
18. Medford ARL. Learning curve for EBUS-TBNA: longer than we may think. *Respiration*. 2015; 90(2): 173, doi: [10.1159/000381554](https://doi.org/10.1159/000381554), indexed in Pubmed: [25896031](https://pubmed.ncbi.nlm.nih.gov/25896031/).
19. Folch E, Majid A. Point: are >50 supervised procedures required to develop competency in performing endobronchial ultrasound-guided transbronchial needle aspiration for mediastinal staging? *Yes*. *Chest*. 2013; 143(4): 888–891, doi: [10.1378/chest.12-2462](https://doi.org/10.1378/chest.12-2462), indexed in Pubmed: [23546478](https://pubmed.ncbi.nlm.nih.gov/23546478/).
20. Wahidi M, Herth F, Yasufuku K, et al. Technical aspects of endobronchial ultrasound-guided transbronchial needle aspiration. *Chest*. 2016; 149(3): 816–835, doi: [10.1378/chest.15-1216](https://doi.org/10.1378/chest.15-1216).
21. Davoudi M, Colt HG, Osann KE, et al. Endobronchial ultrasound skills and tasks assessment tool: assessing the validity evidence for a test of endobronchial ultrasound-guided transbronchial needle aspiration operator skill. *Am J Respir Crit Care Med*. 2012; 186(8): 773–779, doi: [10.1164/rccm.201111-1968OC](https://doi.org/10.1164/rccm.201111-1968OC), indexed in Pubmed: [22837376](https://pubmed.ncbi.nlm.nih.gov/22837376/).
22. Konge L, Annema J, Clementsen P, et al. Using virtual-reality simulation to assess performance in endobronchial ultrasound. *Respiration*. 2013; 86(1): 59–65, doi: [10.1159/000350428](https://doi.org/10.1159/000350428), indexed in Pubmed: [23712017](https://pubmed.ncbi.nlm.nih.gov/23712017/).
23. Kheir F, Alokla K, Myers L, et al. Endobronchial ultrasound-transbronchial needle aspiration of mediastinal and hilar lymphadenopathy learning curve. *Am J Ther*. 2016; 23(4): e1016–e1019, doi: [10.1097/MJT.0000000000000050](https://doi.org/10.1097/MJT.0000000000000050), indexed in Pubmed: [24621644](https://pubmed.ncbi.nlm.nih.gov/24621644/).
24. Wahidi MM, Hulett C, Pastis N, et al. Learning experience of linear endobronchial ultrasound among pulmonary trainees. *Chest*. 2014; 145(3): 574–578, doi: [10.1378/chest.13-0701](https://doi.org/10.1378/chest.13-0701), indexed in Pubmed: [24114380](https://pubmed.ncbi.nlm.nih.gov/24114380/).
25. Stather D, Chee A, MacEachern P, et al. Evaluation of the endobronchial ultrasound learning curve in interventional pulmonary fellows. *Respirology*. 2015; 20(2): 333–339, doi: [10.1111/resp.12450](https://doi.org/10.1111/resp.12450), indexed in Pubmed: [25488151](https://pubmed.ncbi.nlm.nih.gov/25488151/).
26. Agarwal R, Srinivasan A, Aggarwal AN, et al. Efficacy and safety of convex probe EBUS-TBNA in sarcoidosis: a systematic review and meta-analysis. *Respir Med*. 2012; 106(6): 883–892, doi: [10.1016/j.rmed.2012.02.014](https://doi.org/10.1016/j.rmed.2012.02.014), indexed in Pubmed: [22417738](https://pubmed.ncbi.nlm.nih.gov/22417738/).
27. Fernández-Bussy S, Labarca G, Canals S, et al. Diagnostic yield of endobronchial ultrasound-guided transbronchial needle aspiration for mediastinal staging in lung cancer. *J Bras Pneumol*. 2015; 41(3): 219–224, doi: [10.1590/S1806-37132015000004466](https://doi.org/10.1590/S1806-37132015000004466), indexed in Pubmed: [26176519](https://pubmed.ncbi.nlm.nih.gov/26176519/).
28. Navasakulpong A, Auger M, Gonzalez AV. Yield of EBUS-TBNA for the diagnosis of sarcoidosis: impact of operator and cytopathologist experience. *BMJ Open Respir Res*. 2016; 3(1): e000144, doi: [10.1136/bmjresp-2016-000144](https://doi.org/10.1136/bmjresp-2016-000144), indexed in Pubmed: [27547408](https://pubmed.ncbi.nlm.nih.gov/27547408/).
29. Garwood S, Judson MA, Silvestri G, et al. Endobronchial ultrasound for the diagnosis of pulmonary sarcoidosis. *Chest*. 2007; 132(4): 1298–1304, doi: [10.1378/chest.07-0998](https://doi.org/10.1378/chest.07-0998), indexed in Pubmed: [17890467](https://pubmed.ncbi.nlm.nih.gov/17890467/).
30. DeLong E, DeLong DM, Clarke-Pearson DL. Comparing the areas under two or more correlated receiver operating characteristic curves: a nonparametric approach. *Biometrics*. 1998; 44(3): 837–845, doi: [10.2307/2531595](https://doi.org/10.2307/2531595).