



Diagnostic and Surgico-therapeutic Management of Perineal Tumour in Dogs

Vishal Kaushik ^{a++}, Reshma Jain ^{a#}, Atul S. Parihar ^{a†},
Niddhi Shrivastava ^{a#}, B. P. Shukla ^{a‡} and Megha Gaur ^{a+++}

^a College of Veterinary Science and Animal Husbandry, Mhow (Madya Pradesh), India.

Authors' contributions

This work was carried out in collaboration among all authors. All authors read and approved the final manuscript.

Article Information

DOI: <https://doi.org/10.9734/air/2024/v25i51161>

Open Peer Review History:

This journal follows the Advanced Open Peer Review policy. Identity of the Reviewers, Editor(s) and additional Reviewers, peer review comments, different versions of the manuscript, comments of the editors, etc are available here: <https://www.sdiarticle5.com/review-history/124085>

Original Research Article

Received: 30/07/2024

Accepted: 01/10/2024

Published: 03/10/2024

ABSTRACT

The benign perianal tumour form comprises more than 80% and is third most common tumour in male dogs. The present study was planned to record the cases of perineal tumour, their diagnosis and management. Their age, sex, breed, size of tumour and clinical history were recorded. Clinical, physical, radiographic and ultrasonographic examination of affected dogs were also done accordingly.

In uncastrated male dogs first castration was done 2-4 weeks before excision of tumour via open prescrotal castration method. Corrective surgery was performed for tumour excision in 9 dogs under

⁺⁺ PG Scholar;

[#] Associate Professor;

[†] Assistant Professor;

[‡] Professor and Head;

*Corresponding author: E-mail: vetmeghagaur1996@gmail.com;

Cite as: Kaushik, Vishal, Reshma Jain, Atul S. Parihar, Niddhi Shrivastava, B. P. Shukla, and Megha Gaur. 2024. "Diagnostic and Surgico-Therapeutic Management of Perineal Tumour in Dogs". *Advances in Research* 25 (5):281-90. <https://doi.org/10.9734/air/2024/v25i51161>.

general anaesthesia as per the standard technique. Two dogs diagnosed with venereal granuloma, were treated by using the chemotherapeutic protocol.

During the study of perineal affection, 11 cases of perineal tumour were recorded in intact male dogs. Indian Spitz breed was most commonly affected followed by other breeds. Varying size of perineal tumours were recorded along with anorexia, faecal and urinary incontinence. Radiographic examination and Ultrasonography were also done to determine the nature and extent of perineal swelling for accurate removable of growth without any complications.

In the haematological studies, there was significant decrease in neutrophil and increase in lymphocyte and monocyte count. Biochemical parameters indicated a non-significant decline. In cytological and histopathological analysis, it was confirmed that 5 dogs had perianal adenoma, 2 had perianal epithelioma, 2 had venereal granuloma, 1 had anal gland adenoma and 1 had adenocarcinoma. Perianal adenoma could be managed successfully by surgical excision with castration. Venereal granuloma growth in perineal region could be corrected successfully with chemotherapeutic protocol with good outcome.

Keywords: Perineal tumour; venereal granuloma; cytological; histopatological; adenoma.

1. INTRODUCTION

Perianal adenomas appear as slow-growing, non-painful masses around the anus. They can arise as single, multiple or diffuse masses. Occasionally, they will be ulcerated and infected on their surface. Dogs frequently develop perineal tumours and the two most common tumours are perianal gland adenoma and anal sac adenocarcinoma. Due to their histological similarities to hepatocytes, perianal glands are also known as hepatoid glands. The benign form comprises more than 80% of the perianal tumours and is third most common tumour in male dogs [1]. The biological behavior of these tumours varies greatly and they are typically benign or occasionally malignant [2]. As compared to female dogs, intact males are at high risk [3]. Treatment comprises removal of tumour surgically concomitant with orchietomy. In adult and elderly male dogs, androgenic stimulation causes hyperplasia and neoplastic transformation of the hepatoid glands [4].

Canine transmissible venereal tumour (CTVT) is most commonly found in young sexually mature stray dogs with uncontrolled reproductive activity and typically resembles a cauliflower which is friable and ranges in colour from red to flesh. The disease is horizontally transmissible from male to female during breeding among affected animals or vice-versa [5]. For confirm diagnosis of tumours, cytology and histopathology are helpful procedures that are typically utilized [6].

The present study was conducted to diagnosis the type of perineal tumour and their surgico-therapeutic management.

2. MATERIALS AND METHODS

The present study was conducted in eleven dogs presented with perineal tumour at Veterinary Clinical Complex (VCC), College of Veterinary Science and Animal Husbandry, Mhow from June, 2022 to February, 2023. Their age, sex, breed, size of tumour and clinical history were recorded. Clinical, physical, radiographic and ultrasonographic examinations of affected dogs were done accordingly.

In uncastrated male dogs, first castration was done 2-4 weeks before excision of tumour via open prescrotal castration method.

For haemato-biochemical examination parameters including Total erythrocyte count (TEC) (million/ μ l), Packed cell volume (PCV) (%), Total leukocyte count (TLC) (thousand/ μ l), Haemoglobin (Hb) (g/dl), Differential leukocyte count (DLC) (%), Aspartate transaminase (AST) (IU/L), Alanine aminotransferase (ALT) (IU/L), Blood urea nitrogen (BUN) (mg/dl) and Creatinine (mg /dl) were on 0 day (on the day of presentation of animal) and 7th day (after therapeutic management or surgery).

Dogs were prepared aseptically at the site of perineal region and operated under general anaesthesia using inj. Atropine sulphate @ 0.02–0.04 mg/kg b.wt. and inj. Xylazine @ 0.5-1 mg/kg b.wt. I/M as preanesthetic followed by inj. Ketamine @ 5-10 mg/kg b.wt. I/V for induction. Anaesthesia was maintained by combination of inj. Diazepam and inj. Ketamine in 1:1 (volume:volume) ratio I/V as and when required.

For removal of tumour, dogs were positioned in ventral recumbency with elevated hindquarter and tumour was dissected from subcutaneous tissue and external anal sphincter with minimal trauma. The skin was sutured and tumour was then sent for histopathological examination.

Antibiotic inj. Ceftriaxone @ 20 mg/kg b.wt. I/M, BID and analgesic inj. Meloxicam @ 0.2 mg/kg b.wt. I/M, OD were given for 7 days and 3 days respectively. Antiseptic dressing was done for 2 weeks on daily basis and owners were advised to feed the dog with laxative diet. Skin sutures were removed at 10-12th day postoperatively as per healing.

In cases of venereal granuloma of perineal region cytological examination was done by taking fine needle aspirate from the tumour tissue. For regressing the growth administration of inj. Vincristine sulphate was done on weekly basis and side effects were managed symptomatically.

The data was analysed by using Complete Randomized Design (CRD) and paired 't' test as per the standard procedure outlined by Snedecor and Cochran [7].

3. RESULTS AND DISCUSSION

In the present study period, 11 cases of perineal tumour were recorded. The occurrence of perineal tumour was more in age group of more than 6 years (10 dogs) and only one case was of less than 6 years of age. Males (8 dogs) were presented more with perineal growth as compared to females (3 dogs). The occurrence of perineal tumour was noticed more in Indian Spitz (4 dogs) followed by Mongrel (3 dogs), Labrador (3 dogs) and Golden Retriever (1 dog) during the observation period (Table 1).

Similarly, Shabeeba et al. [8] also concluded that males with mean age of 9.8 years were more predisposed to the condition. Madheswaran et al. [9] and Kokila et al. [10] also presented similar results.

The high risk for development of perianal adenomas is found in aged and intact males due to androgen dependency [11] as hyperplasia and neoplastic transformation of hepatoid glands is induced by androgenic stimulation in aged male dogs [4]. The steroid sex hormones suggested to stimulate the proliferation of perianal gland tumours by acting as local growth factors [12].

Pisani et al. [13] also reported that presence of immunohistochemical expression of androgen receptors is higher in hepatoid gland tumours.

In the present study, Indian Spitz was found to be the most predisposed breed to perineal tumours. Batra [14] also reported similar findings during management of perineal tumours in 10 dogs while contrary to these findings Kokila et al. [10] revealed highest incidence of anal tumours in German Shepherd. Tozon et al. [1] reported that Mongrels were mostly predisposed while number of tumour nodules were maximum in German Shepherd breed of dog. However the predisposition of certain breed depends on availability of different breeds in a particular geographical location.

Varying size of perineal tumours were recorded on the basis of visual examination which revealed three dogs had large sized growth (approximately more than 10 cm), three had moderate sized growth (approximately 5-10 cm) and five dogs had small sized growth (approximately less than 5 cm). In two dogs, the tumourous growth was ulcerated and in one dog growths were multiple in number. Most of the dogs (10 dogs) were presented with clinical sign of biting at perineal region. Anorexia was reported in five dogs, faecal incontinence in four dogs, urinary incontinence in two dogs and haematochezia was present in two dogs (Table 1, Table 2).

Results of present study are in agreement of Shabeeba et al. [8] who mentioned clinical history of perianal growth, loss of appetite, faecal incontinence, severe itching, haemorrhages and ulcers on perineal region during her study on hepatoid gland tumours in five dogs. Similarly, Kokila et al. [10] mentioned common clinical signs like swelling in perineal area, anorexia, bloody discharge, biting perineal area, discomfort, weight loss, ulceration, tail lifting, lethargy, dysuria, constipation, necrosis and dyschezia in affected dogs which is consistent with the present findings. Devi et al. [15] also mentioned lesions of varying size from nodules to large ulcerated and haemorrhagic forms which compressed the anal opening, leading to difficulty in defecation.

The anaesthetic protocol and animal preparation was satisfactory for all the dogs. Analgesia, muscle relaxation was noticed to be adequate for the surgical procedure and all the dogs recovered post-operatively.

Table 1. Signalment of the dogs affected with perineal tumour (n=11)

Case No.	Age (years)	Sex	Breed	Type of tumour	Size of tumour
1.	03	M	Mongrel	Perianal adenoma	Large
2.	13	F	Labrador	Anal sac gland adenoma	Moderate
3.	08	M	Labrador	Perianal adenoma	Small
4.	14	M	Indian spitz	Perianal epithelioma	Small
5.	09	M	Labrador	Perianal adenoma	Large
6.	13	F	Indian spitz	Perianal adenoma	Moderate
7.	15	M	Indian spitz	Perianal adenocarcinoma	Moderate
8.	15	M	Mongrel	Perianal epithelioma	Small
9.	10	M	Mongrel	Perianal adenoma	Large
10.	08	M	Golden Retriever	Venereal tumour	Small (Multiple)
11.	06	F	Indian spitz	Venereal tumour	Small

Table 2. Clinical signs in dogs affected with perineal tumour (n=11)

S. No.	Clinical signs	No. of dogs
1.	Biting of perineal region	10
2.	Anorexia	5
3.	Faecal incontinence	4
4.	Haematochezia	2
5.	Urinary incontinence	2
6.	Ulceration of tumourous mass	2

Castration was performed in 5 intact male dogs as mentioned in material method. After the castration, surgery was performed for tumour excision as per standard protocol in 9 dogs. While excision, the major complication was bleeding in some cases although it was managed (Fig. 1, Fig. 2, Fig. 3, Fig. 4).

Kokila et al. [10] also considered surgical excision as the routine therapy. The preferred course of treatment for intact male dogs with perianal adenoma, according to Thomas and Fox [16], is to remove the tumour and neuter the dog, which can reduce recurrence rates by 95% as castration eliminates the major source of testosterone. Generally, neutering of male dogs early in life will help to prevent the development of perianal adenomas, adenocarcinomas and other such type of growths. Wilson and Hayes [17] also opined that perianal adenomas generally occurred in tissues around the rectum that were responsive to androgens, hence castration resulted in regression of the tumour as Pisaniet al. [13] also reported that presence of immunohistochemical expression of androgen receptors is higher in hepatoid gland tumours.

As per clinical and cytological examination, 2 dogs were treated by chemotherapeutic agent, inj. Vincristine sulphate @ 0.025 mg/kg b.wt. I/V on weekly basis. One dog was treated for 2

weeks and the other one for 3 weeks. The reduction in growth was noticed in both the dogs after one week and complete resolution of growth occurred in 2 weeks in one dog and 3 weeks in other dog. Vomition and anorexia were noticed in dogs during chemotherapeutic treatment but managed accordingly without any serious complication (Fig. 5, Fig. 6).

Anusha et al. [5] reported in her study on canine transmissible venereal tumours that when a group of 6 dogs treated with inj. Vincristine @ 0.025 mg/kg b.wt. mixed with normal saline and administered I/V once in a week, showed appreciable tumour regression within 4-6 weeks which is in agreement with the present study. The vincristine was potent in the treatment of canine transmissible venereal tumour (CTVT) which showed complete regression of tumours with some side effects like vomition and anorexia.

Post operatively, two dogs showed wound dehiscence on 3rd and 5th day respectively after the surgery which was corrected by resuturing of the wound. Wound dehiscence was the common post-operative complication due to self-mutilation, negligence of owner, mobility during defaecation and difficulty in bandaging due to anatomical position. In most of the dogs, slight faecal incontinence was also noticed and managed by laxative drugs and diet.



Fig. 1. Perineal tumour before excision

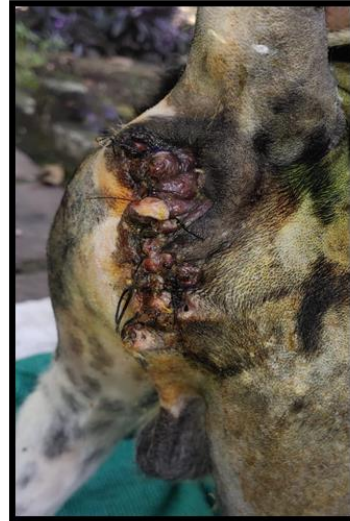

Fig. 2. Post operatively after excision

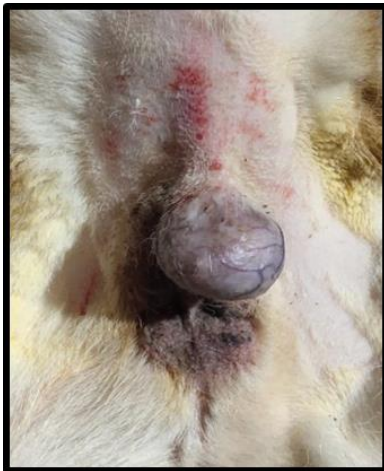

Fig. 3. Perineal adenoma before surgery

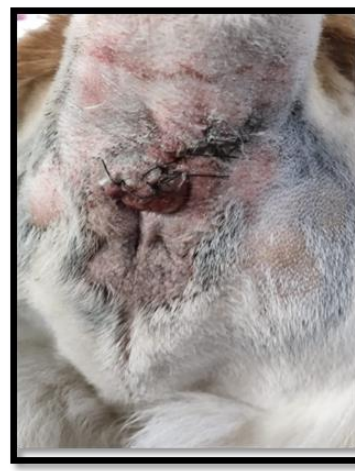


Fig. 4. Post operatively after excision of perineal adenoma

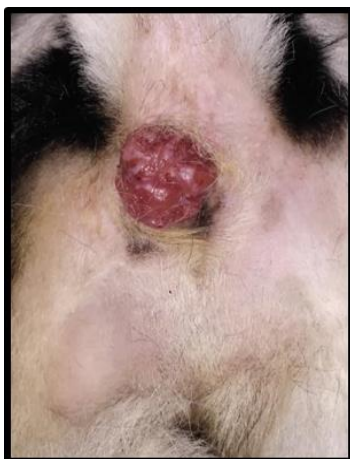

Fig. 5. Perineal venereal granuloma before chemotherapy

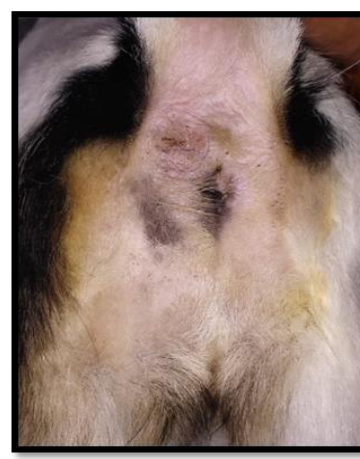

Fig. 6. Regression of growth after chemotherapeutic protocol

Table 3. Mean values (\pm SE) of haematological parameters in dogs affected with perineal tumour (n=11)

Interval (days)	Hb (g/dl)	PCV (%)	TEC (million/ μ l)	TLC ($10^3/\mu$ l)	DLC (%)				
					Neutrophil	Lymphocyte	Monocyte	Eosinophil	Basophil
0	13.80 \pm 0.20	41.40 \pm 0.62	6.90 \pm 0.10	13.66 \pm 0.20	71.81 \pm 0.48 ^a	19.45 \pm 0.52 ^a	5.45 \pm 0.24 ^a	1.90 \pm 0.25	1.20 \pm 0.19
7	13.62 \pm 0.20	40.88 \pm 0.62	6.81 \pm 0.10	13.15 \pm 0.22	68.27 \pm 0.60 ^b	22.36 \pm 0.41 ^b	6.00 \pm 0.23 ^b	2.00 \pm 0.19	1.36 \pm 0.15

Mean value with different superscripts differ significantly ($p < 0.05$) within days

Table 4. Mean values (\pm SE) of biochemical parameters in dogs affected with perineal tumour (n=11)

Interval (days)	BUN (mg/dl)	Creatinine (mg/dl)	ALT (IU/L)	AST (IU/L)
0	22.13 \pm 0.59	1.26 \pm 0.04	36.10 \pm 0.92	34.71 \pm 1.08
7	21.86 \pm 0.58	1.17 \pm 0.04	35.41 \pm 1.01	33.76 \pm 1.04

The mean values of haemoglobin, packed cell volume, total erythrocyte count and leukocyte count decreased non-significantly on 7th day as compared with the pretreatment 0 day. In differential leukocyte count statistically, there was significant decrease in neutrophil while increase in lymphocyte and monocyte count. Although, the values of both the days were within normal physiological range. There was non-significant changes seen in the mean values of eosinophil and basophil (Table 3).

Madheswaran et al. [9] revealed that haematological parameters of the affected dogs did not show any significant changes for total erythrocyte count, haemoglobin and total leukocyte count. Kumar et al. [18] also reported non-significant decrease of mean haemoglobin, packed cell volume and total erythrocyte count with insignificant alteration of leukocyte count. These findings are in accordance with the present study. Javanbakht et al. [19] also revealed similar findings in his study on anal sac adenocarcinoma tumour in a Spitz dog.

The mean values of blood urea nitrogen, creatinine, alanine aminotransferase and aspartate transaminase showed non-significant decrease at 7th day as compared to day 0 (Table 4).

Kokila et al. [10] also reported that the mean values of blood urea nitrogen and creatinine were within the normal range in the dogs with

anal tumours throughout the study period which is in complete agreement of the present study. Similar observations were also recorded by Madheswaran et al. [9] and Kumar et al. [18] during their study period.

Radiographs were taken in two dogs to analyze the extent of tumour. No other organs were found to be suppressed by the tumourous mass. Ultrasonography was also done in two dogs to determine the nature of perineal swelling and hyperechoic image confirmed the swelling as tumorous growth. The swelling was found to be only in the subcutaneous area without any warranted suppression of the nearby organs (Fig. 7, Fig. 8).

Kokila [10] observed that radiographs of animals suffering with perineal tumours showed soft tissue swelling in urogenital perineal region which is in consonance of the present study.

Fine needle aspirate was taken in two dogs for cytological study, they were diagnosed as veneral granuloma of perineal region with oval to round shaped nucleus, clear cytoplasmic vacuoles (Fig. 9, Fig. 10).

The present study is in agreement with Anusha et al. [5]; Thangathuria et al. [20]; Purohit [21] and Tella et al. [22] who also observed similar presence of clear cytoplasmic vacuoles in CTVT affected dogs.

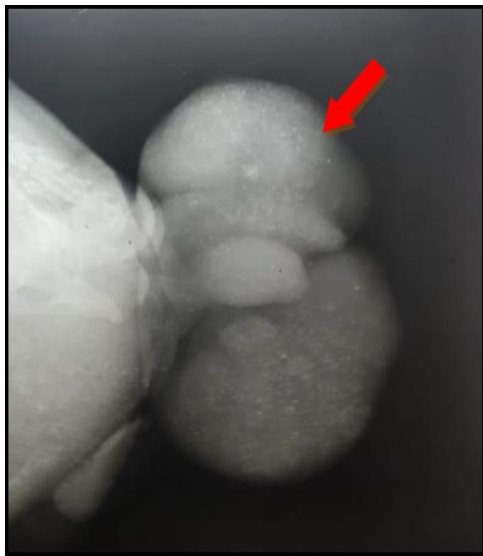

Fig. 7. Radiographic image of perineal tumour

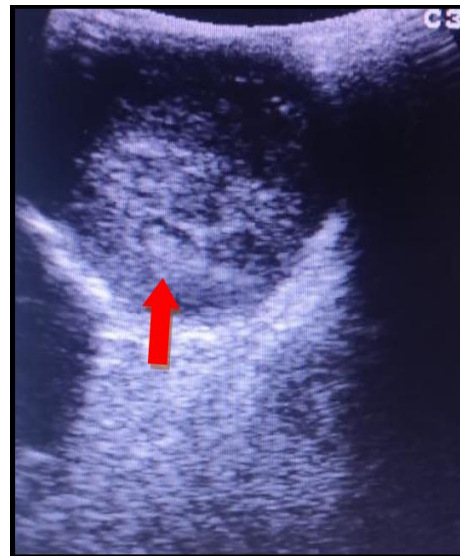

Fig. 8. Ultrasonographic image of perineal tumour

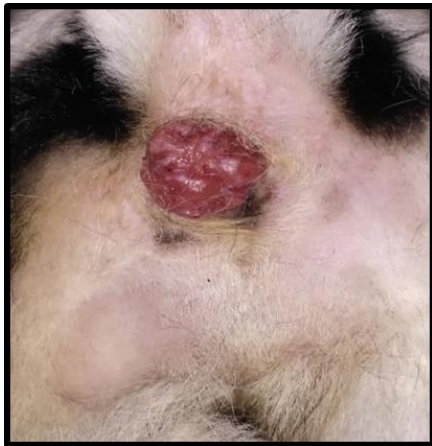

Fig. 9. Gross appearance of venereal granuloma of perineal region

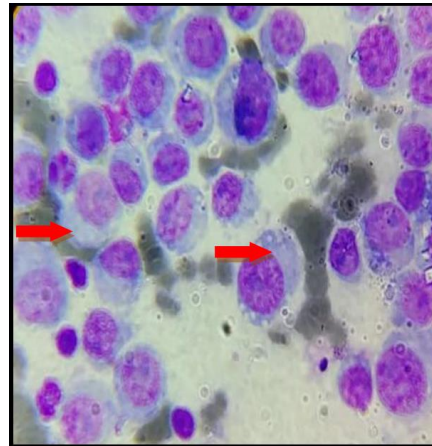


Fig. 10. Cytology of venereal granuloma showing oval to round shaped cells and clear cytoplasmic vacuoles

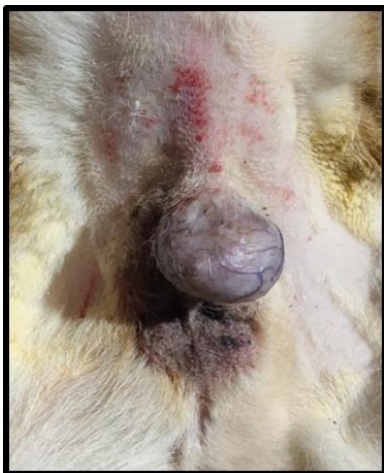

Fig. 11. Gross appearance of perianal adenoma

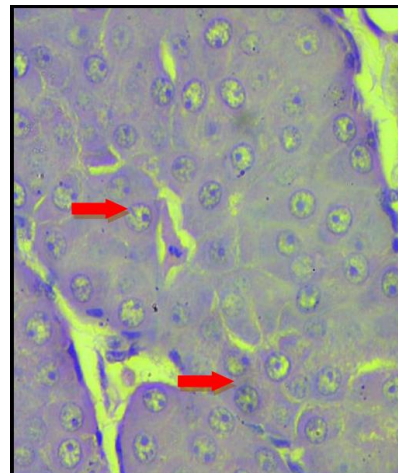


Fig. 12. Histopathology of perianal adenoma showing hepatoid cells with vesicular nucleus

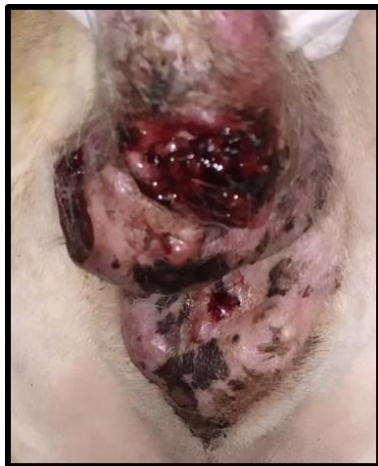

Fig. 13. Gross appearance of anal gland adenocarcinoma

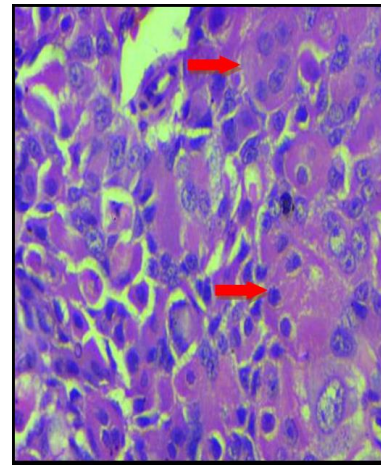


Fig. 14. Histopathology of anal gland adenocarcinoma showing multinucleated giant cells

Histopathological study was performed in 9 dogs for confirmatory diagnosis and revealed that 5 dogs were affected with perianal adenoma characterized by discrete bundles of large and round neoplastic cells which were round to polygonal in shape and appeared as packed hepatocytes, 1 dog with anal sac gland adenoma characterized with proliferation of hepatocytes like hepatoid cells, 2 dogs with perianal epithelioma characterized by presence of basaloid reserve cells with some hepatocyte like cells, 1 dog with perianal adenocarcinoma characterized grossly as firm and ulcerated while microscopically, revealed marked pleomorphic cells with multinucleated giant cells (Fig. 11, Fig 12, Fig. 13, Fig 14).

Madheswaran et al. [9] also confirmed histopathologically, 6 cases of adenoma and 3 cases of adenocarcinoma during clinicopathological study in perianal gland tumours of nine dogs which is in close agreement of histopathological analysis of present study. The histopathological features of perianal gland tumours obtained in the present study are also in accordance with Meuten [2]; Trangadia [23] and Pereira et al. [24]. Shabeeba et al. [8] also confirmed histopathologically, presence of hepatoid gland adenoma in two cases, hepatoid gland epithelioma in one case and two cases of adenocarcinoma during her study of canine hepatoid gland tumours in five dogs which is also in close agreement of the present study on perianal tumours.

4. CONCLUSION

The present study concluded that most common perineal tumours were perianal adenoma and could be managed successfully by surgical excision and castration with no reoccurrence in follow up period of 6 months. Some animals were also affected with venereal granuloma growth in perineal region which could be successfully corrected with chemotherapeutic protocol. There is need of studies on use of advanced chemotherapeutic protocol for regression of perineal tumours.

ETHICAL APPROVAL

As per international standards or university standards written ethical approval has been collected and preserved by the author(s).

DISCLAIMER (ARTIFICIAL INTELLIGENCE)

Author(s) hereby declare that NO generative AI technologies such as Large Language Models

(ChatGPT, COPILOT, etc.) and text-to-image generators have been used during the writing or editing of this manuscript.

COMPETING INTERESTS

Authors have declared that no competing interests exist.

REFERENCES

1. Tozon N, Kodre V, Sersa G, Cemazar M. Effective treatment of perianal tumors in dogs with electrochemotherapy. *Anticancer Res.* 2005;25(2):839-845.
2. Meuten DJ. *Tumors in domestic animals.* 5th ed. Iowa State Press, USA: A Blackwell Publishing Company; 2017.
3. Dernel WS. Perianal tumours. In: 19th The North American Veterinary Conference Proceedings. Orlando, Florida: Eastern States Veterinary Association. 2005;254-255.
4. Brodzki A, Lopuszynski W, Millan Y, Tataru MR, Brodzki P, Kulpa K, Minakow N. Androgen and estrogen receptor expression in different types of perianal gland tumors in male dogs. *Animals.* 2021;11(3):875.
5. Anusha A, Ramana KV, Reddy KCS, Swathi B. Studies on transmissible venereal tumour (TVT) in canines. *J Pharm Innov.* 2022;11(6):1544-1547.
6. Choi EW. Deep dermal and subcutaneous canine hemangiosarcoma in the perianal area: Diagnosis of perianal mass in a dog. *BMC Vet Res.* 2019;15(1):1-5.
7. Snedecor GW, Cochran WG. *Statistical method.* 7th ed. New Delhi: Oxford and IBH Publishing Co; 1994:312-317.
8. Shabeeba PM, Sajitha IS, Devi SS, Divya C, Nair SS. Histopathological study of canine hepatoid gland tumours. *J Vet Anim Sci.* 2021;52(3):277-280.
9. Madheswaran R, Prabhakaran KP, Srinivasan P, Balasubramaniam GA, Balachandran P, Sasikala M, et al. Clinicopathological studies and immunohistochemical expression of hormonal receptors in perianal gland tumors of dogs. *Indian J Vet Pathol.* 2021;45(3):190-194.
10. Kokila S, Veena P, Kumar RV, Srilatha C. Clinical studies on anal tumors in dogs. *Indian J Anim Res.* 2016;50(4):629-631.
11. Withrow S, Vail D, Page R. *Withrow and MacEwen's small animal clinical oncology.*

- 5th ed. Philadelphia, U.S.A.: WB Saunders. 2012;164-173.
12. Kaldrymidou H, Leontides L, Koutinas AF, Saridomichelakis MN, Karayannopoulou M. Prevalence, distribution and factors associated with the presence and the potential for malignancy of cutaneous neoplasms in 174 dogs admitted to a clinic in northern Greece. *J Vet Med Series A*. 2002;49(2):87-91.
 13. Pisani G, Millanta F, Lorenzi D, Vannozzi I, Poli A. Androgen receptor expression in normal, hyperplastic and neoplastic hepatoid glands in the dog. *Res Vet Sci*. 2006;81(2):231-236.
 14. Batra P. Chemotherapeutic and surgical management of perineal affections in dogs. M.V.Sc. thesis (Surgery and Radiology), Punjab Agricultural University, Ludhiana; 2001.
 15. Devi LG, Choudhari A, Singh ND, Banga HS, Gadhav PD. An incidental case of perianal gland adenoma in a stray dog. *Sci J Anim Sci*. 2012;1(2):71-74.
 16. Thomas RC, Fox LE. Tumors of the skin and subcutis, perianal (hepatoid) gland tumors. In: Morrison WB, editors. *Cancer in Dogs and Cats*. Baltimore: Williams & Wilkins; 1998:497-498.
 17. Wilson G, Hayes H. Castration for treatment of perianal gland neoplasms in the dog. *J Am Vet Med Assoc*. 1979;174:1301-1303.
 18. Kumar AV, Kumari NK, Kumar SK, GireeshV, Kumar S, Lakshman M. Hemato-biochemical changes in perianal tumors affected dogs. *J Pharm Innov*. 2018;7(3):25-27.
 19. Javanbakht J, Tavassoli A, Sabbagh A, Hassan MA, Samakkhah SA, Shafiee R, et al. Evaluation of an anal sac adenocarcinoma tumor in a Spitz dog. *Asian Pac J Trop Biomed*. 2013;3(1):74-78.
 20. Thangathurai R, Balasubramaniam GA, Dharmaceelan S, Balachandran P, Srinivasan P, Sivaseelan S, et al. Cytological diagnosis and its histological correlation in canine transmissible venereal tumour. *Vet Arch*. 2008; 78(5):369-376.
 21. Purohit GN. Canine transmissible venereal tumor: A review. *Internet J Veterin Med*. 2009;6(1):1-10.
 22. Tella MA, Ajala OO, Taiwo VO. Complete regression of transmissible venereal tumor (TVT) in Nigerian mongrel dogs with vincristine sulphate chemotherapy. *African J Biomed Res*. 2004;7(3):133-138.
 23. Trangadia BJ, Patel JM, Vihol PD, Prasad MC, Suthar DN, Tyagi SK. Pathology of perianal gland tumors in dogs. *Indian J Vet Pathol*. 2014;38:122-123.
 24. Pereira RS, Schweigert A, de Melo GD, Fernandes FV, Sueiro FAR, Machado GF. Ki-67 labeling in canine perianal glands neoplasms: a novel approach for immunohistological diagnostic and prognostic. *BMC Vet Res*. 2013;9(1): 1-7.

Disclaimer/Publisher's Note: The statements, opinions and data contained in all publications are solely those of the individual author(s) and contributor(s) and not of the publisher and/or the editor(s). This publisher and/or the editor(s) disclaim responsibility for any injury to people or property resulting from any ideas, methods, instructions or products referred to in the content.

© Copyright (2024): Author(s). The licensee is the journal publisher. This is an Open Access article distributed under the terms of the Creative Commons Attribution License (<http://creativecommons.org/licenses/by/4.0>), which permits unrestricted use, distribution, and reproduction in any medium, provided the original work is properly cited.

Peer-review history:

The peer review history for this paper can be accessed here:

<https://www.sdiarticle5.com/review-history/124085>